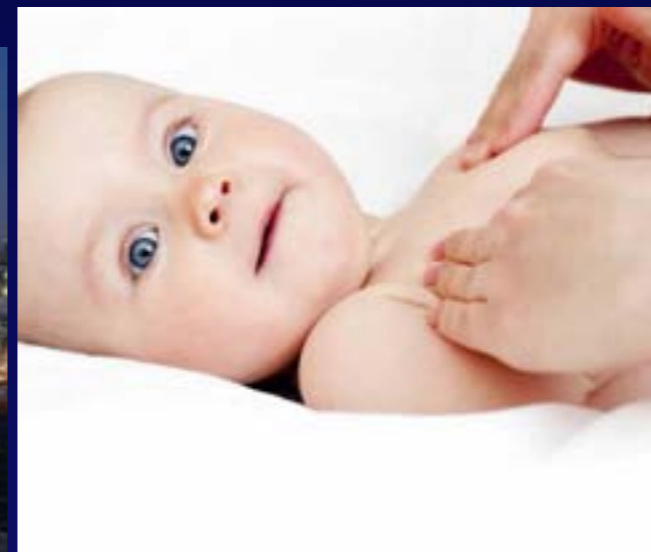

Transposition and Double Outlet Right Ventricle



**Norman H Silverman MD. D Sc (Med), FACC, FASE, FAHA.
Professor of Pediatrics Emeritus (Cardiology) U.C. San Francisco,
Professor Emeritus, Stanford University**



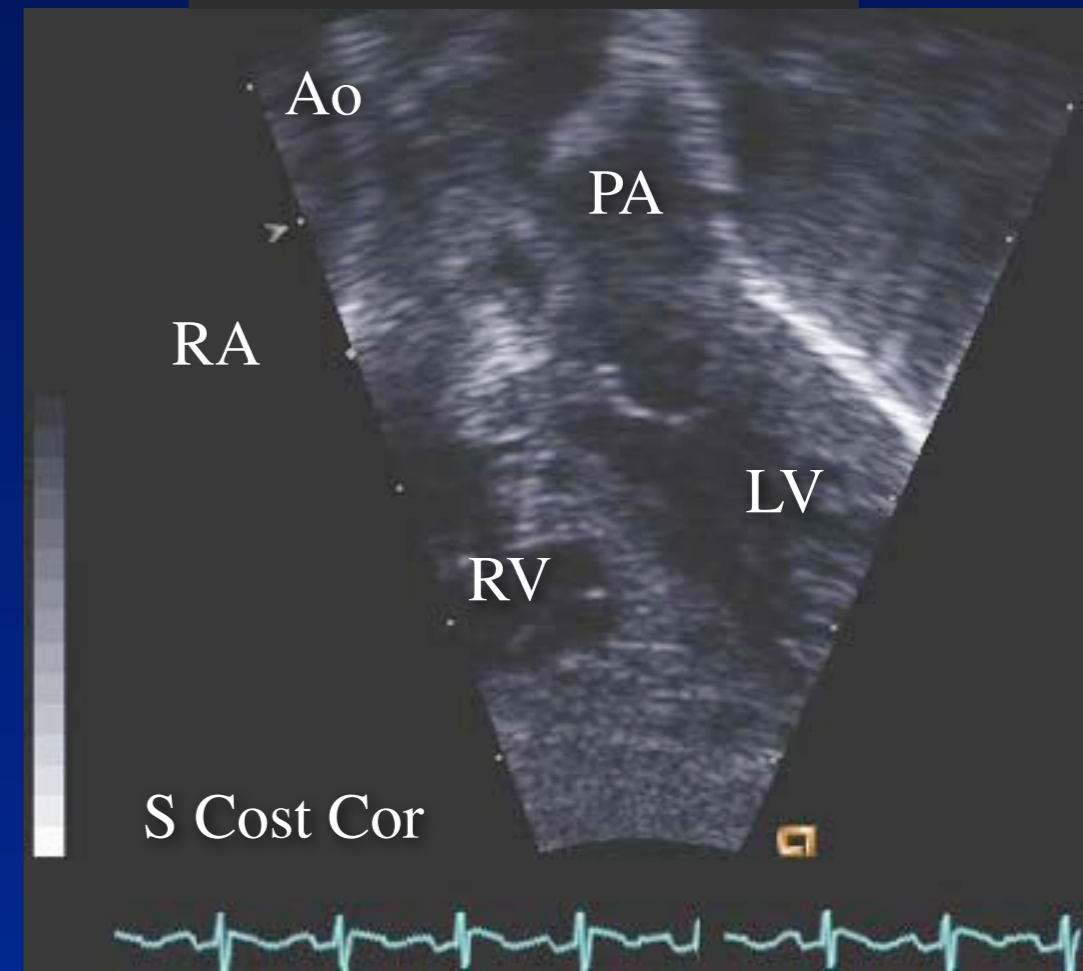
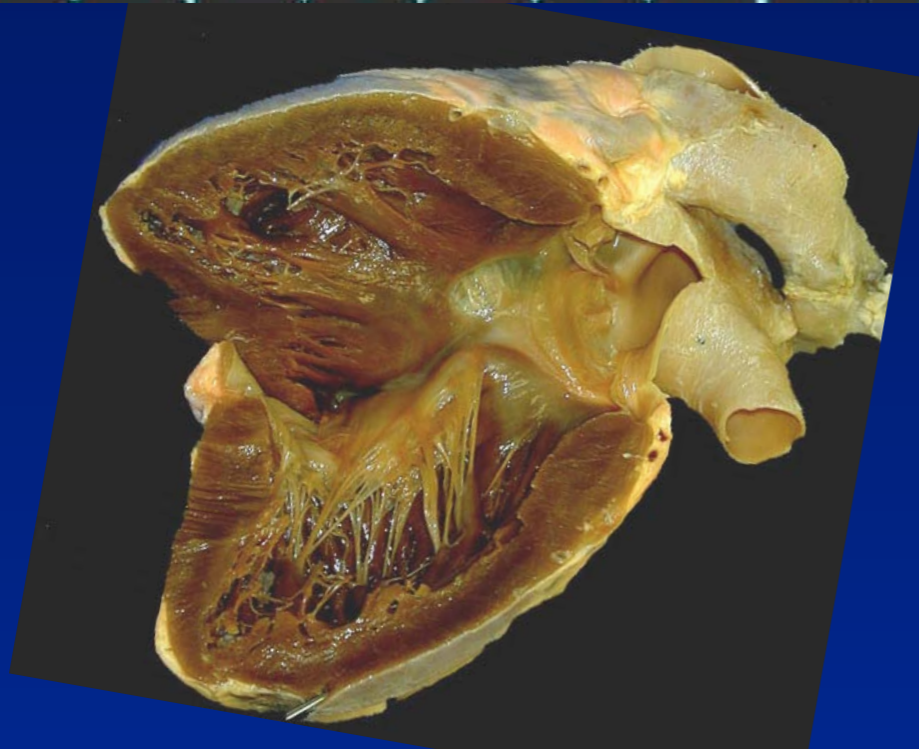
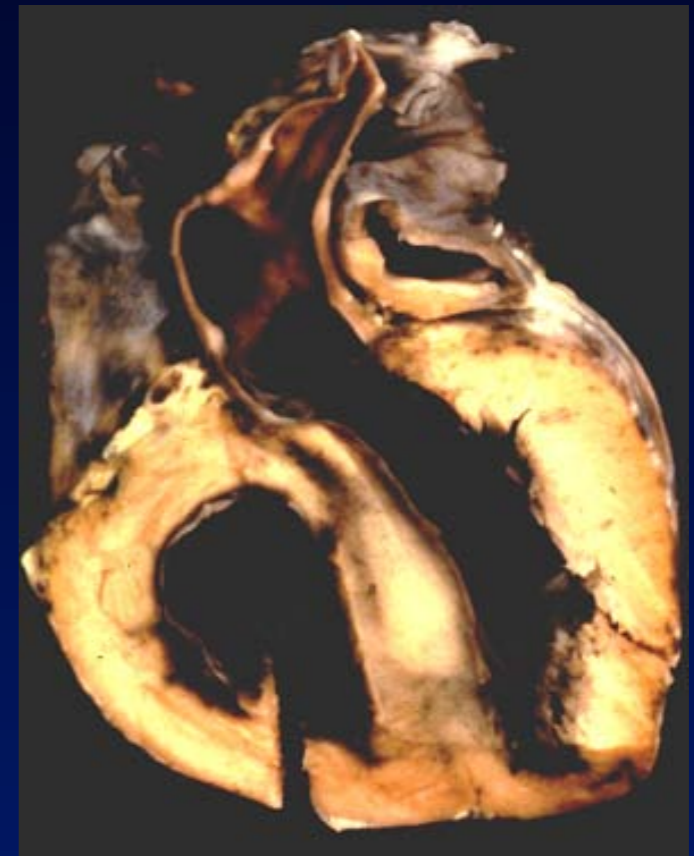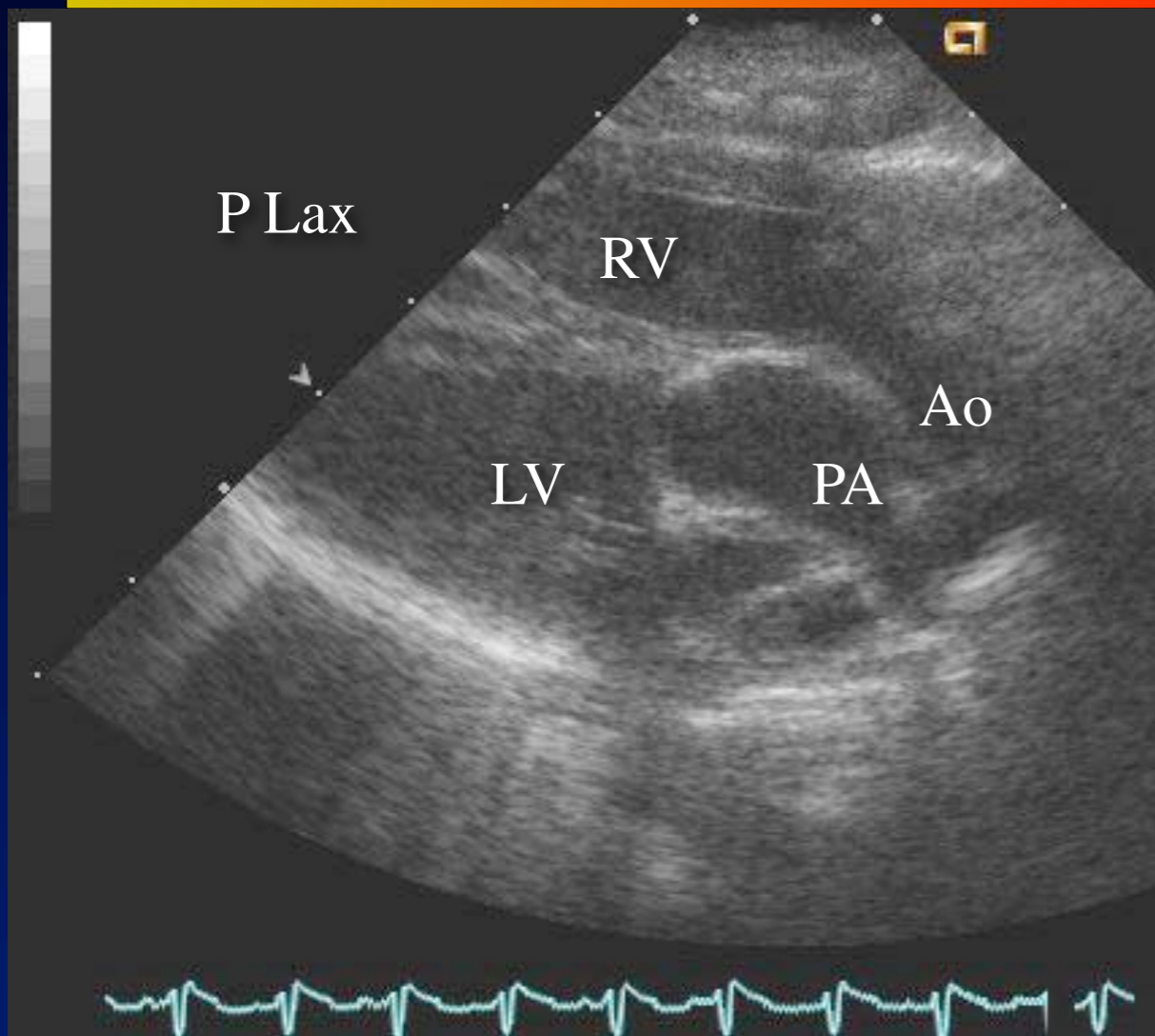
Common Transposition

- 6% of congenital heart disease
- Latin-*transponere*= to place across
- Aorta from right ventricle
- Pulmonary artery from left ventricle

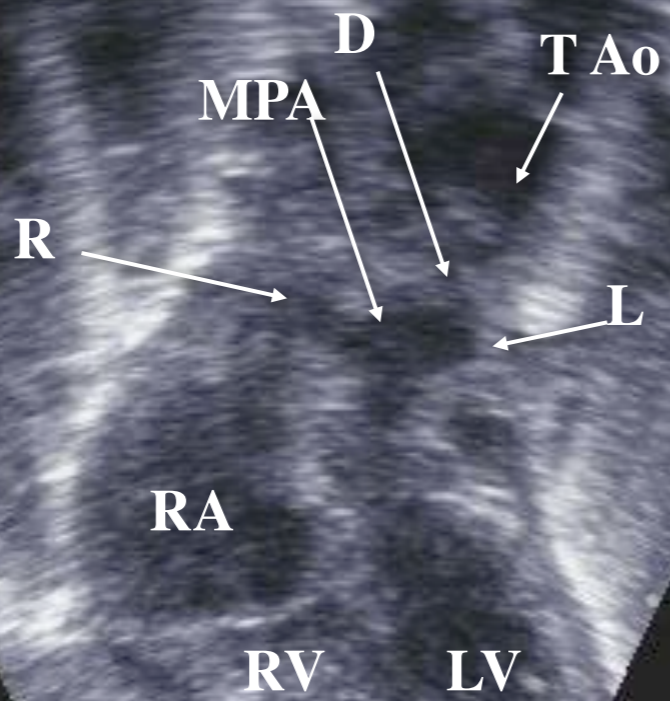
Transposition: State-of-the-Art.

- **Define**
 - **Situs**
 - **Atrioventricular connection**
 - **Ventriculo-arterial connections.**
 - **Type and extent of the atrial connections.**
 - **Perform balloon atrial septostomy where necessary.**
 - **Atrioventricular morphology**
 - **Extent and type of ventricular septal defect**
 - **Arterial Positions**
 - **Aortic, pulmonic and sub, valvar and supra-valvar abnormalities**
 - **Define the coronary artery patterns.**
 - **Assess Ductus**
 - **Arch obstructions**

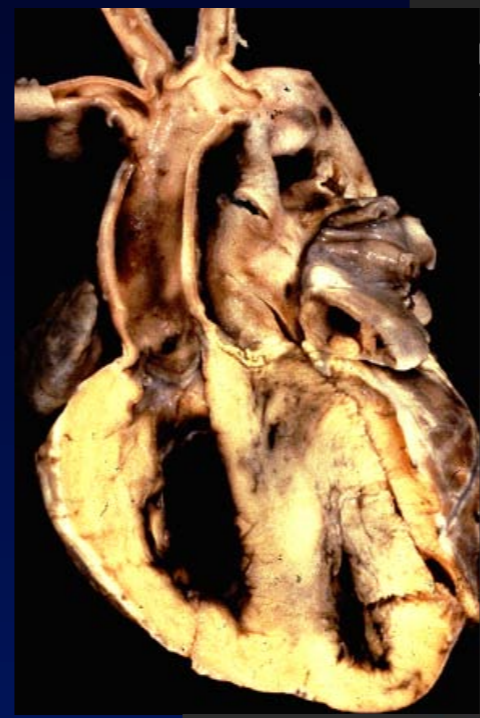Atrioventricular & Ventriculoarterial Connections



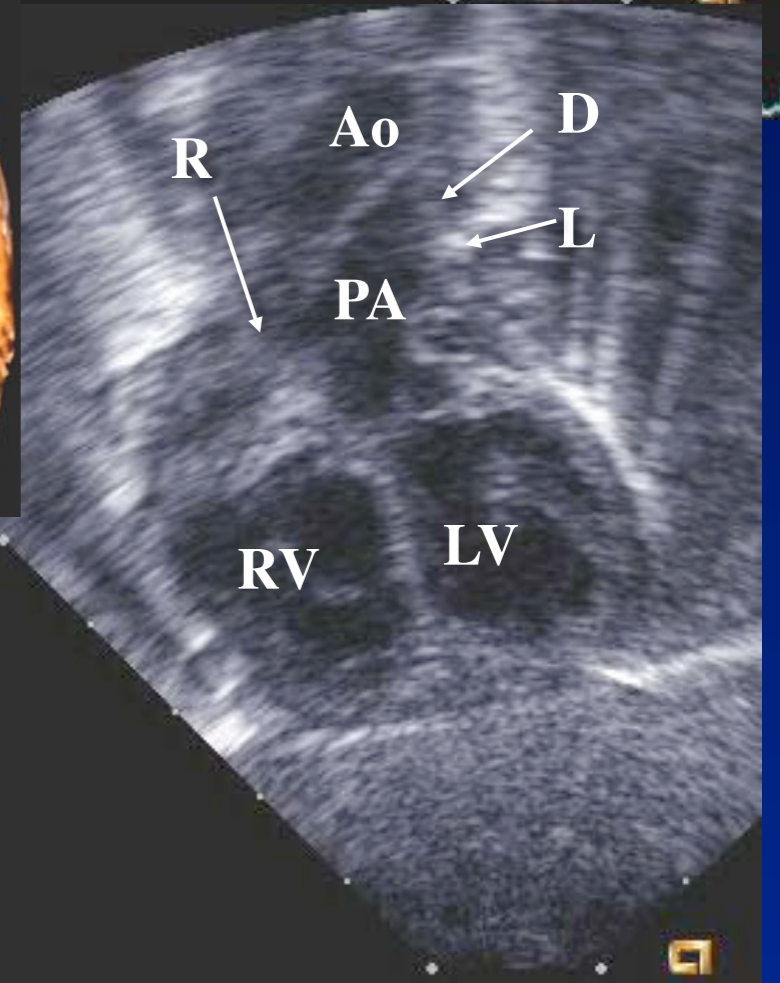
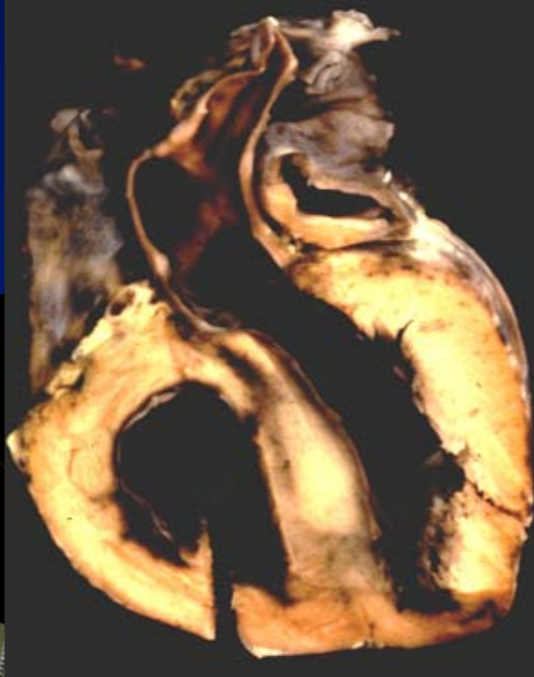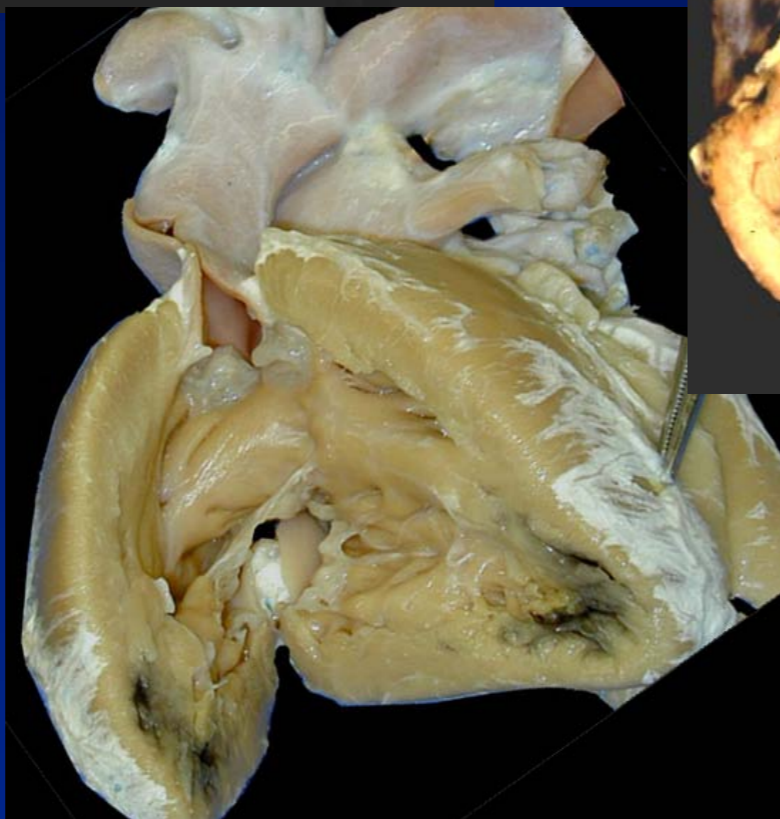
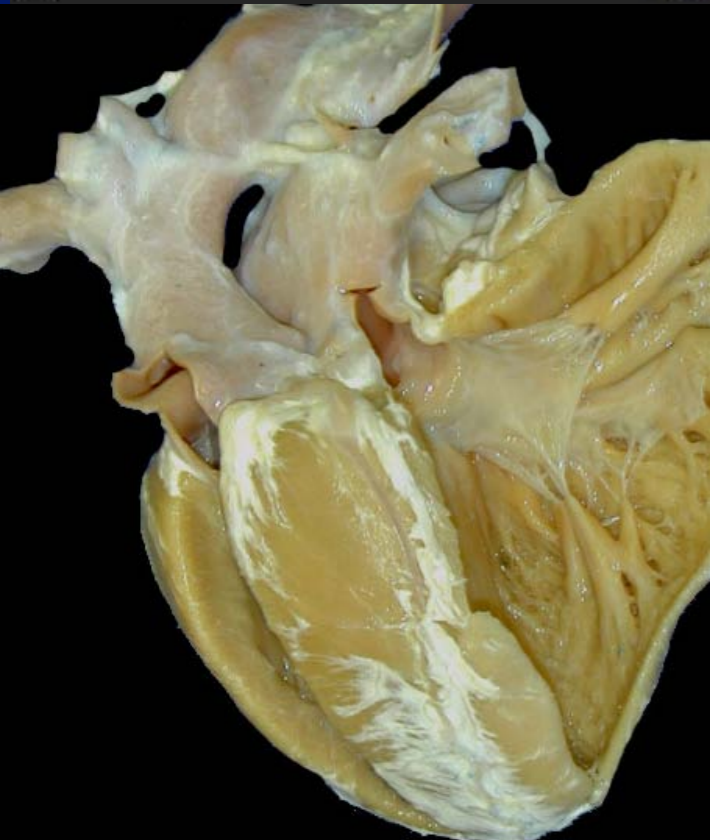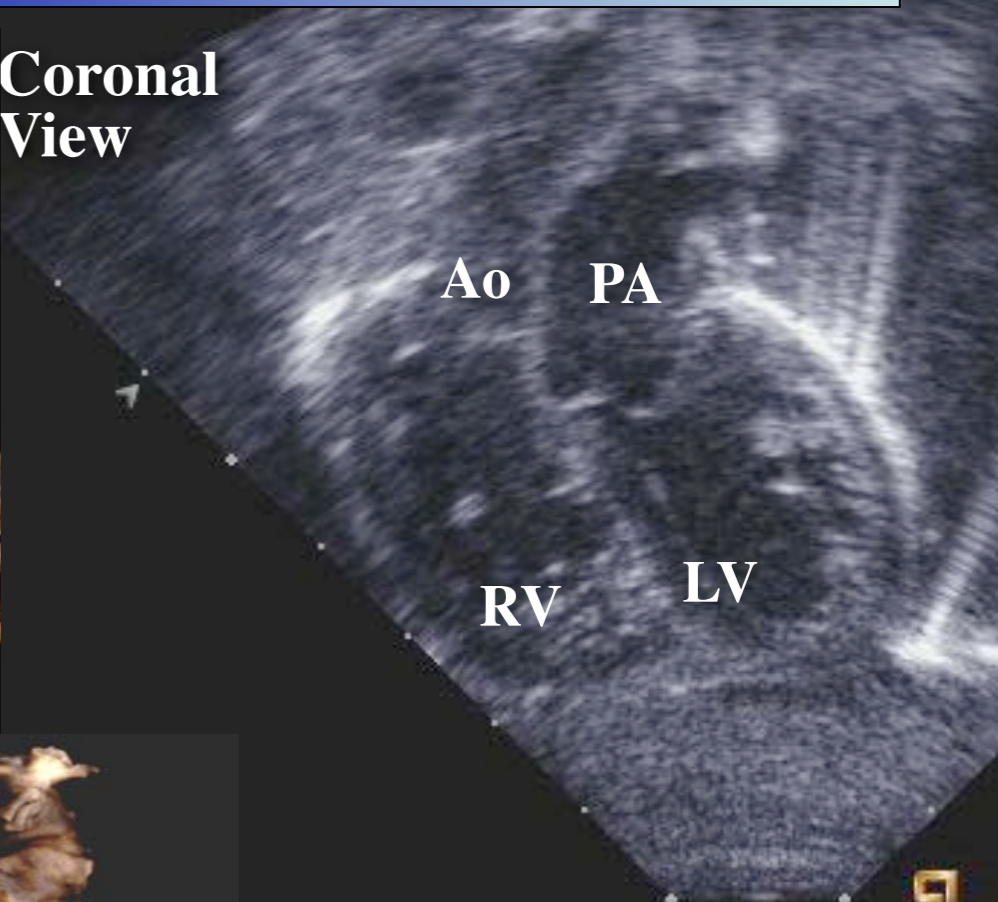
TGA: Subcostal Oblique Imaging



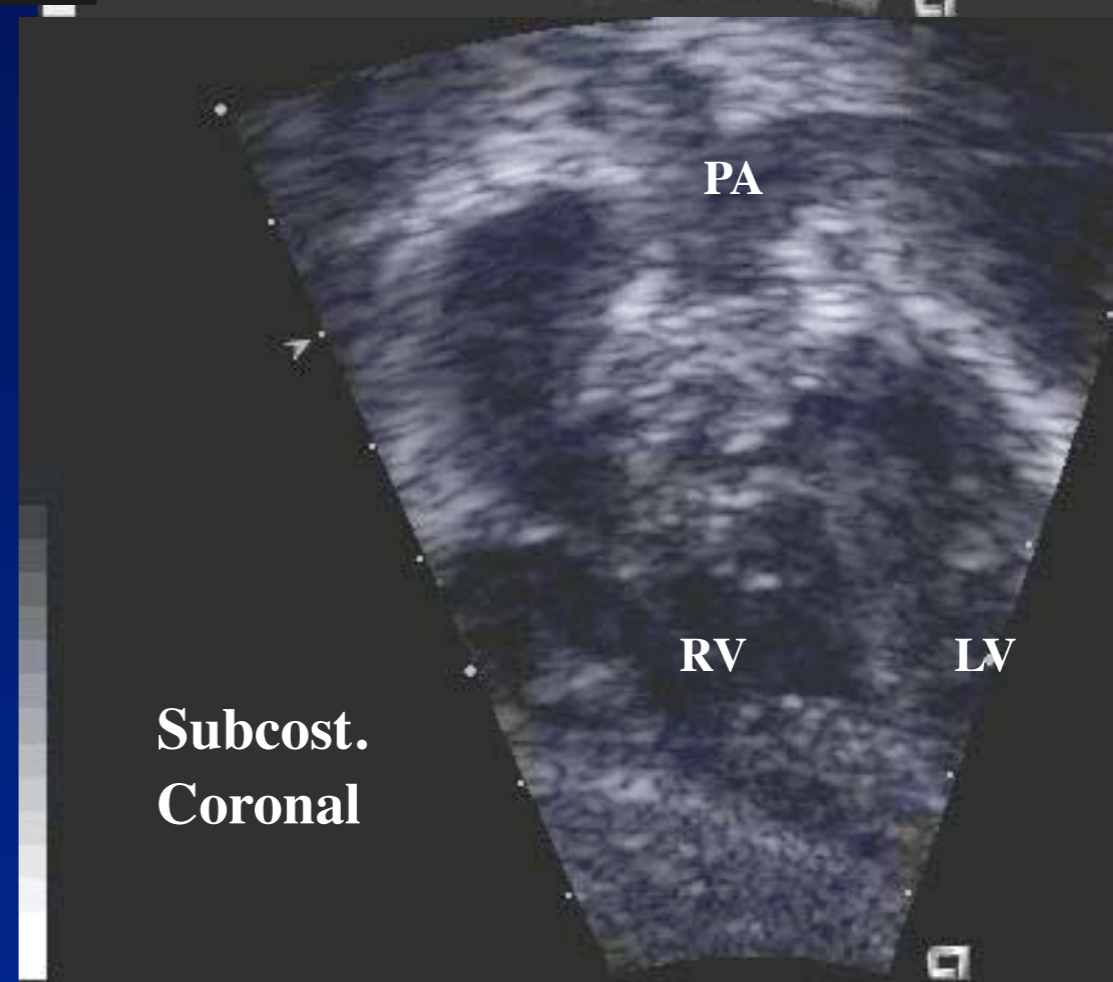
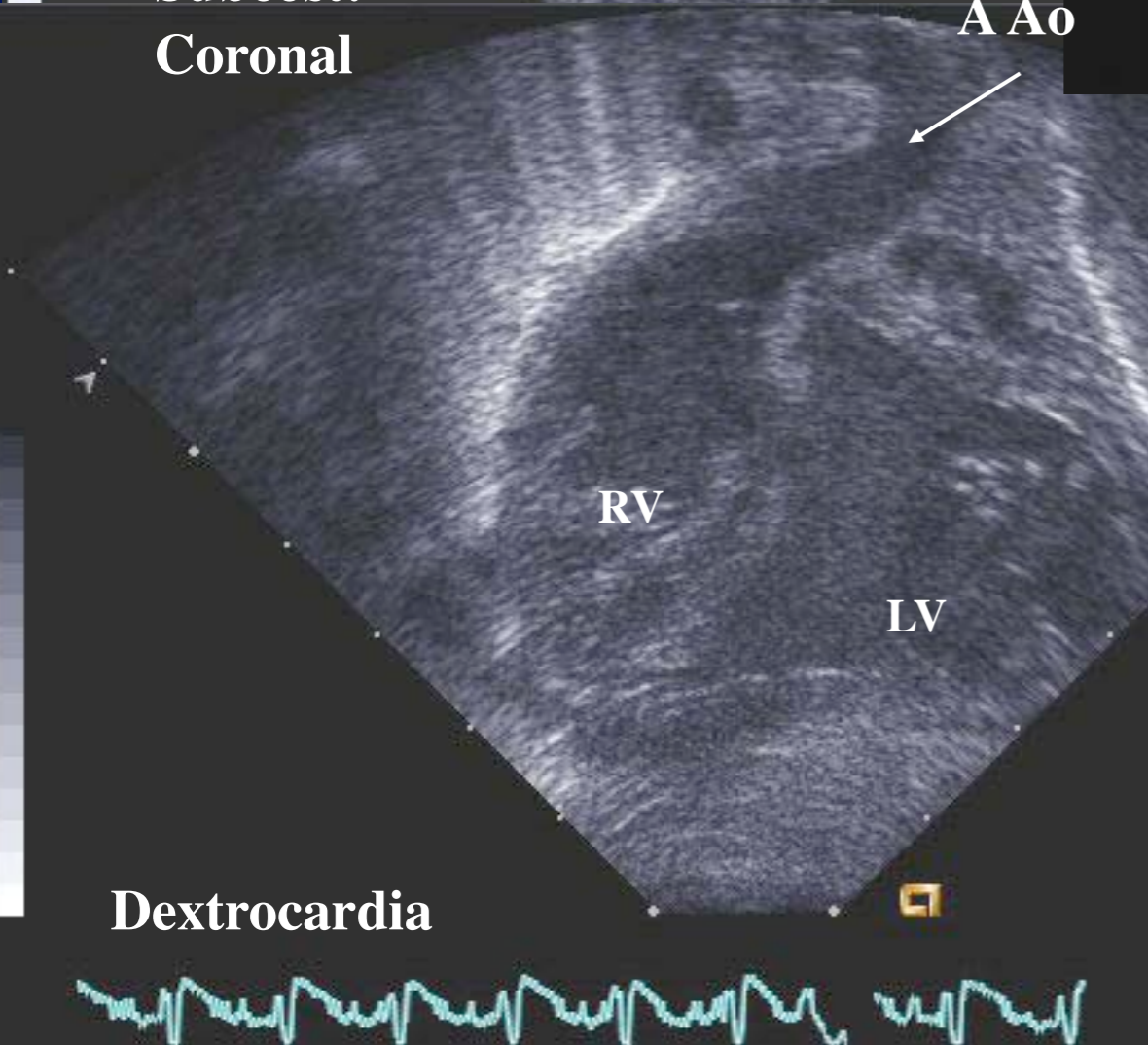
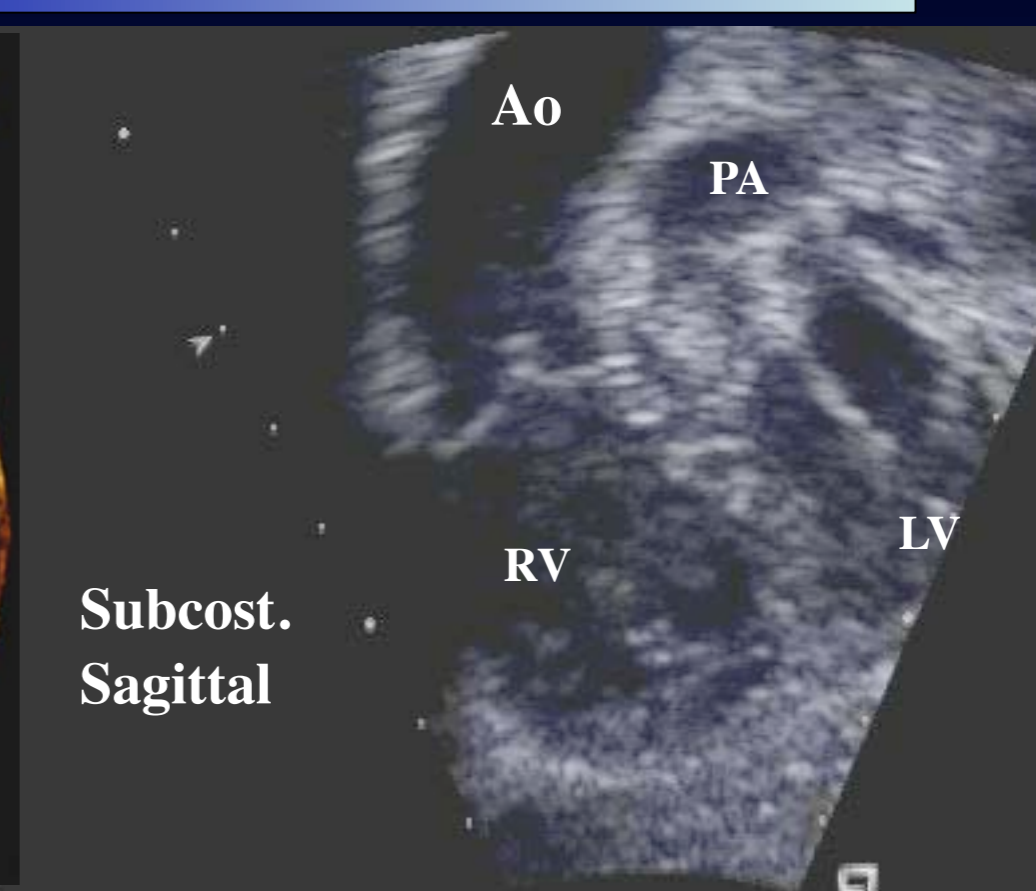
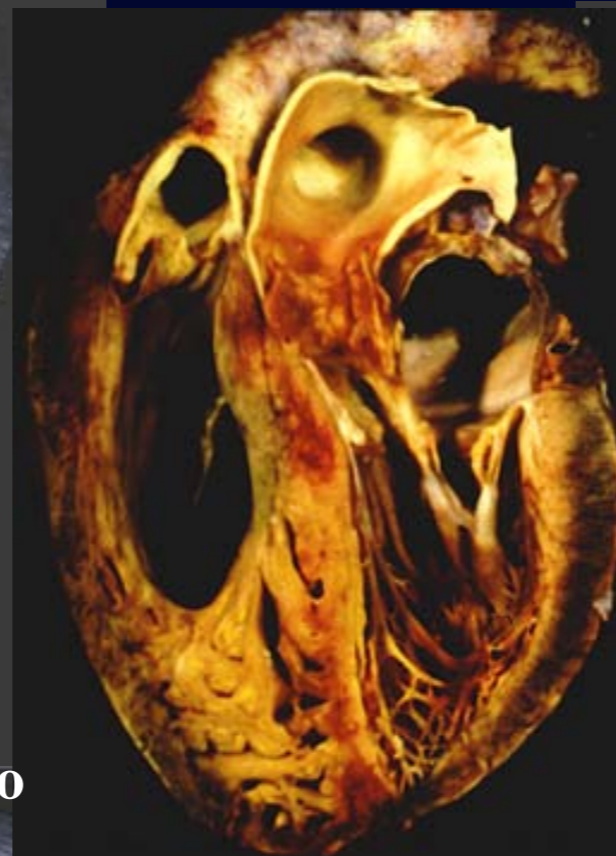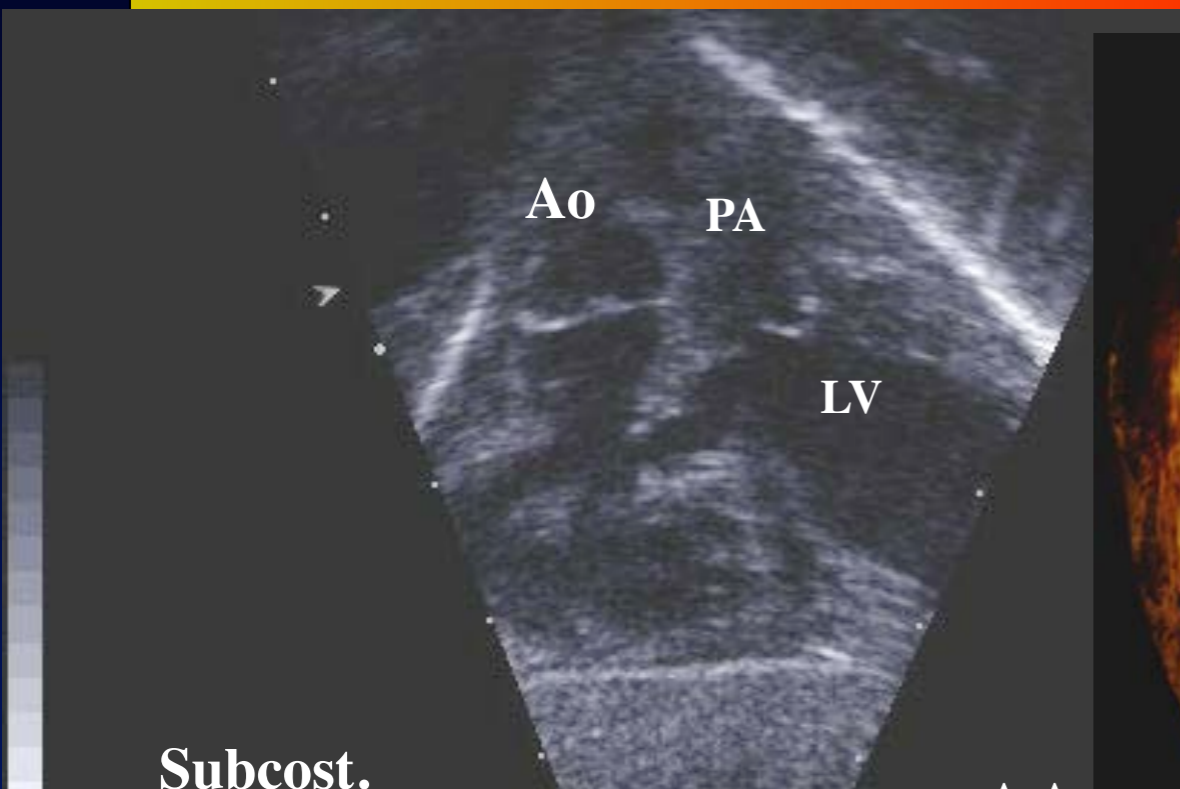
**Coroanl
For PA's**



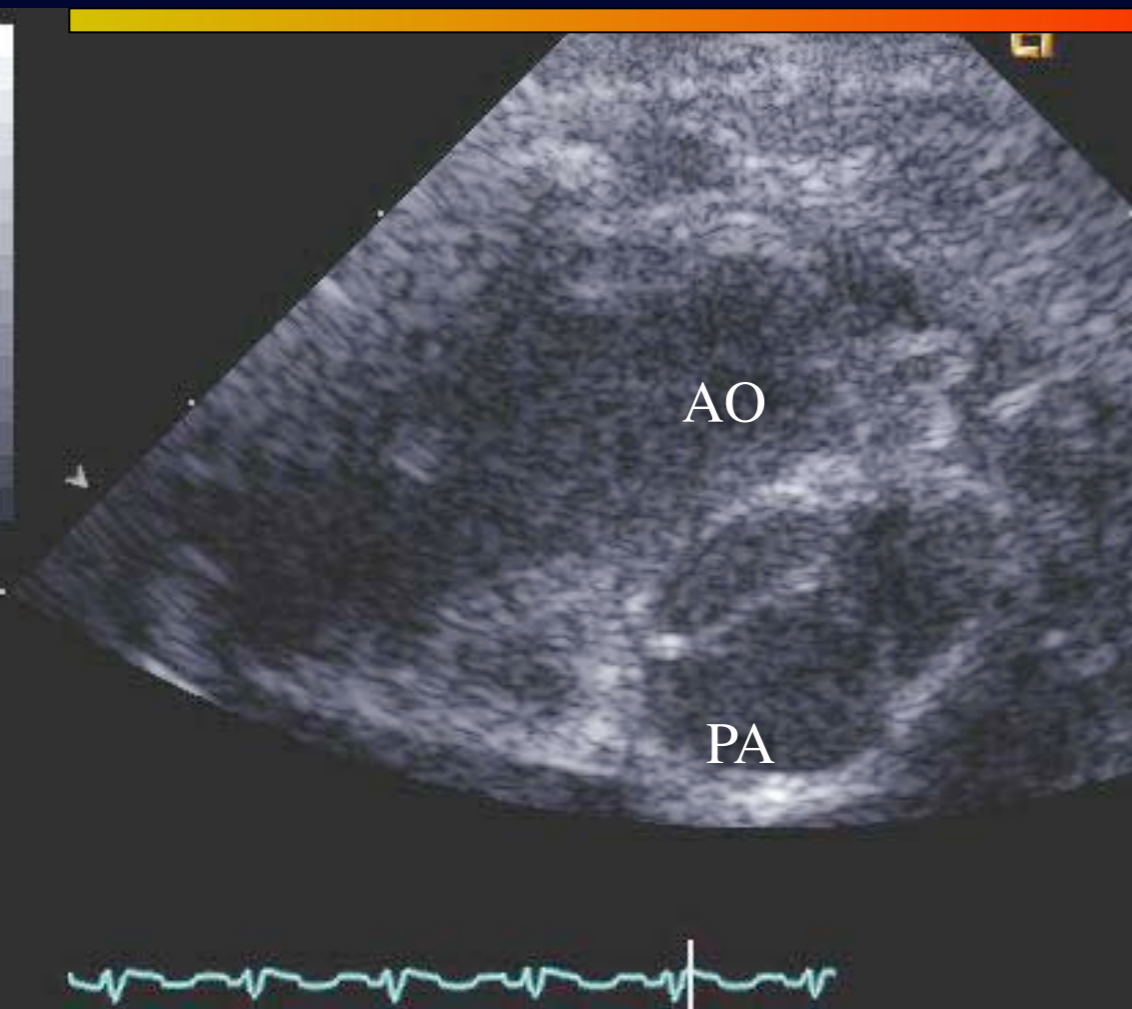
**Coronal
View**



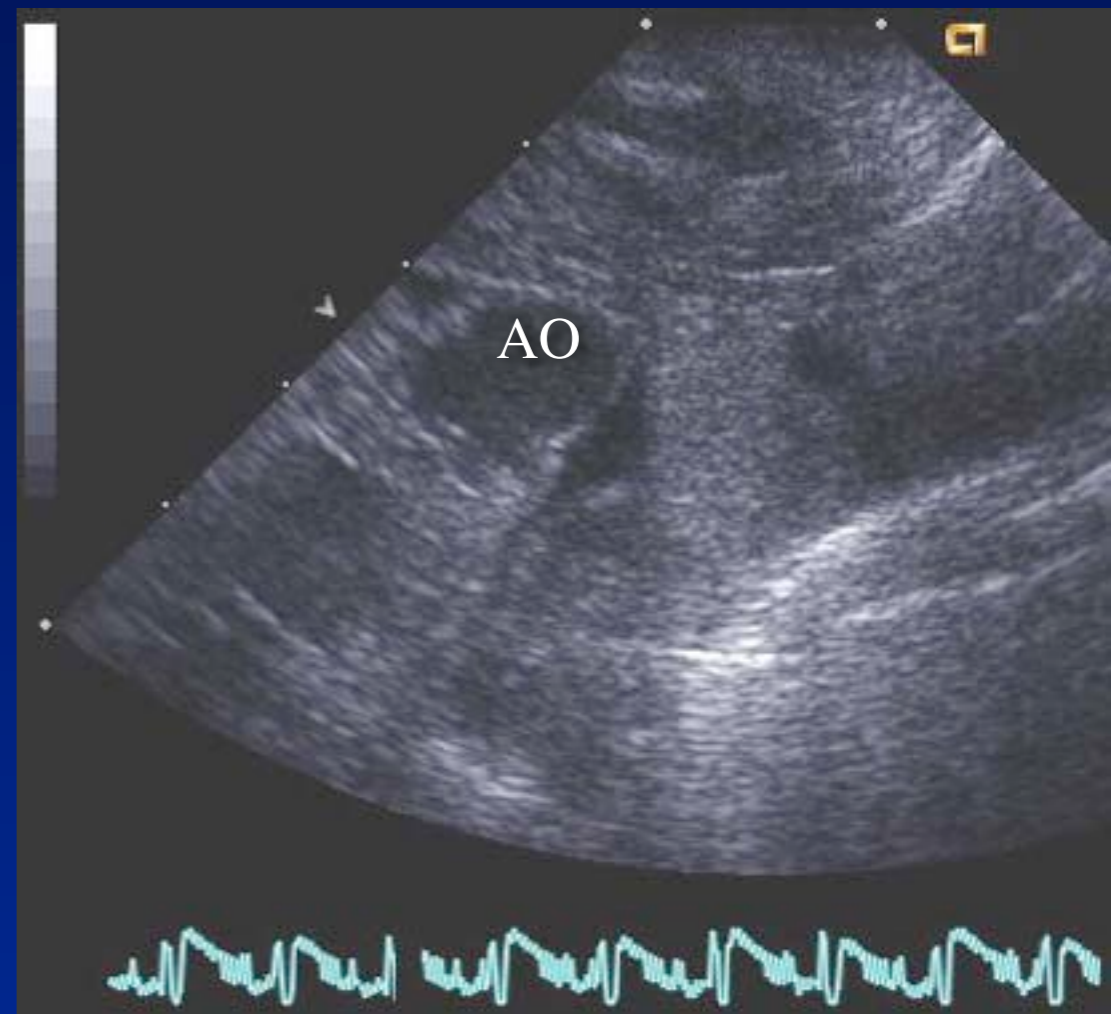
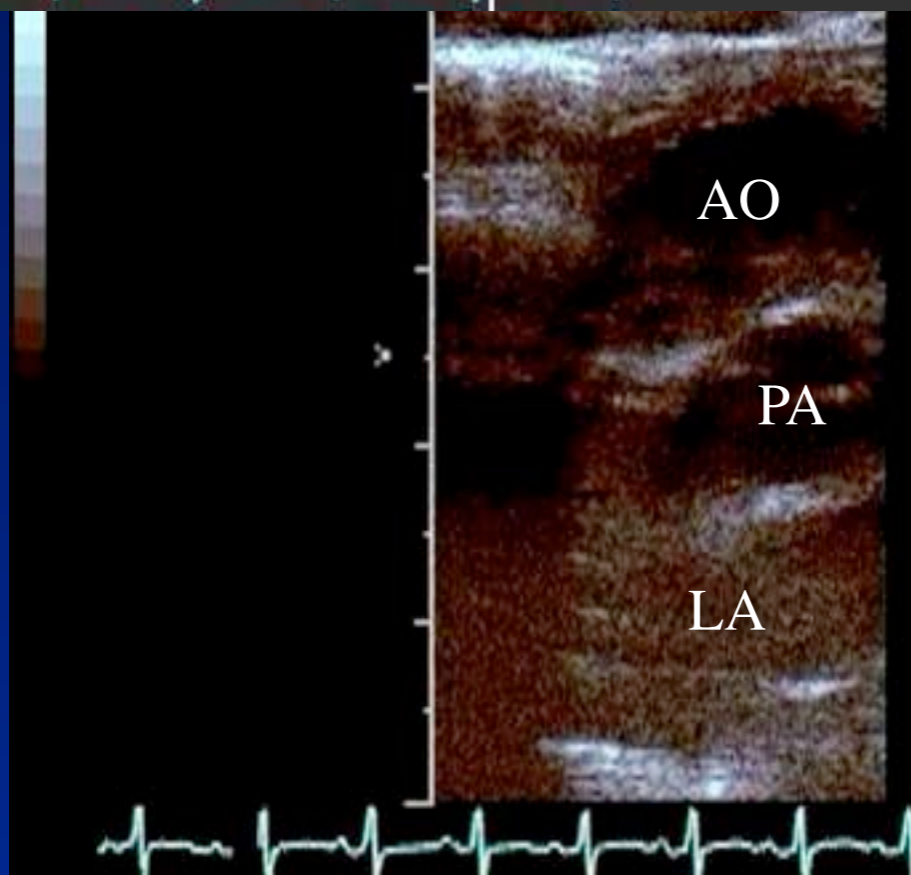
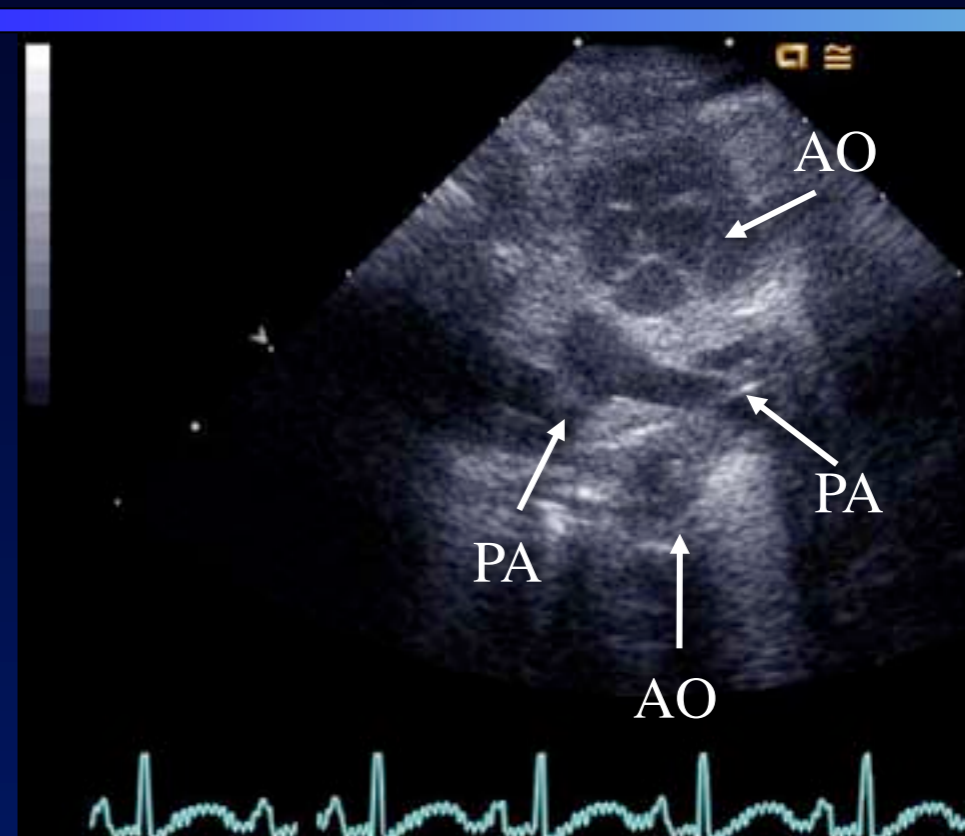
TGA: Subcostal Oblique Views



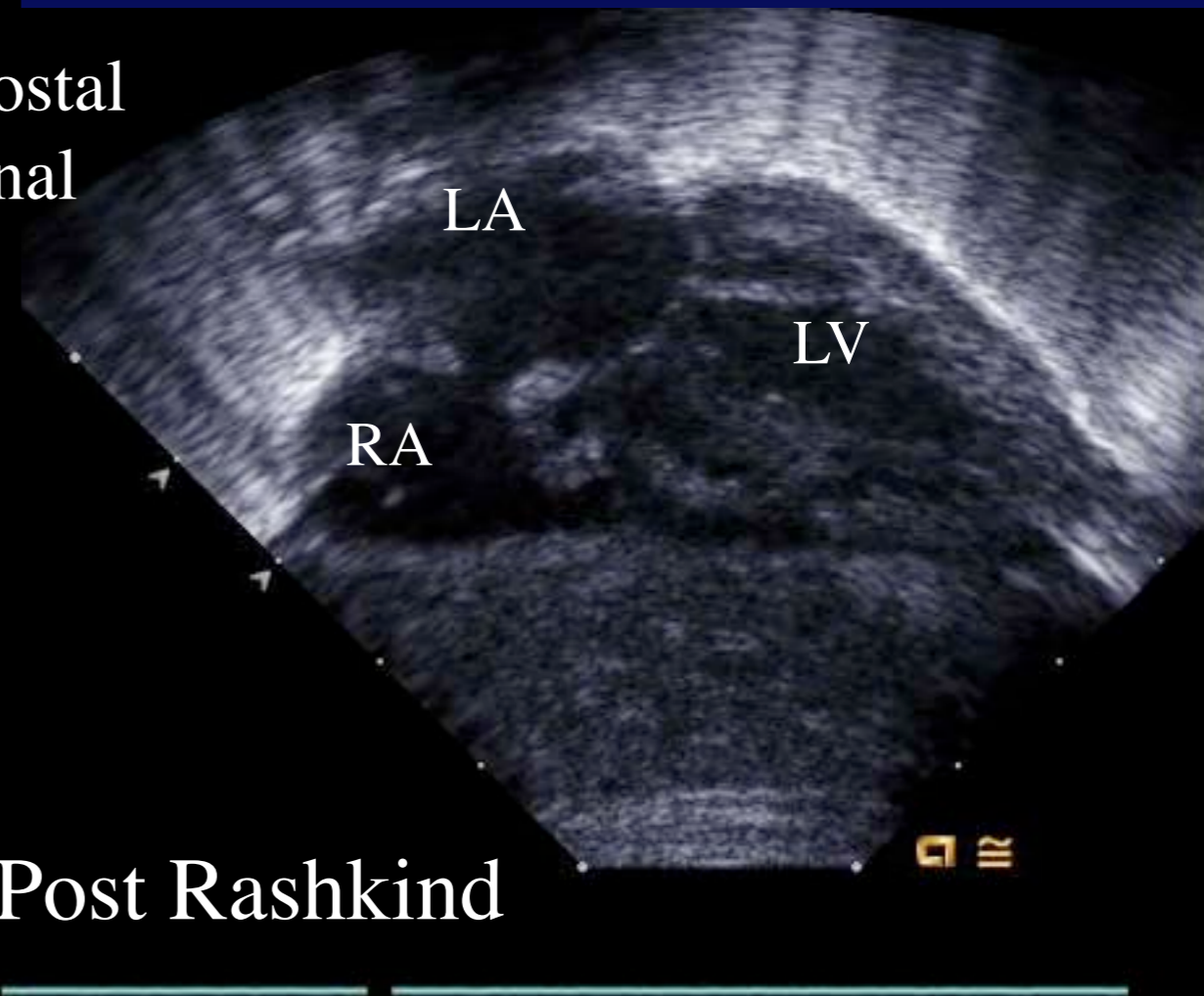
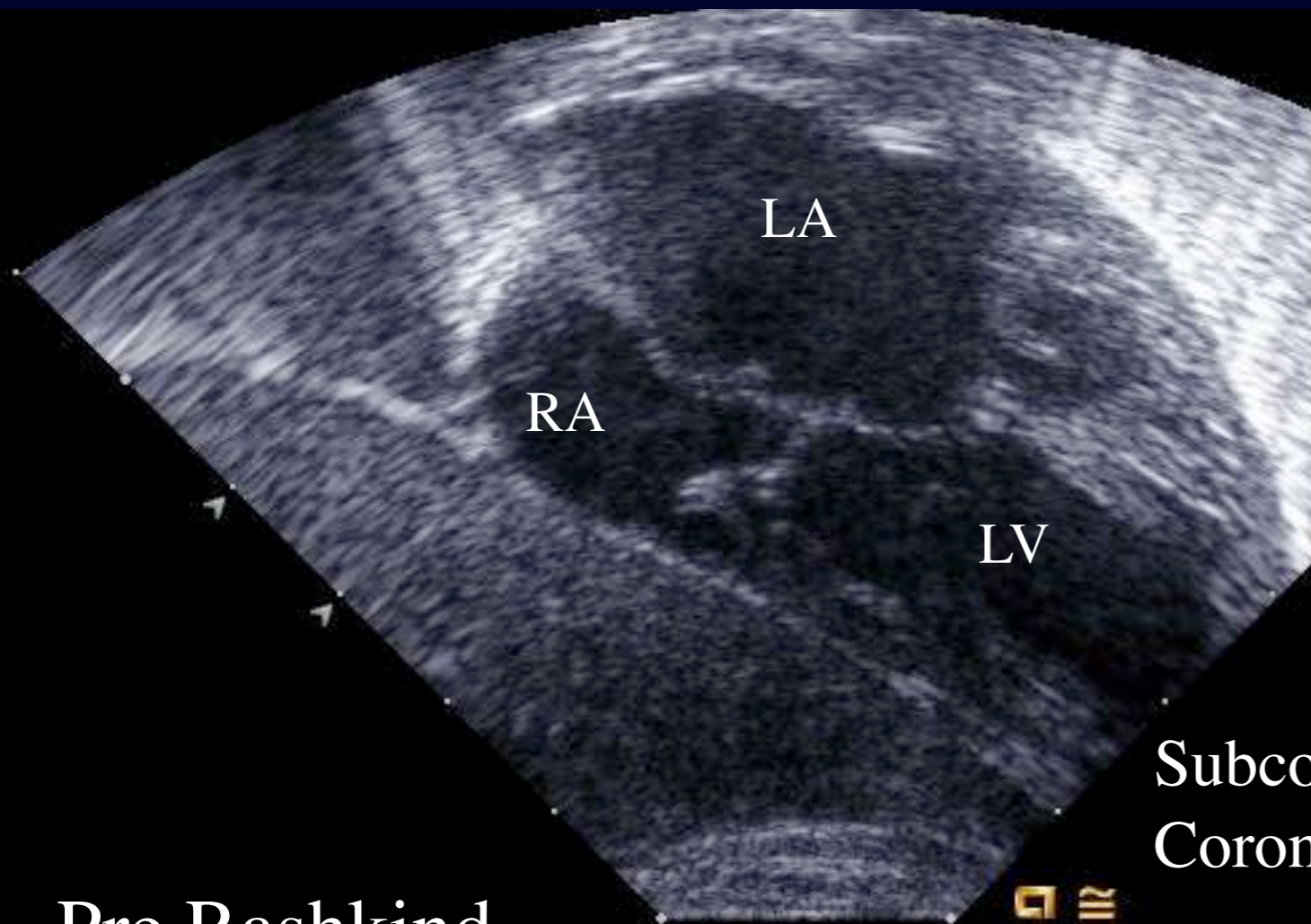
Position of Aorta and Pulmonary Arteries



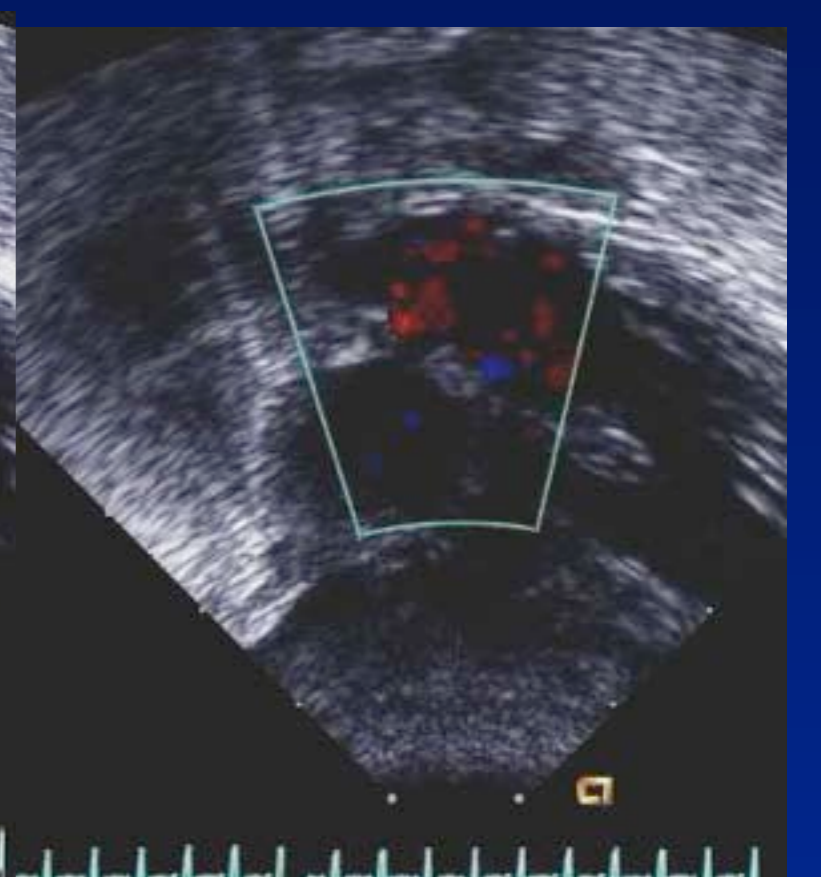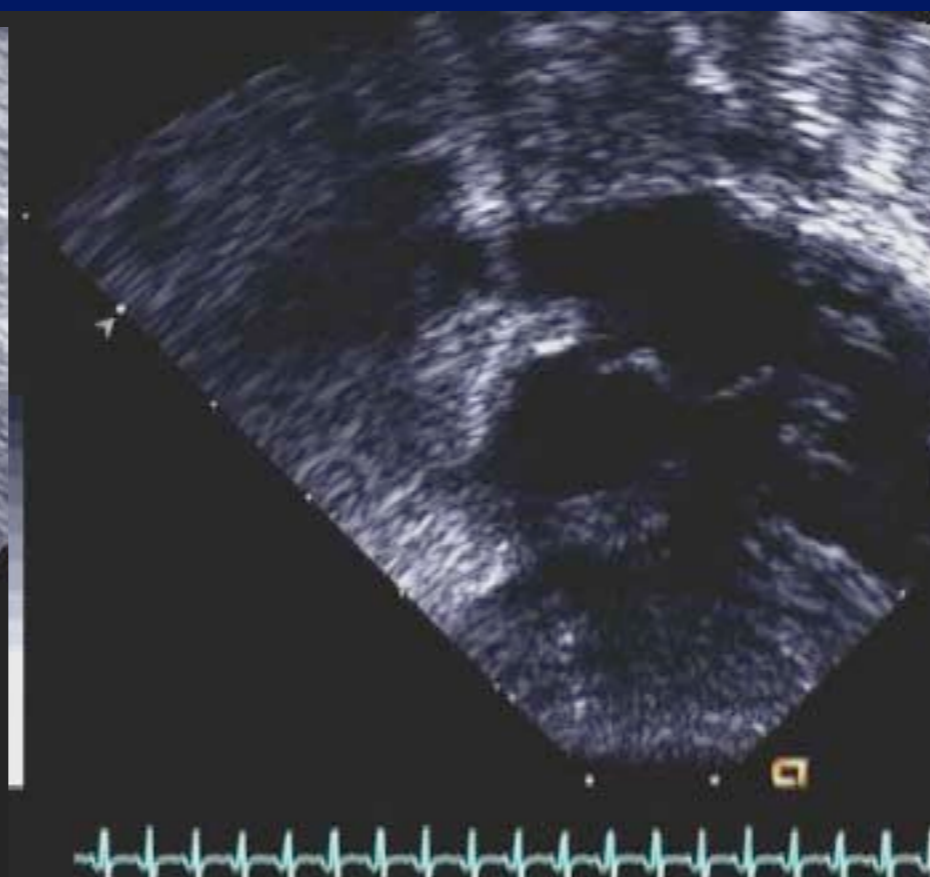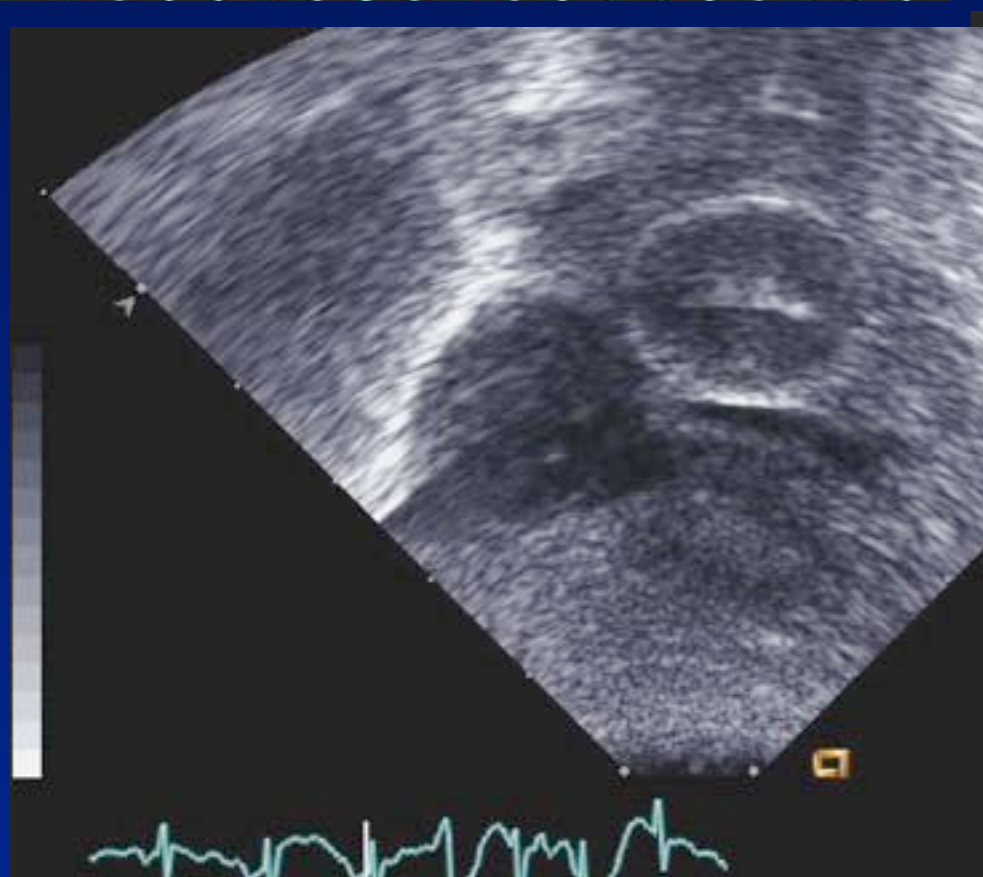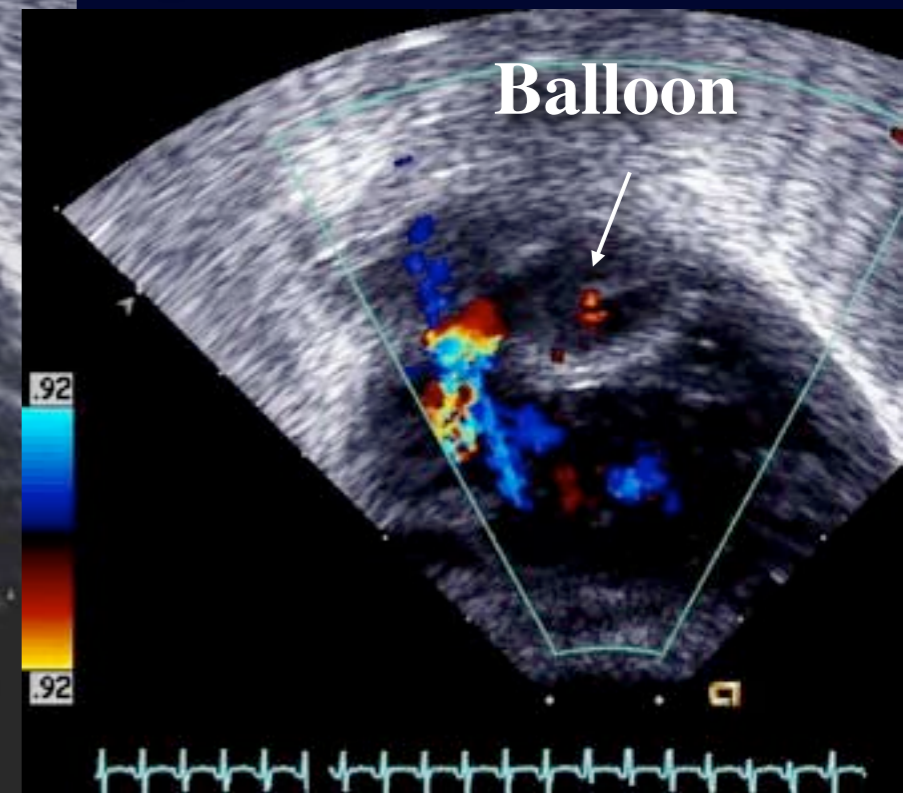
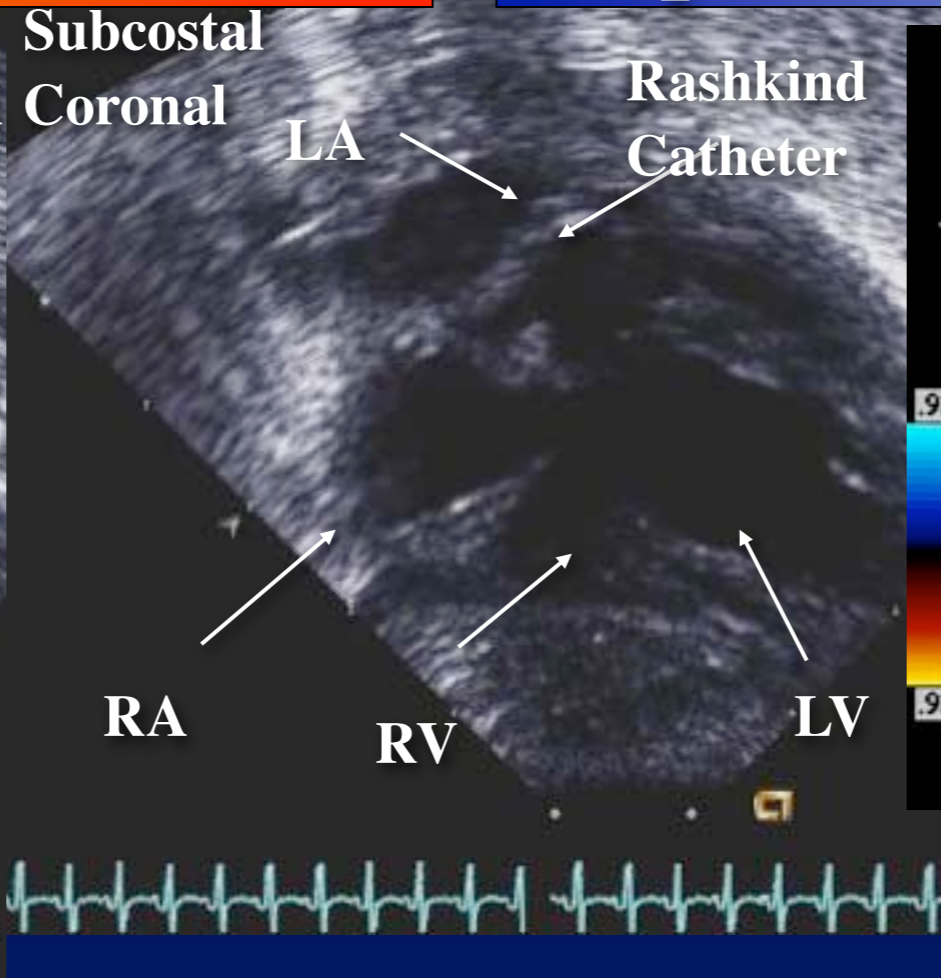
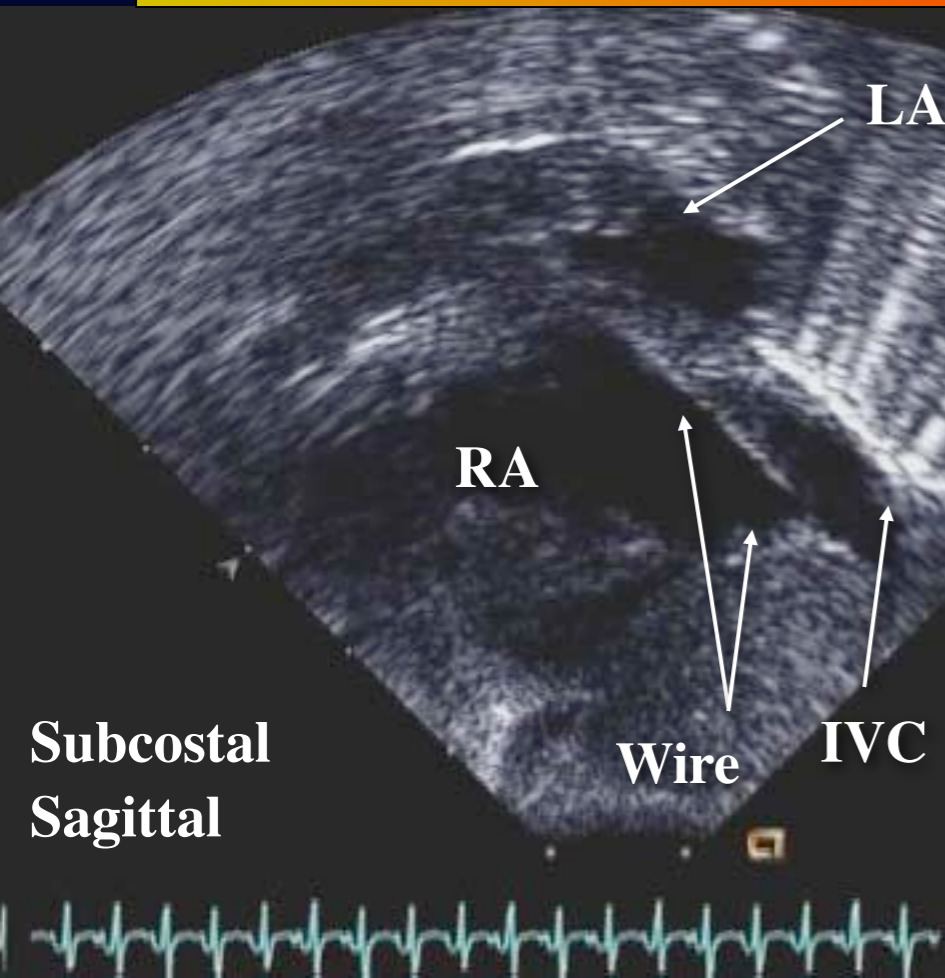
P Sax



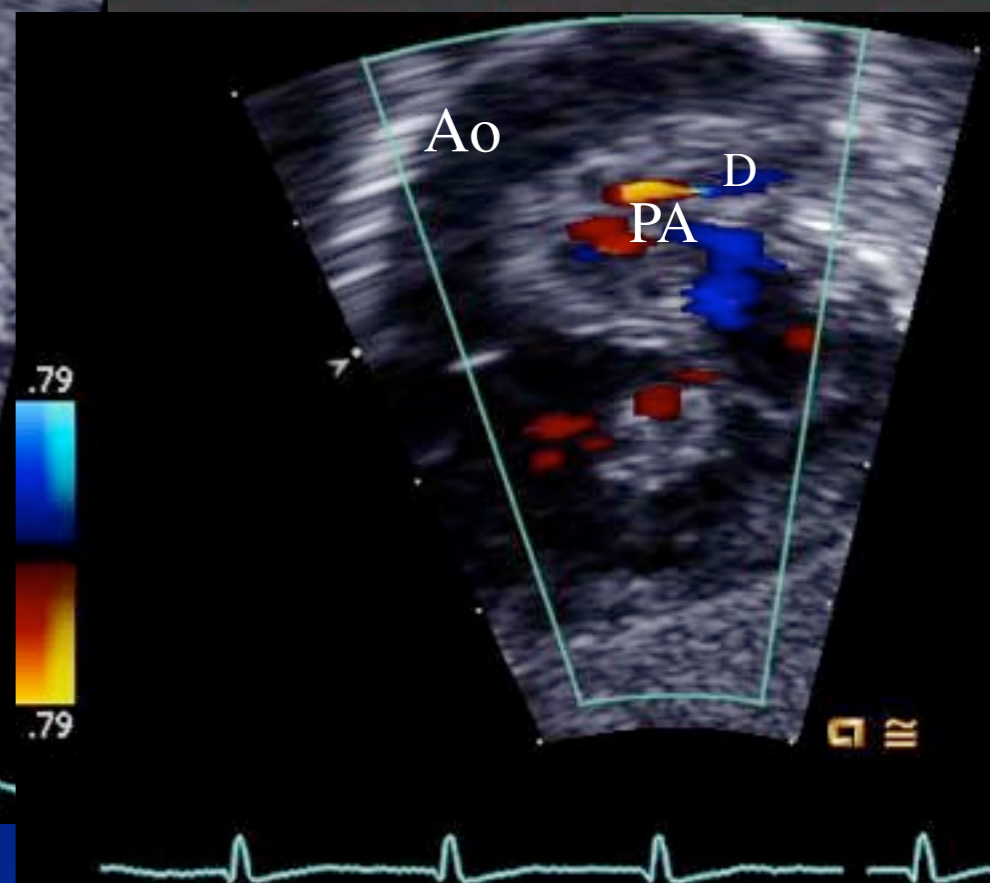
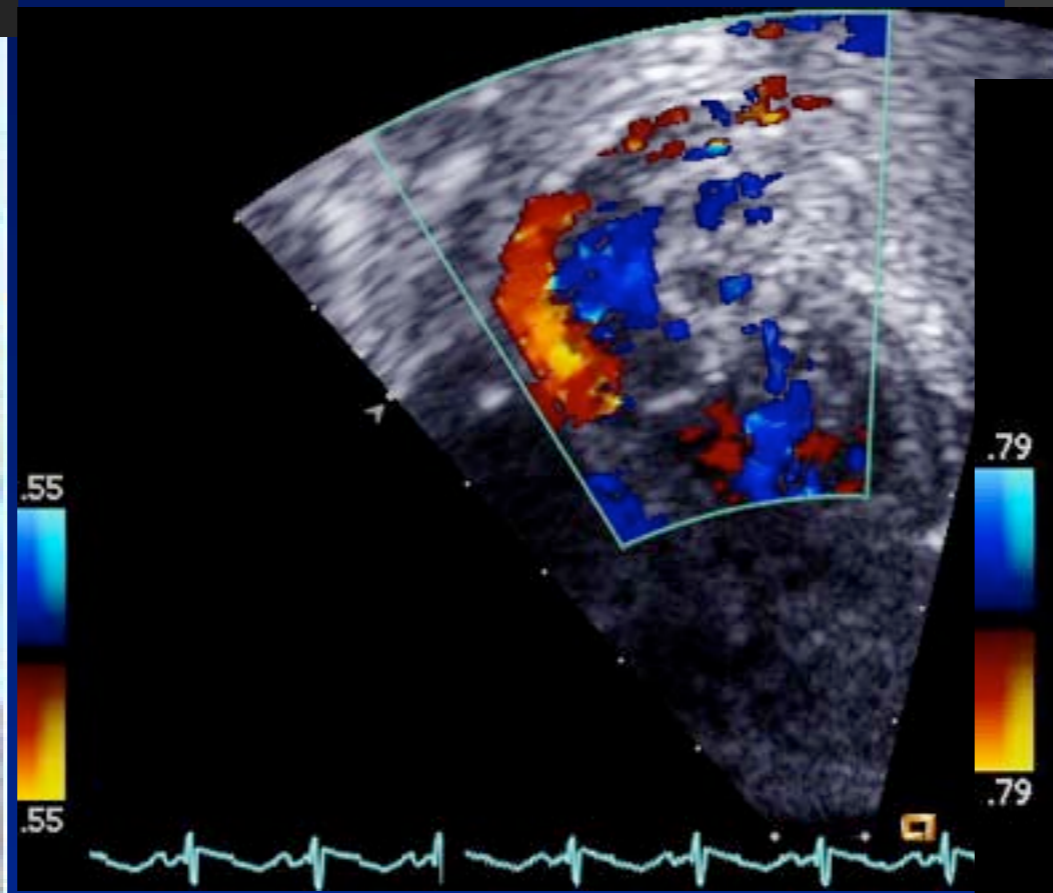
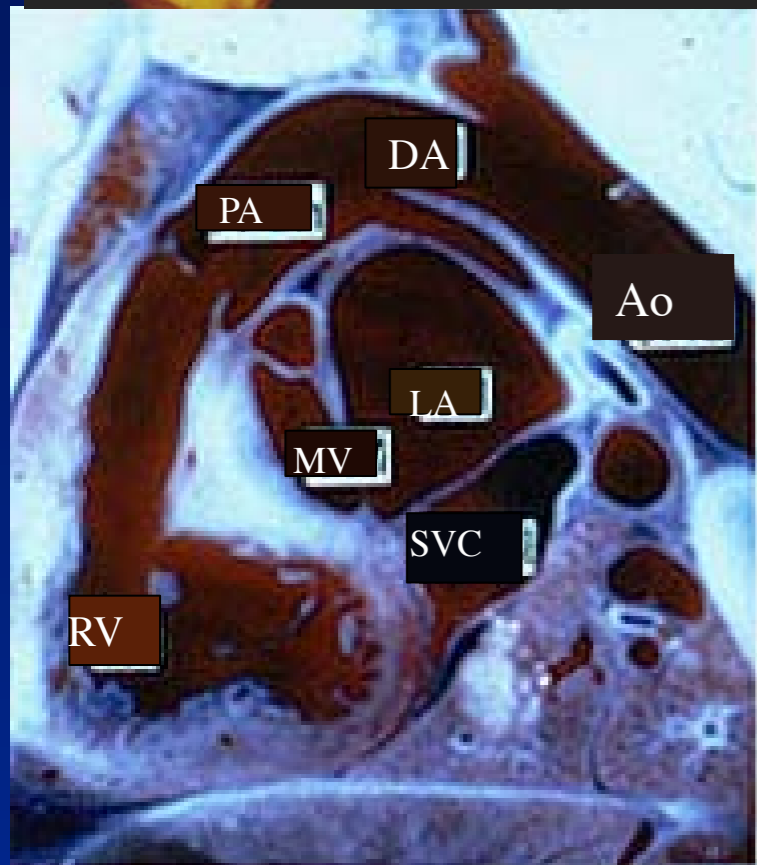
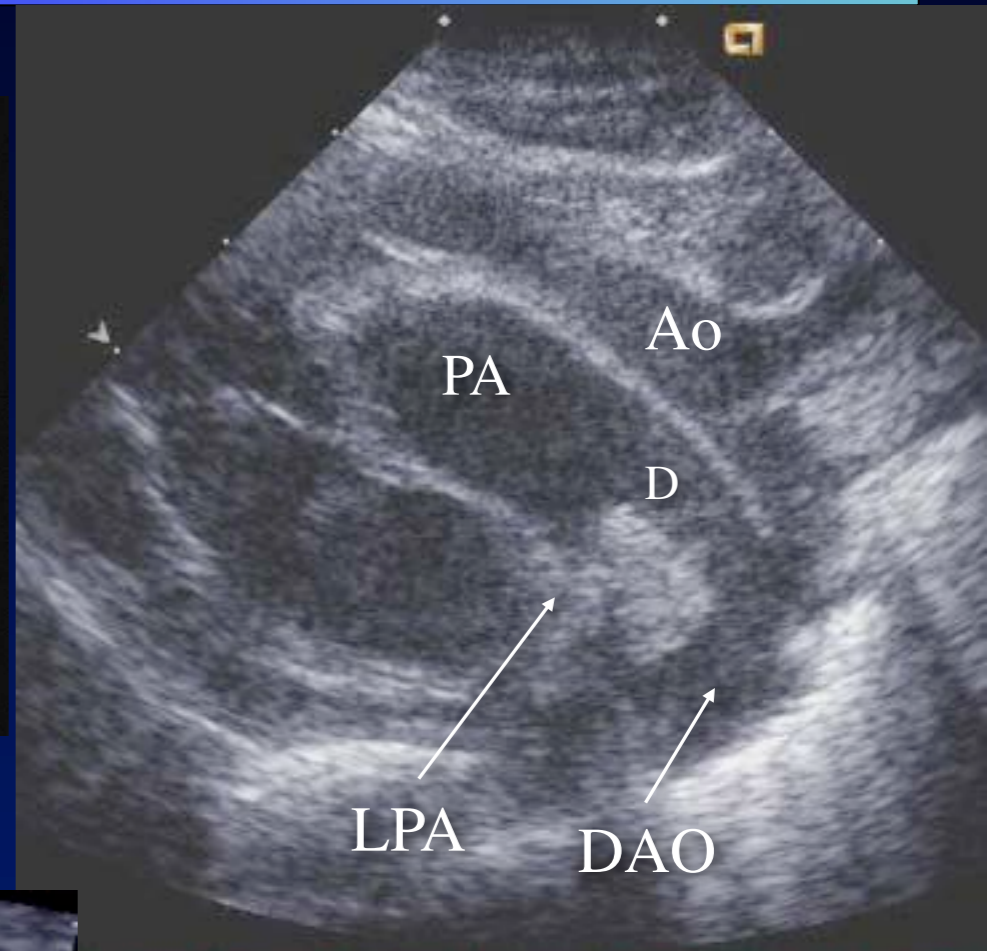
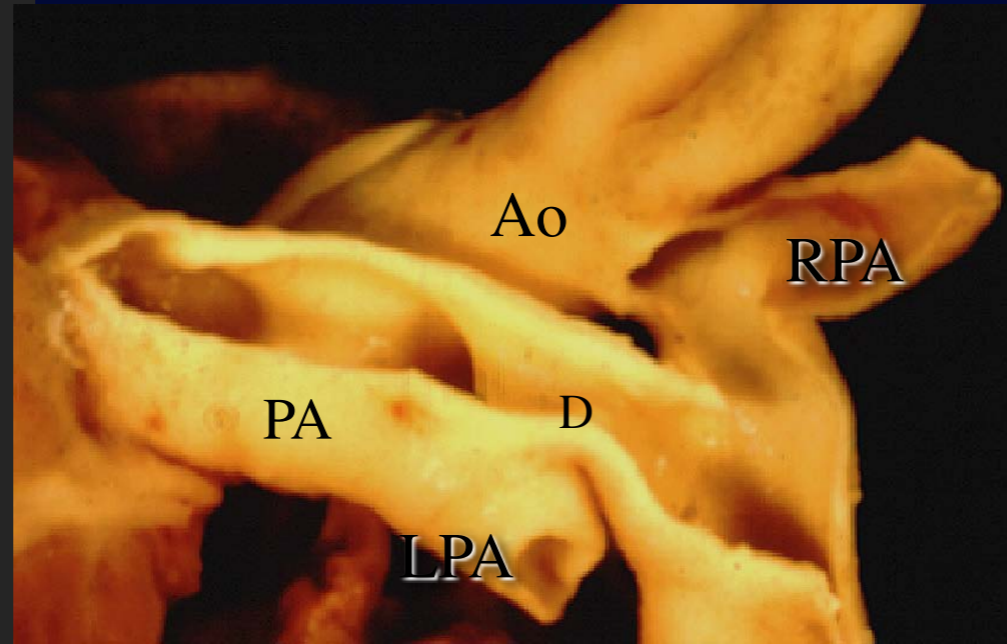
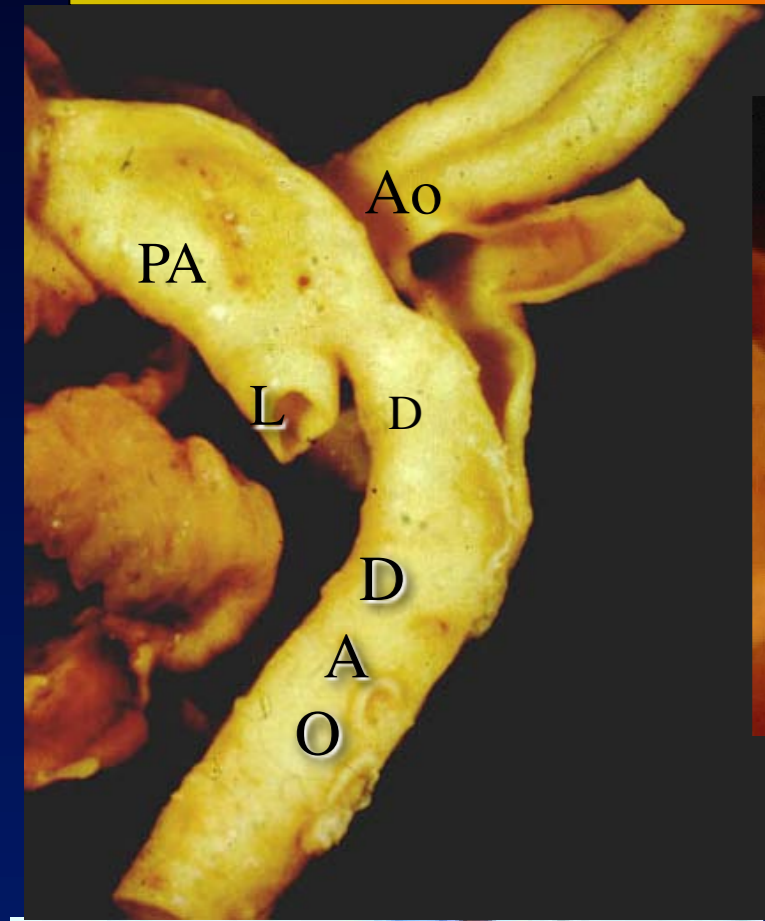Immediate Postnatal ECHO For Cyanosis++



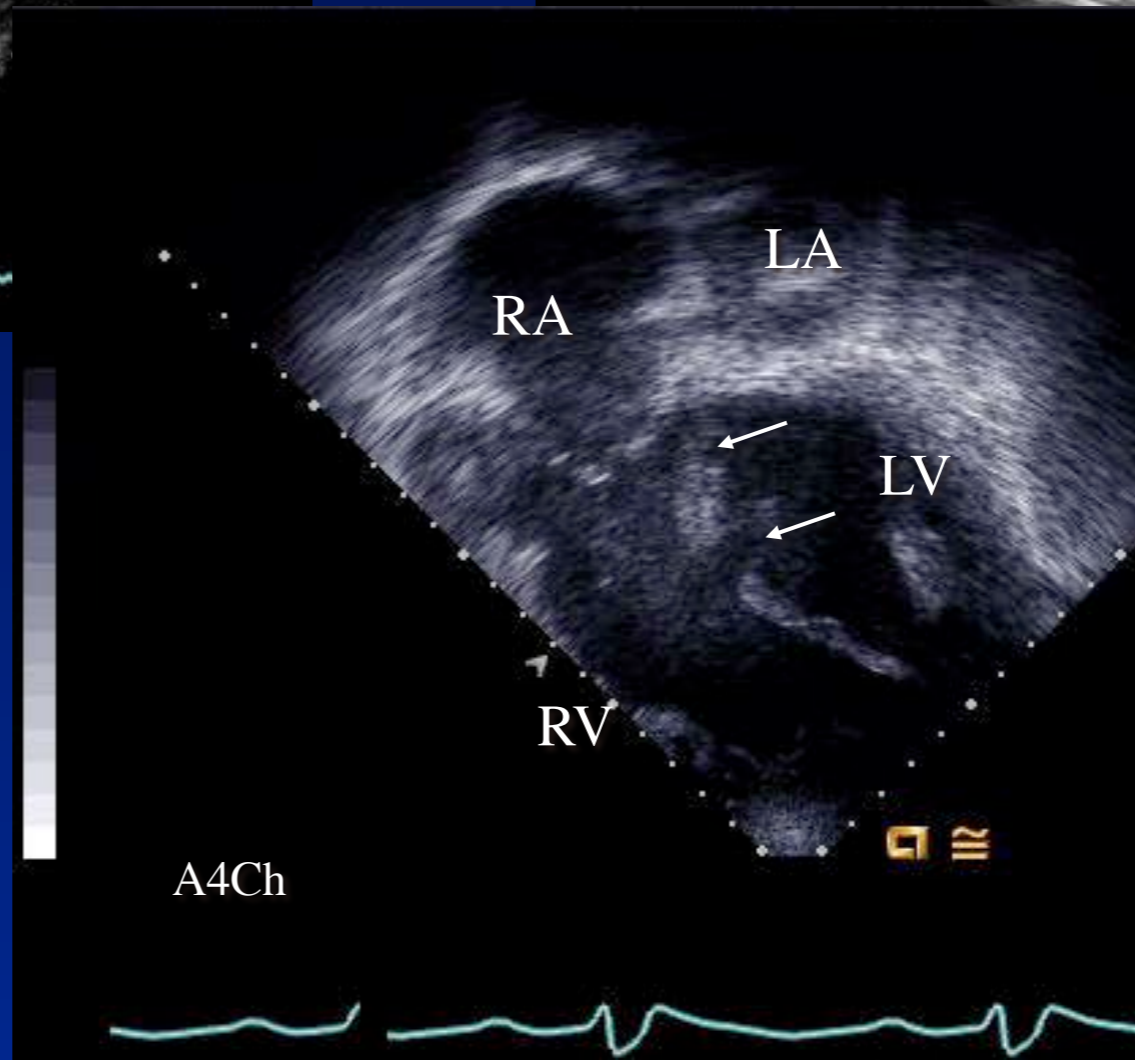
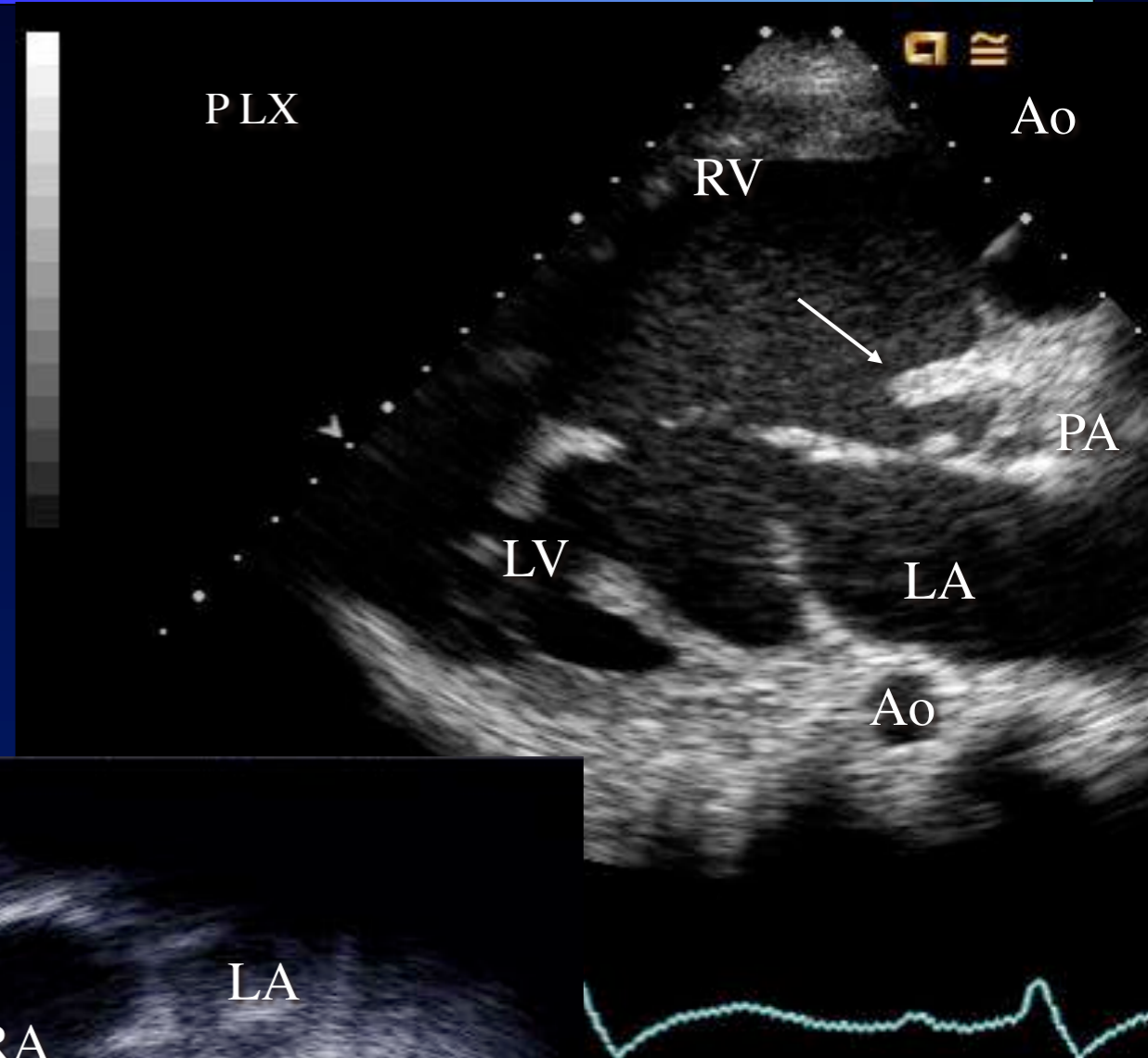
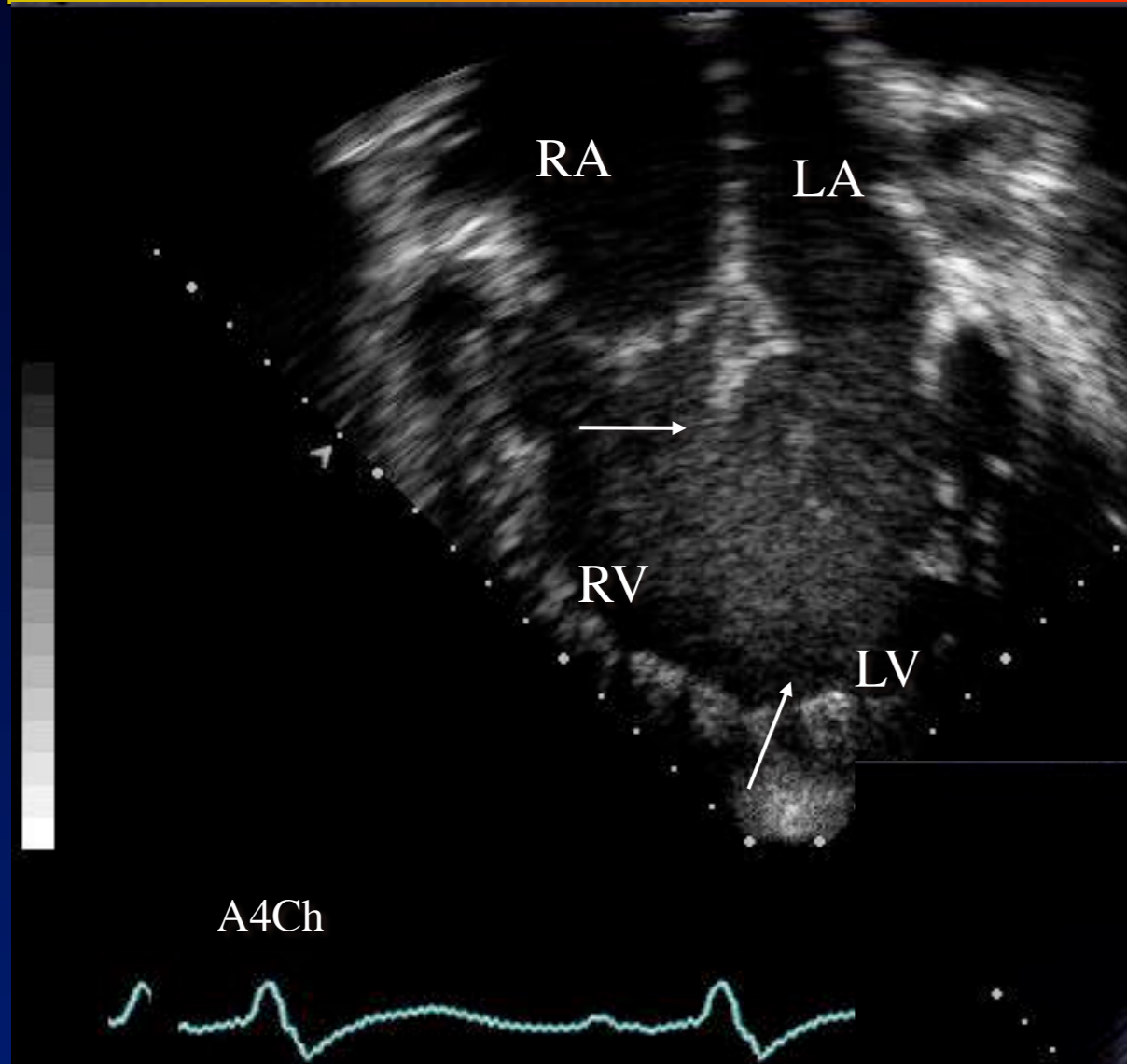
TGA : Balloon Septostomy



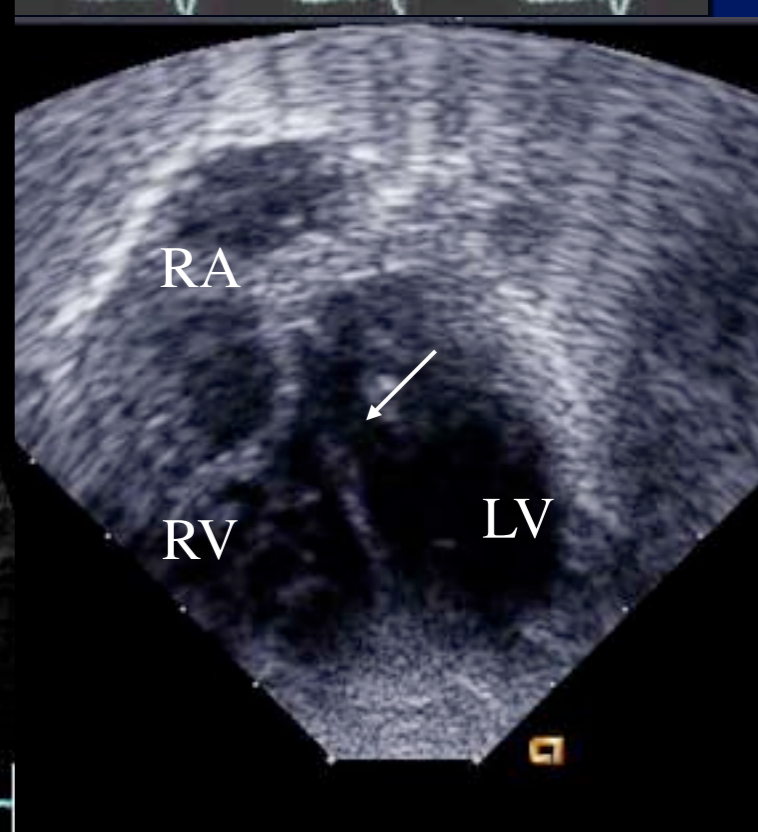
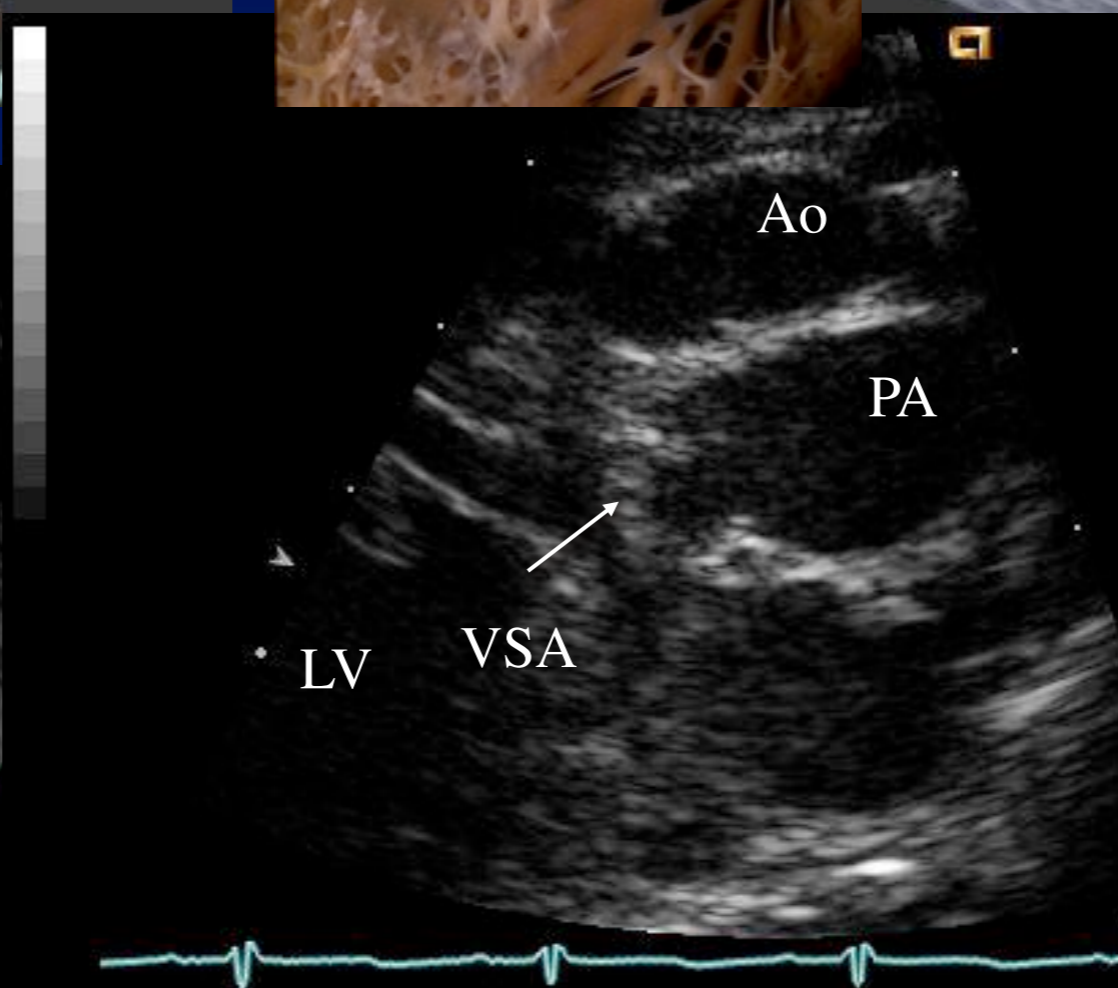
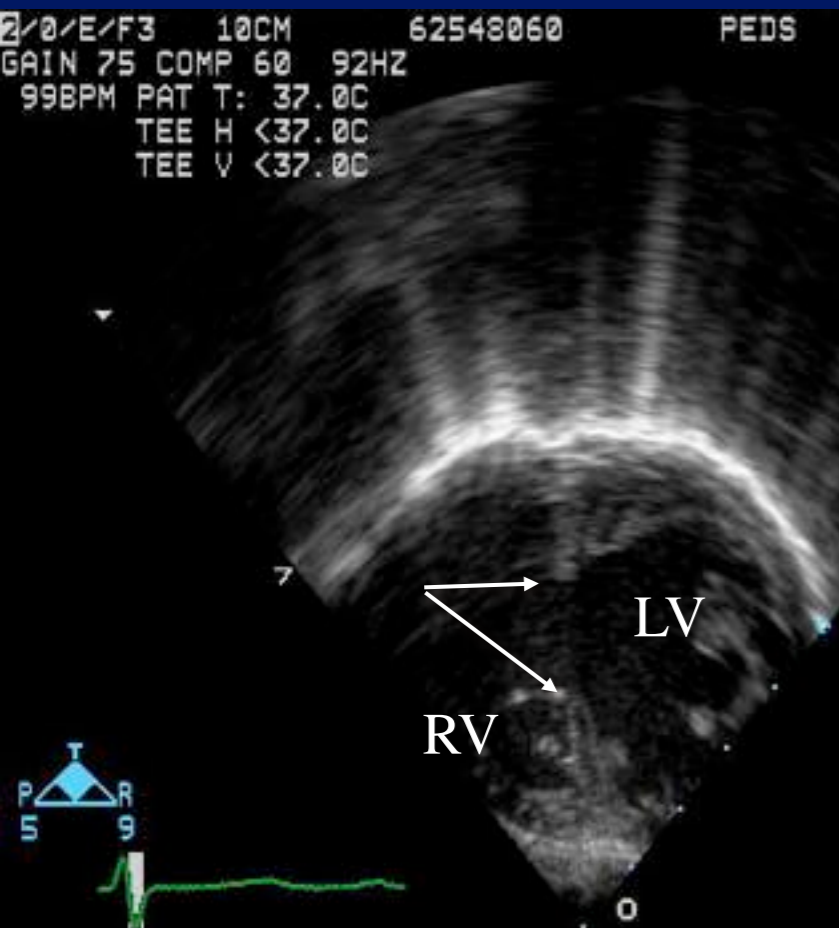
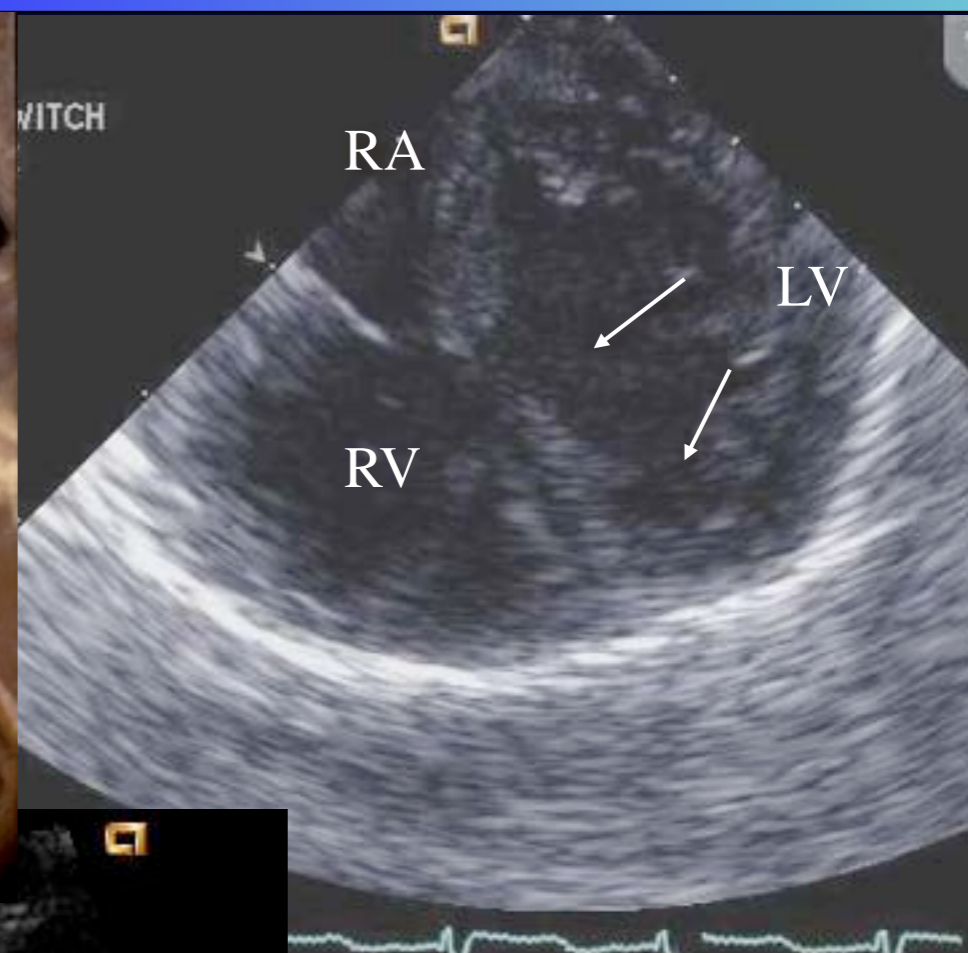
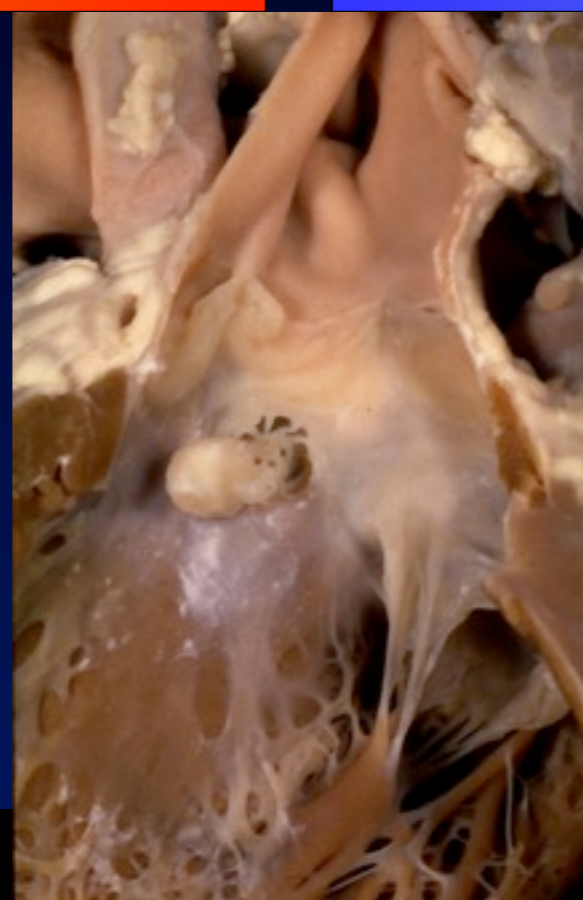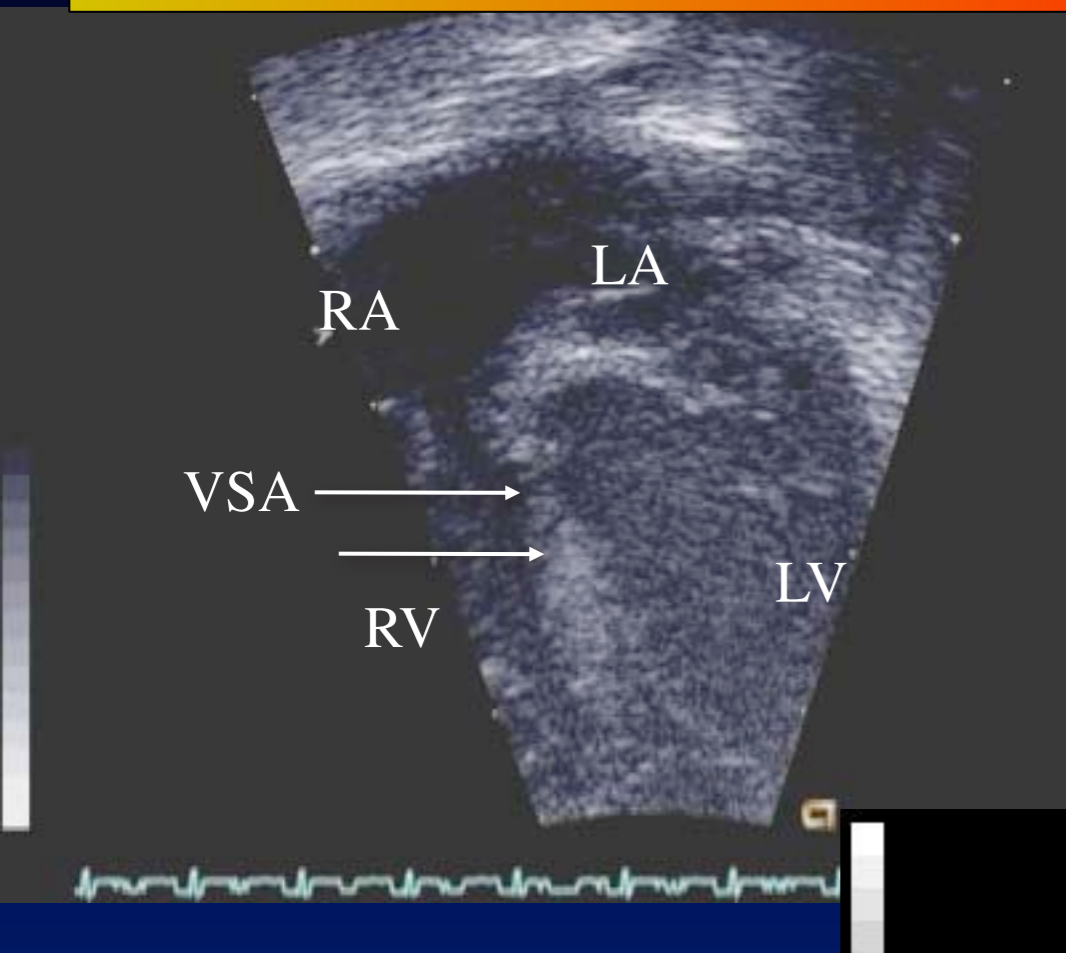
Patent Ductus Arteriosus in TGA



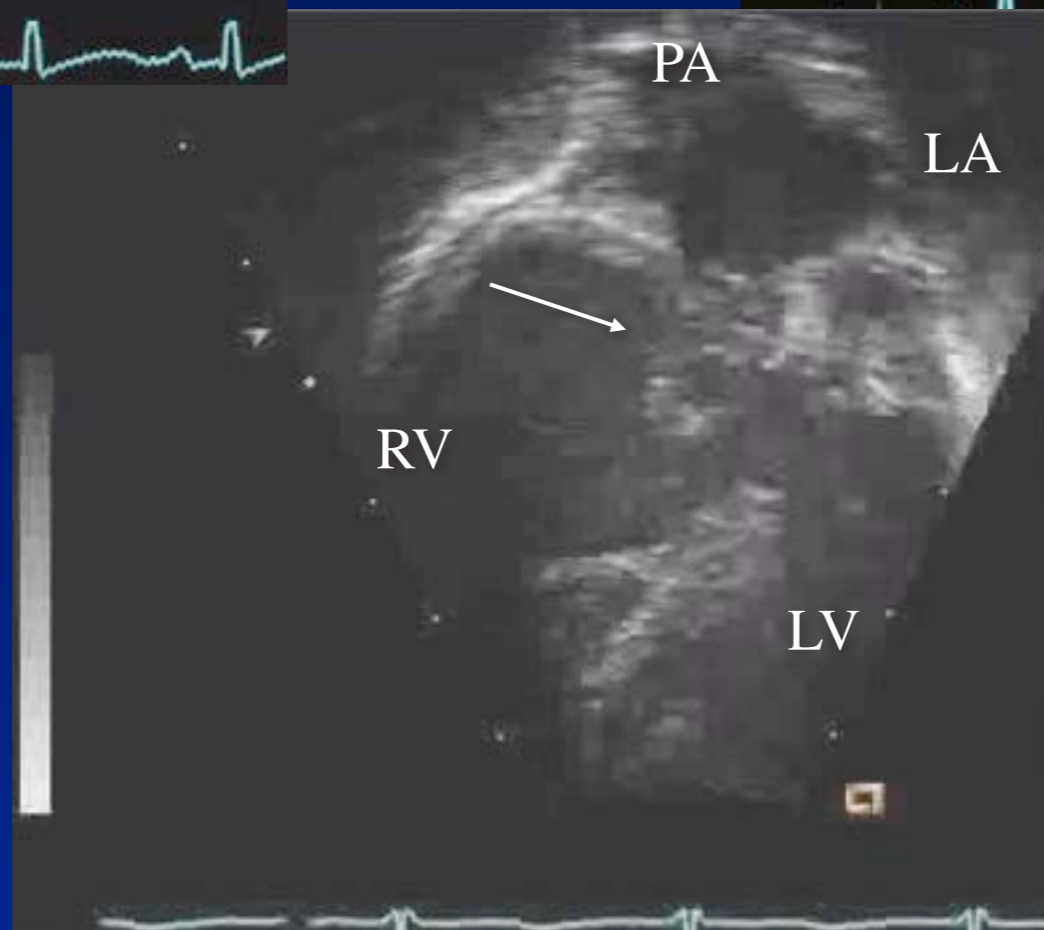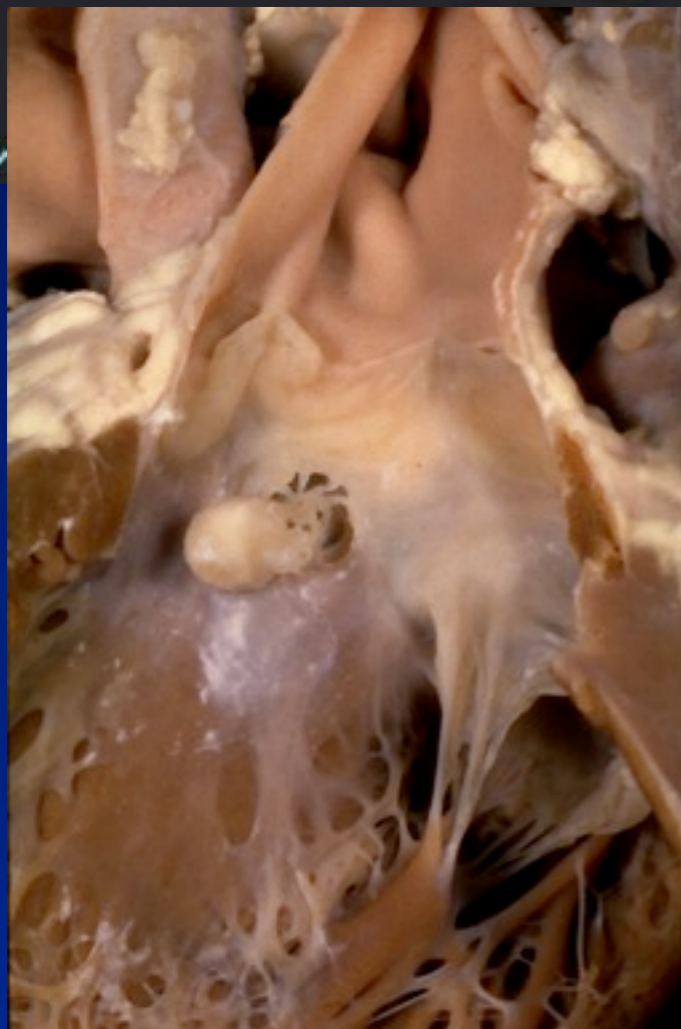
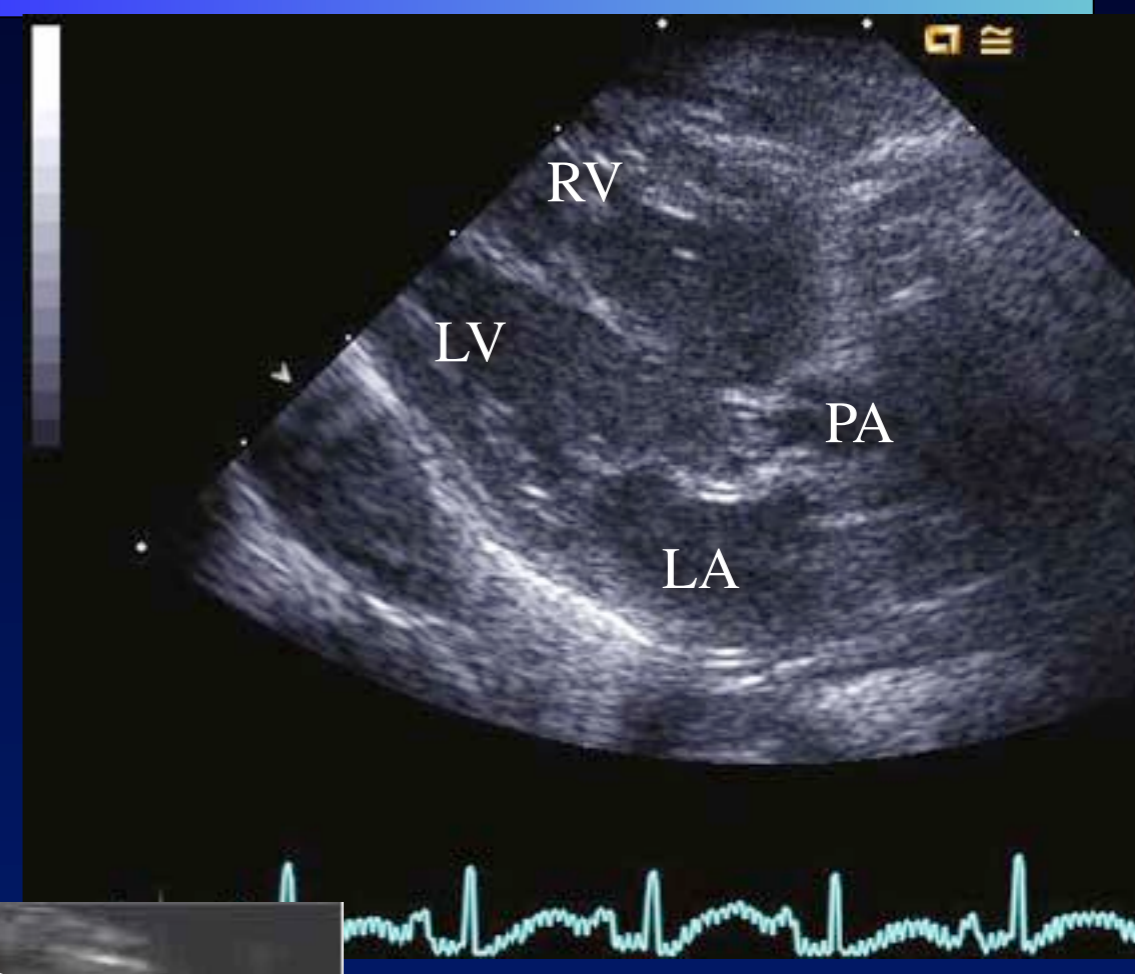
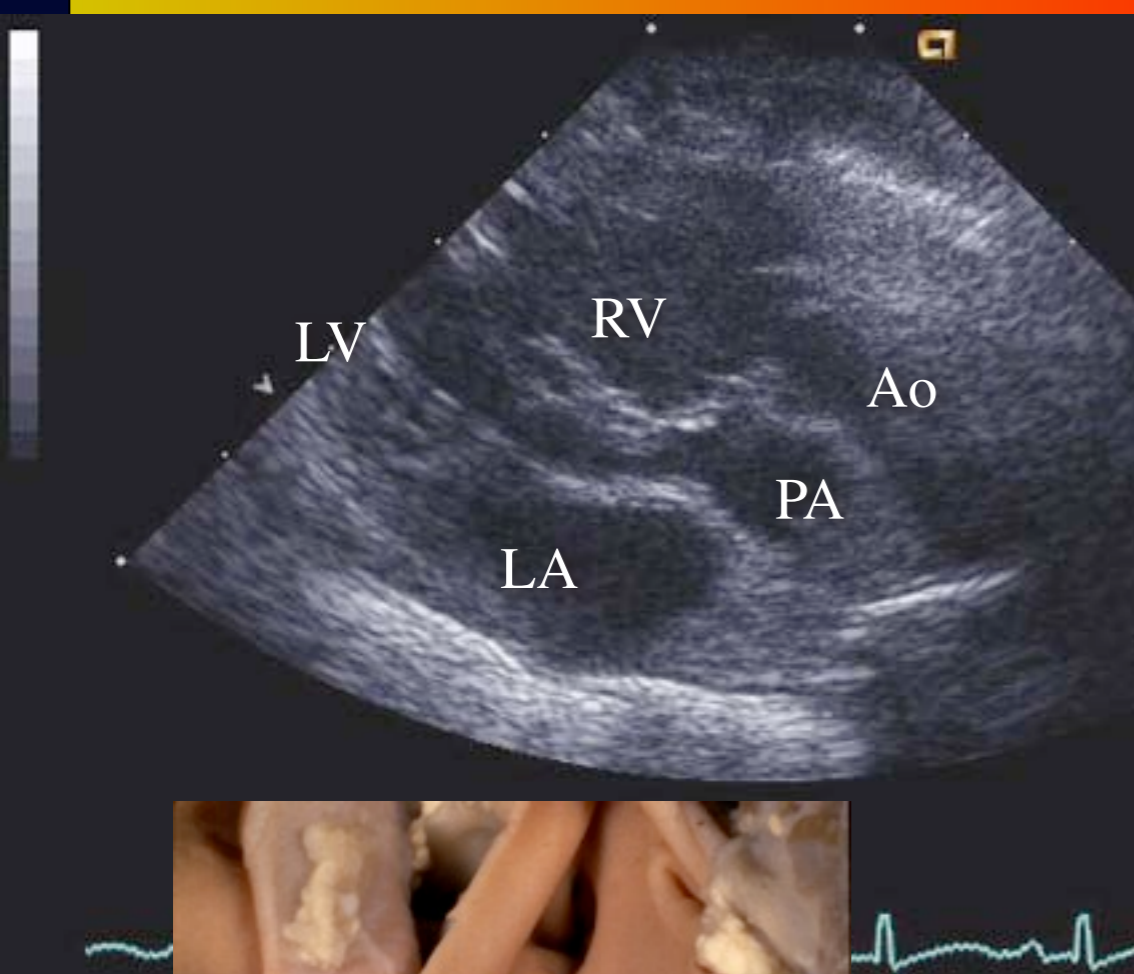
Confluent Large VSD



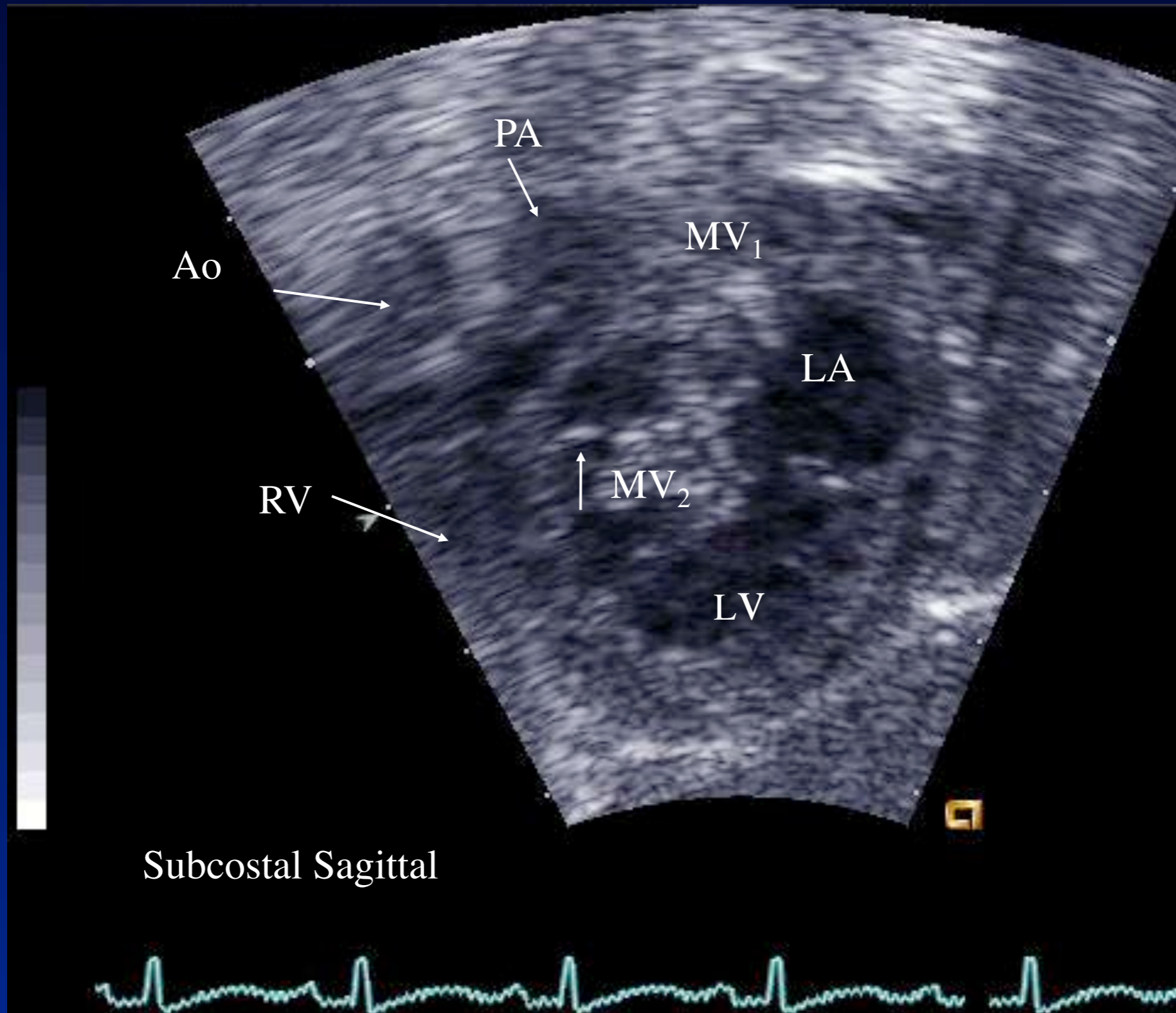
TGA: VSD's



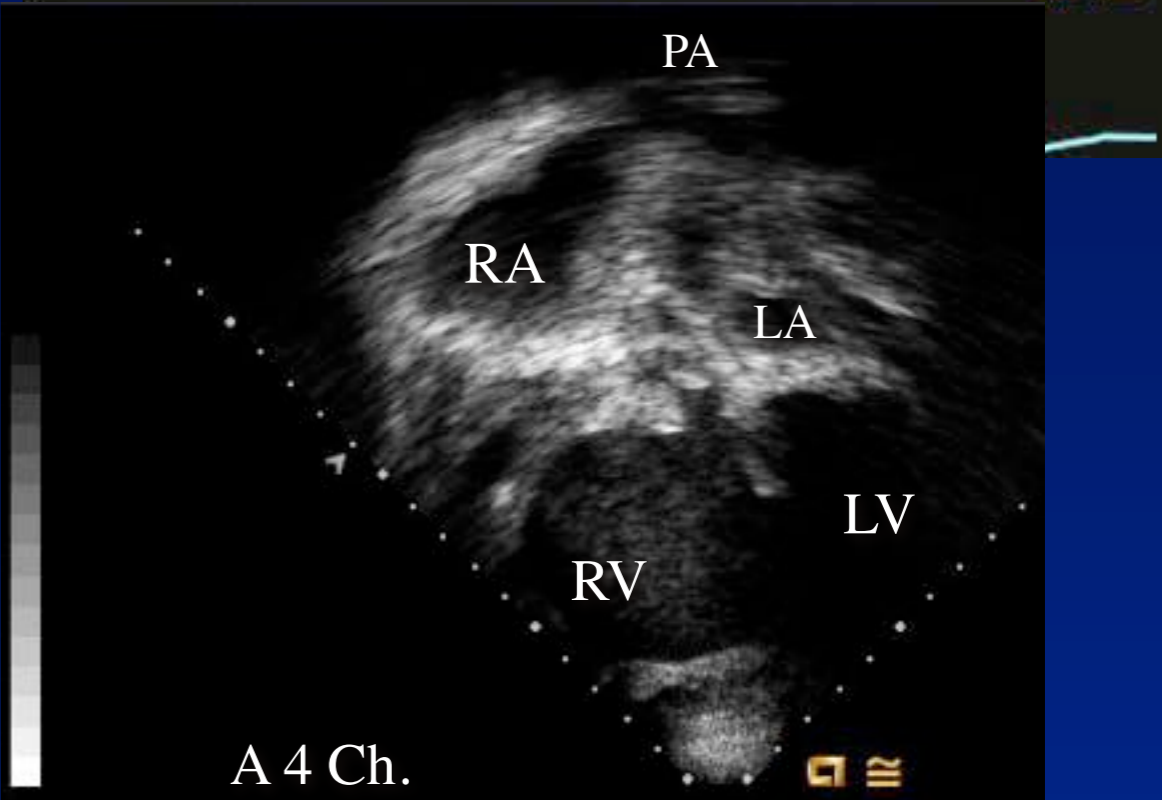
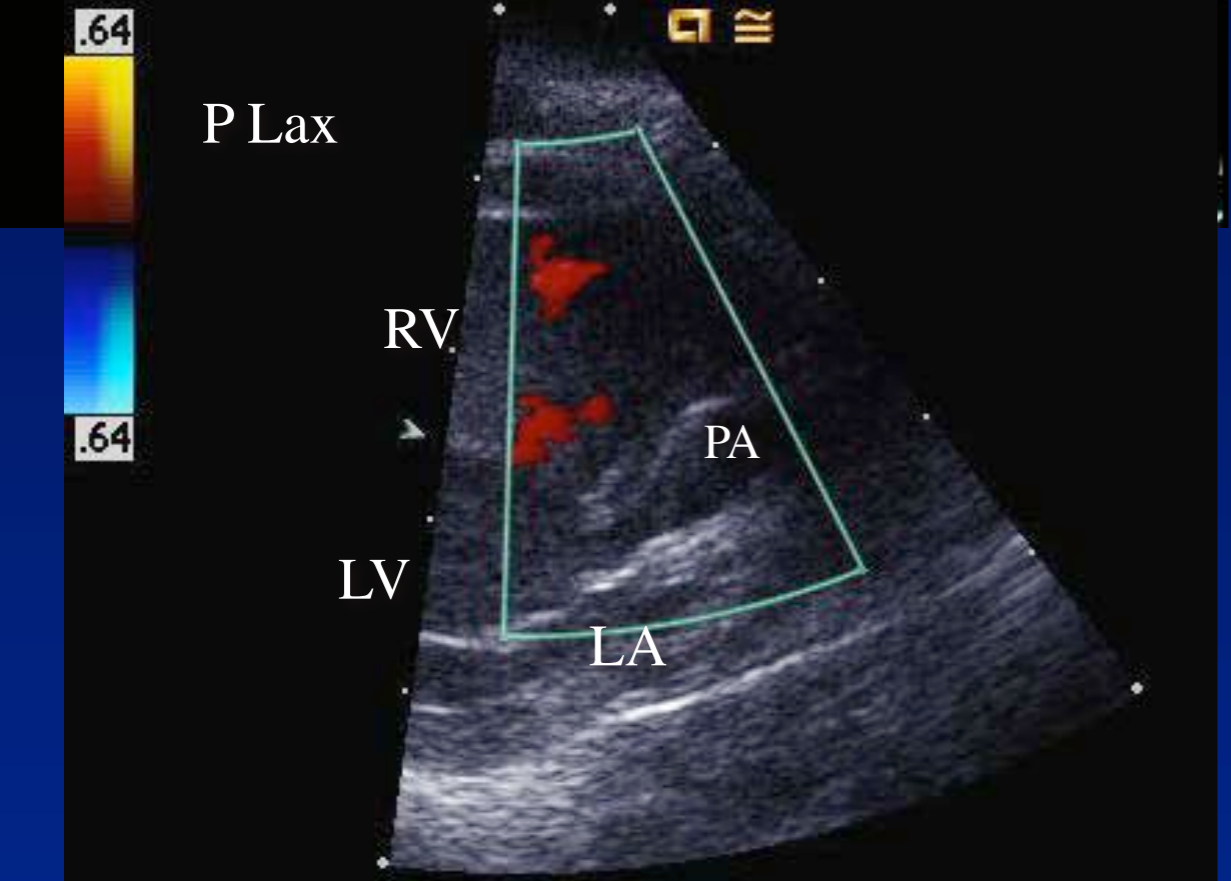
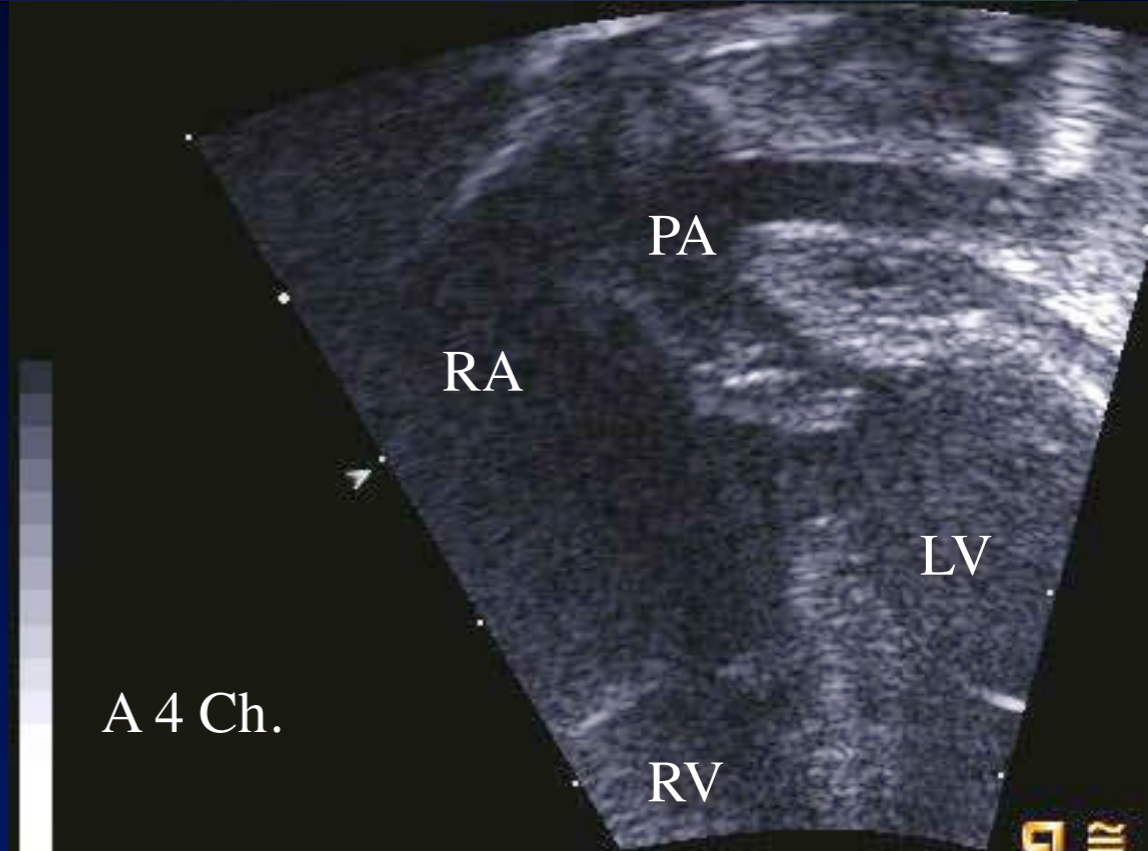
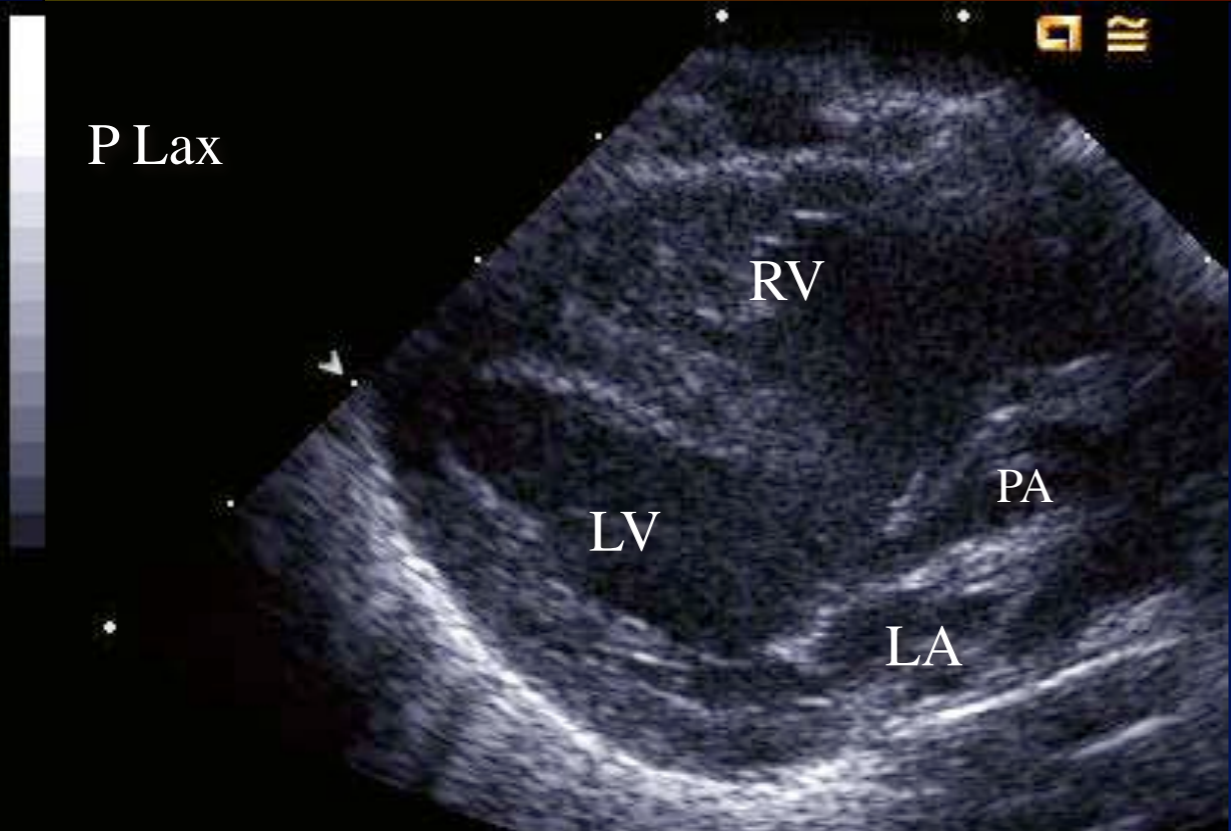
Subpulmonary Stenosis



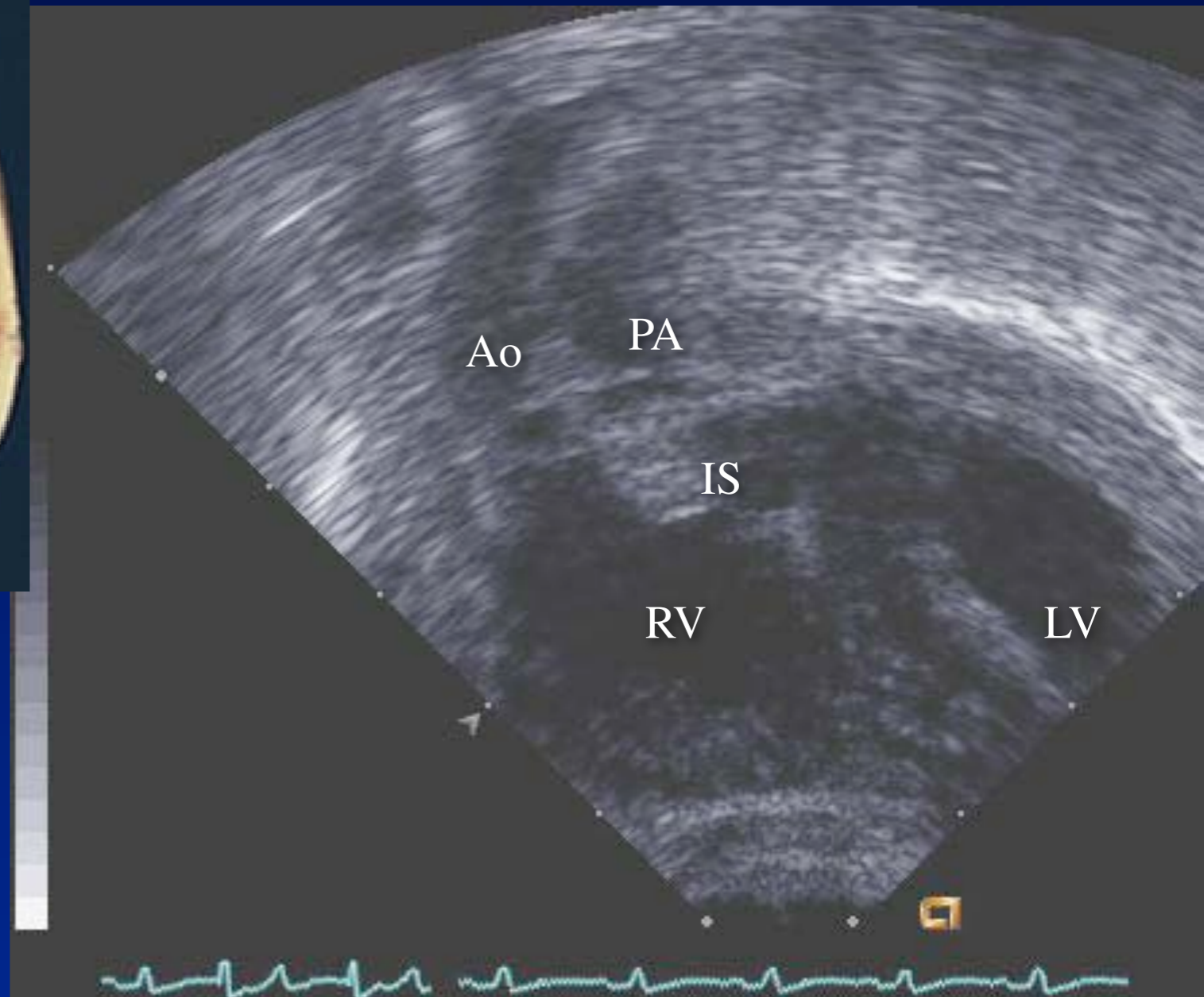
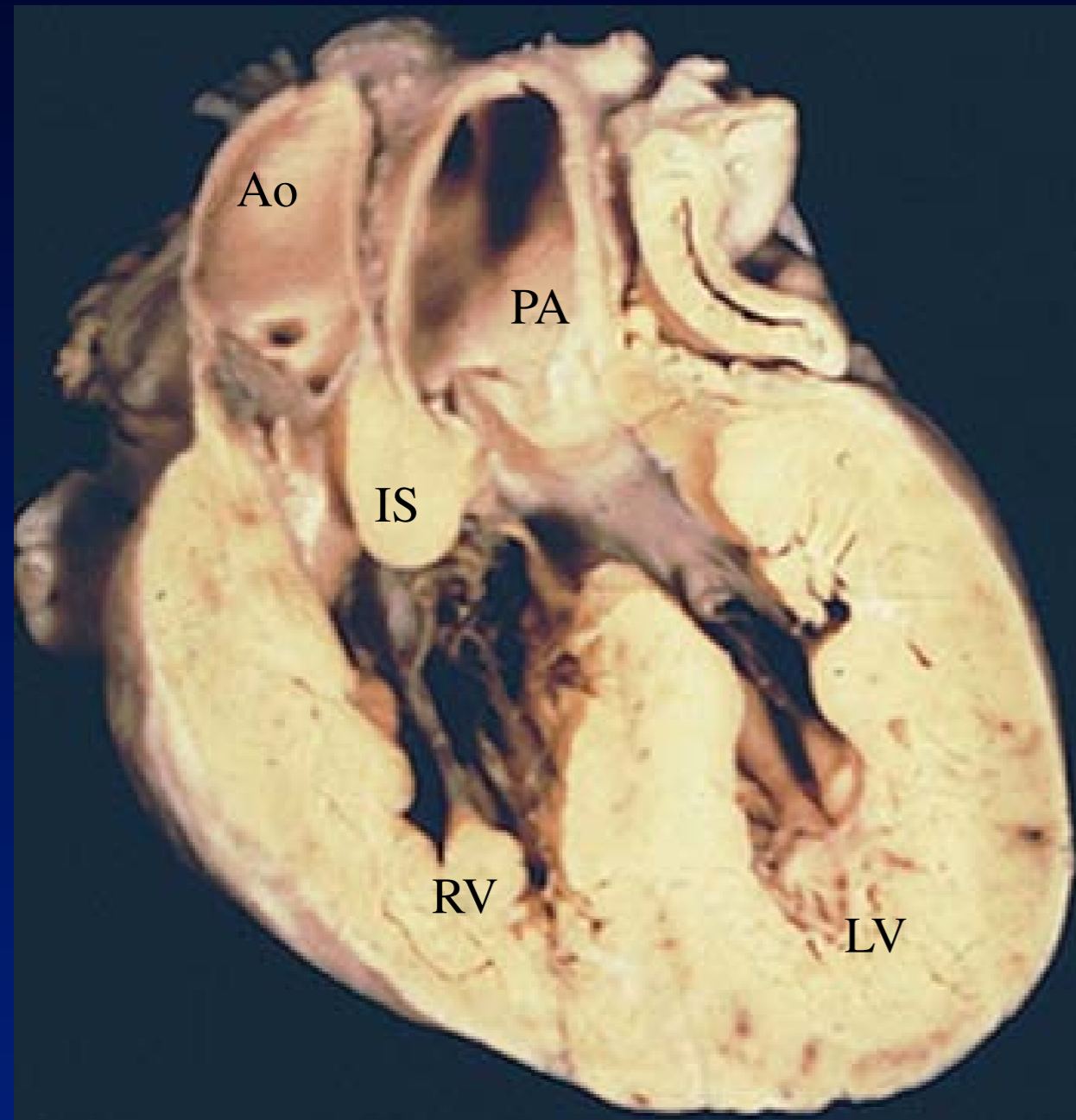
LV Outflow Obstruction due to Mitral Tissue (Double Orifice MV)



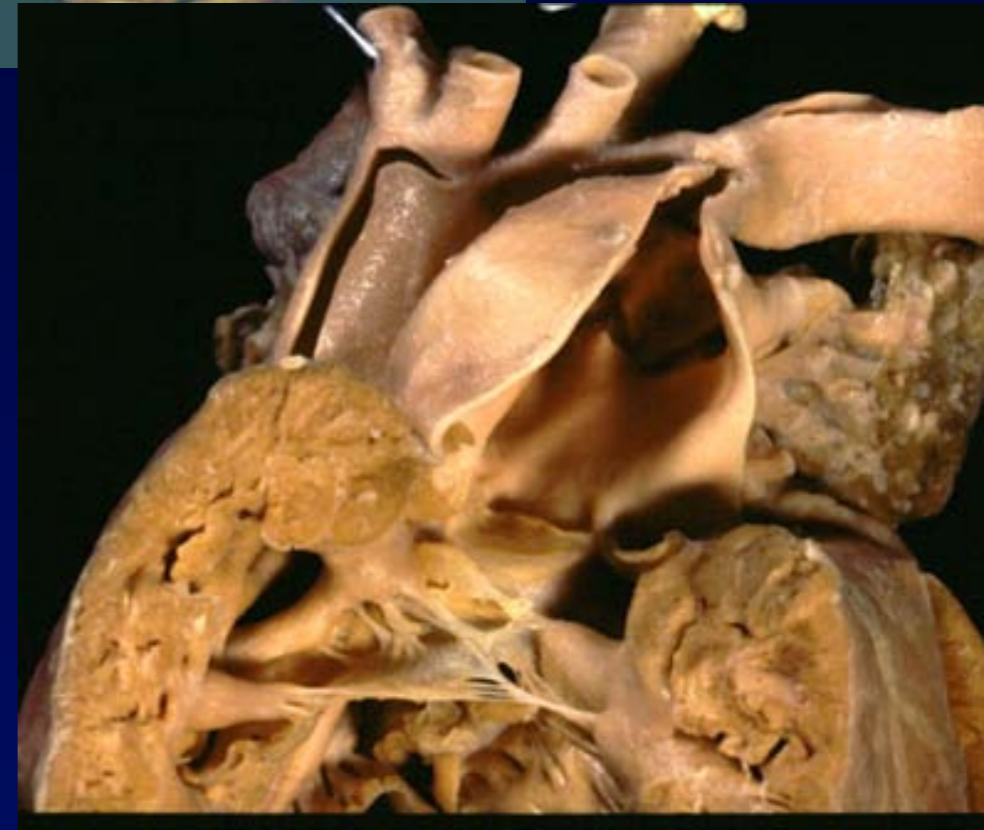
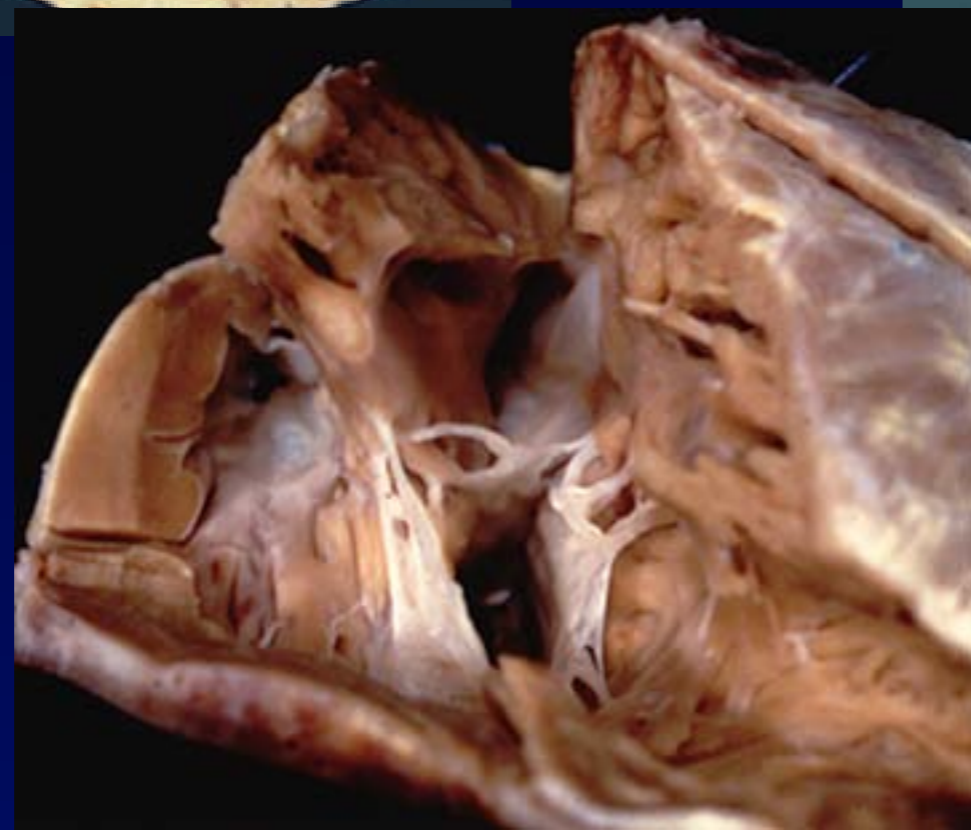
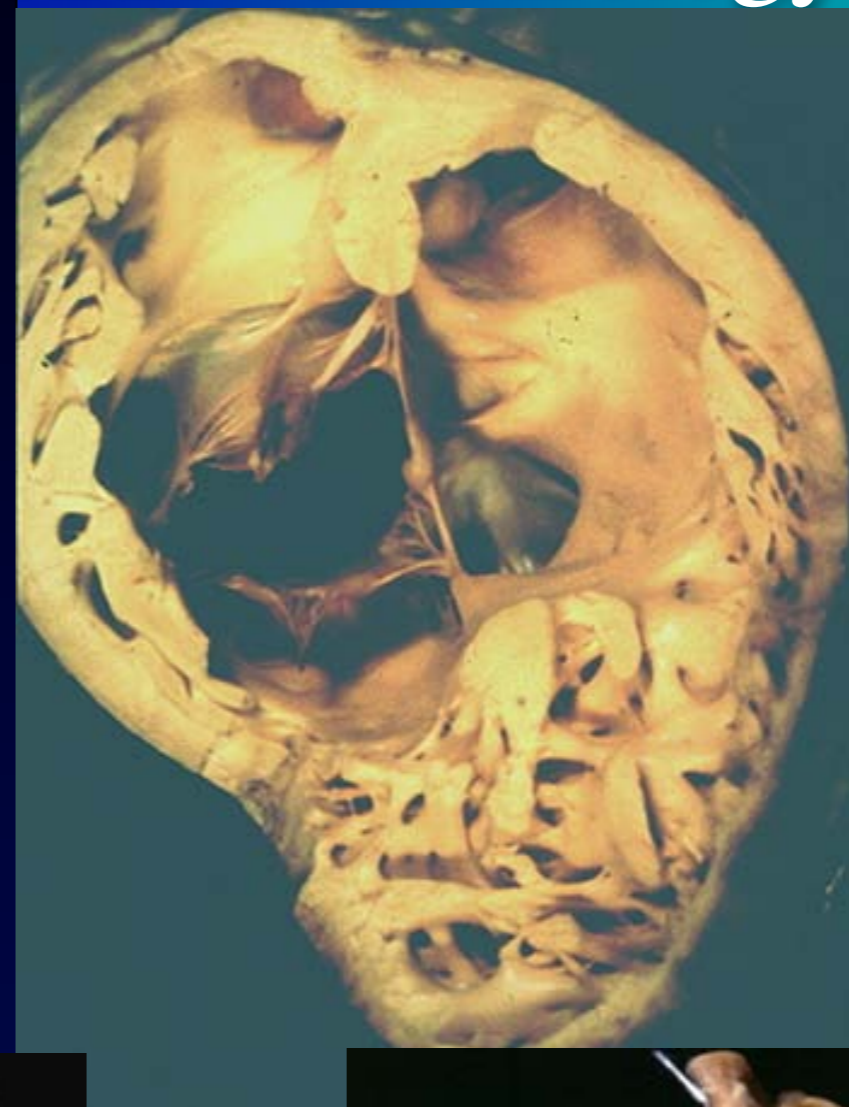
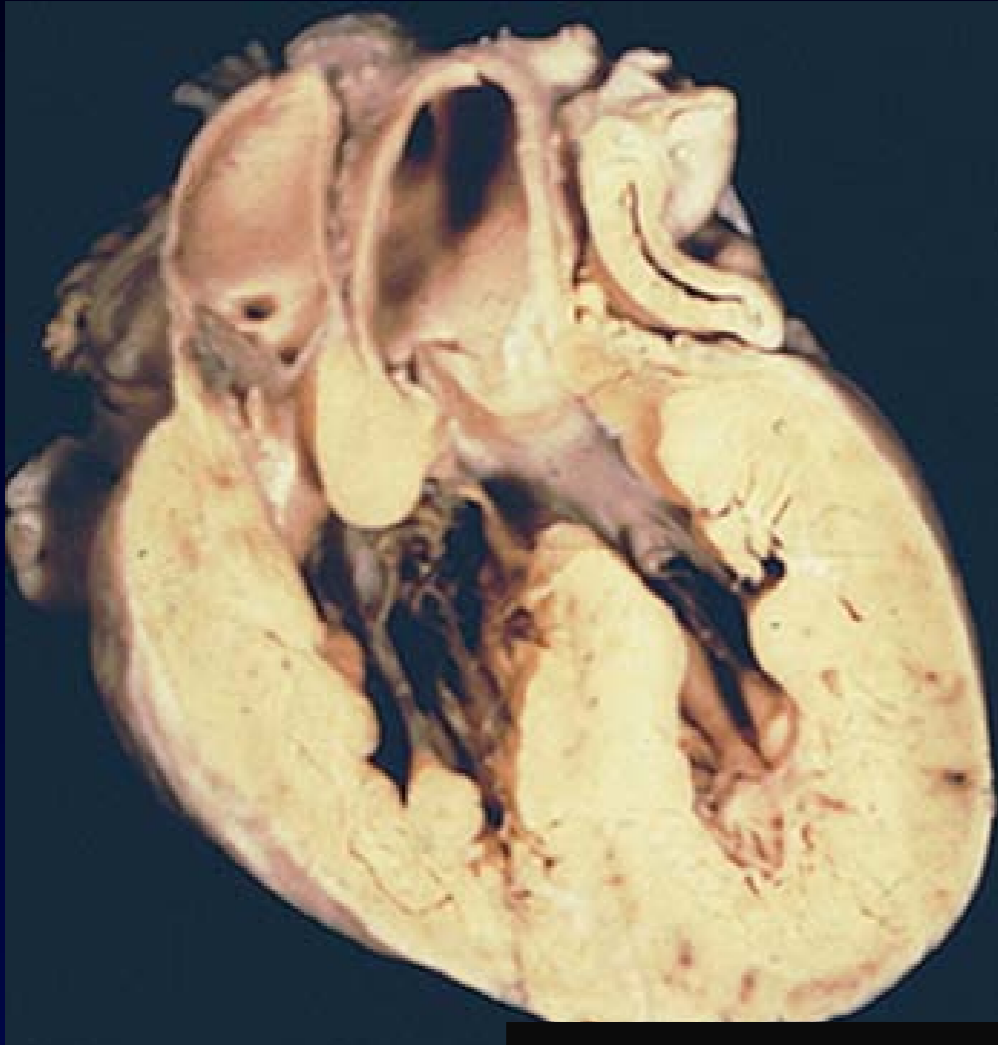Subpulmonary and Valvar Pulmonary Stenosis



Malalignment Ventricular Septal Defect



Double outlet Right Ventricle Pathology



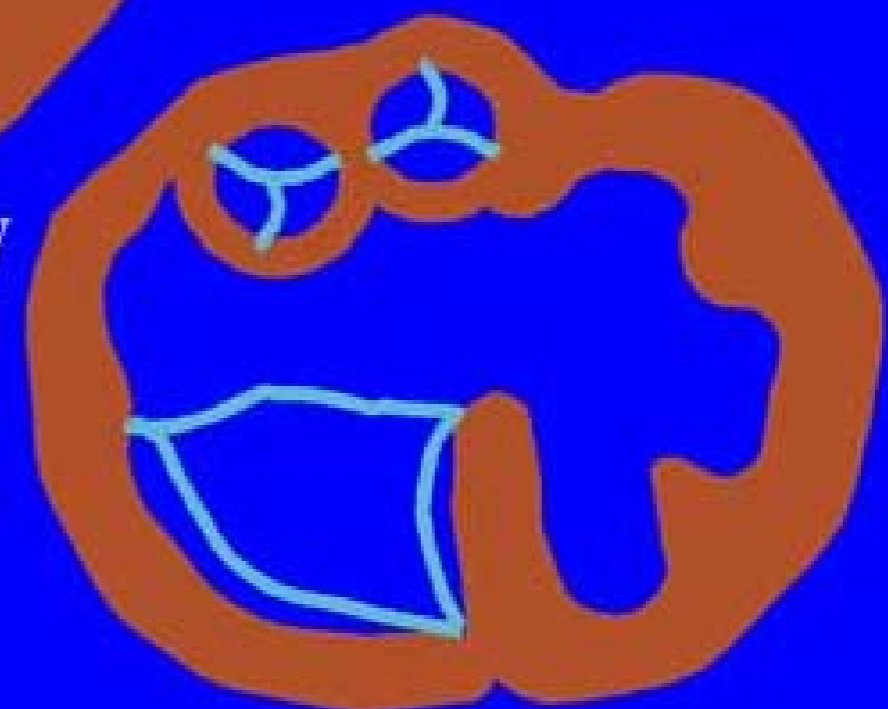Ventricular Septal Defect in Double Outlet Right Ventricle



Subaortic



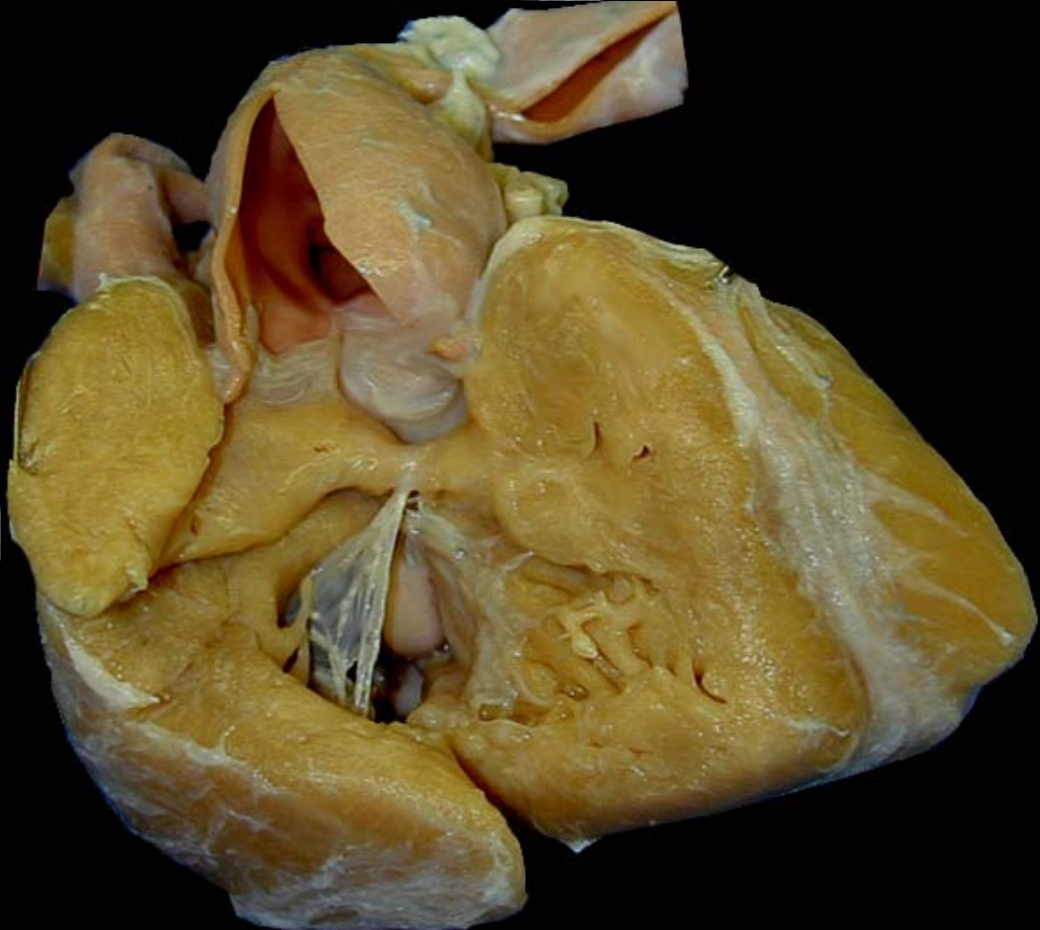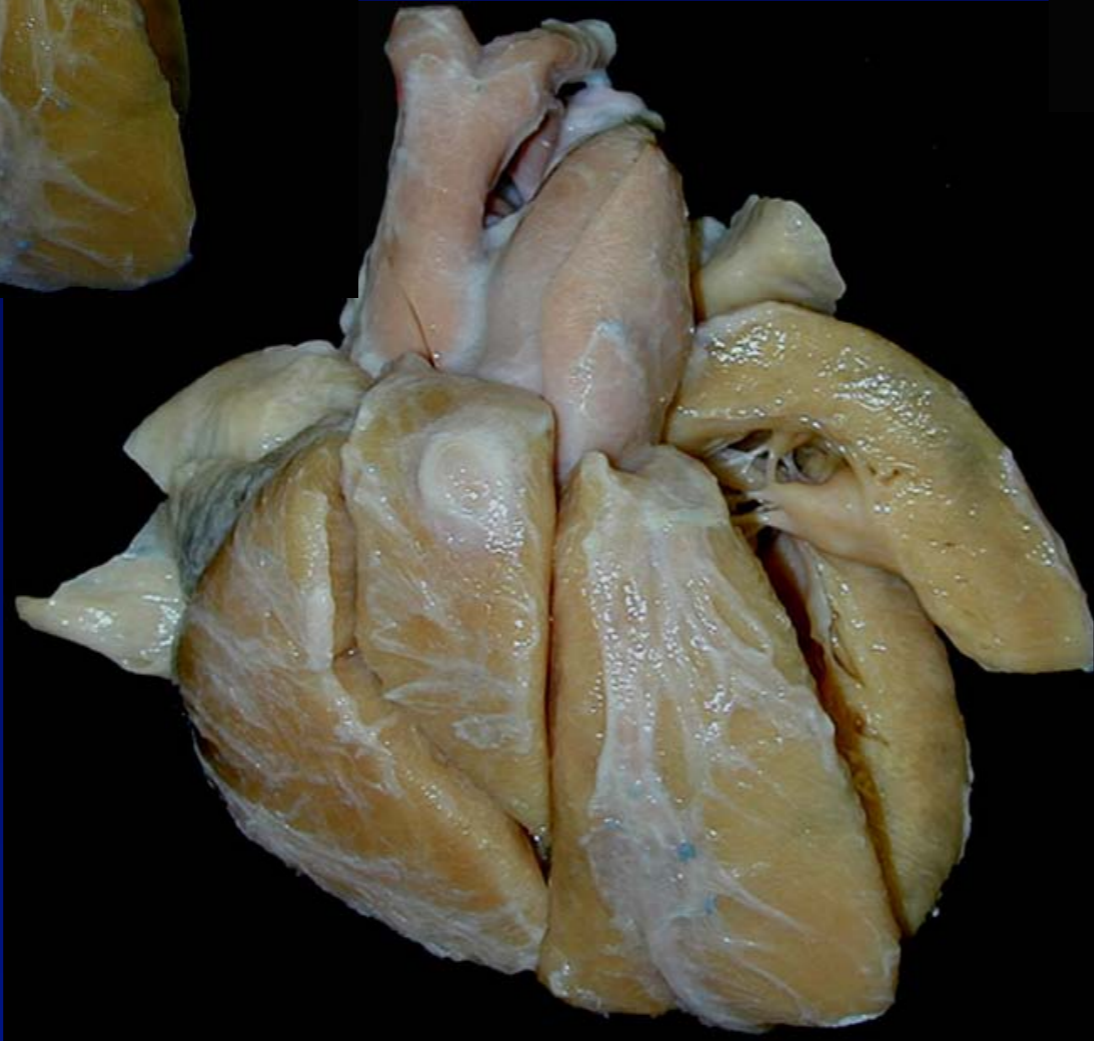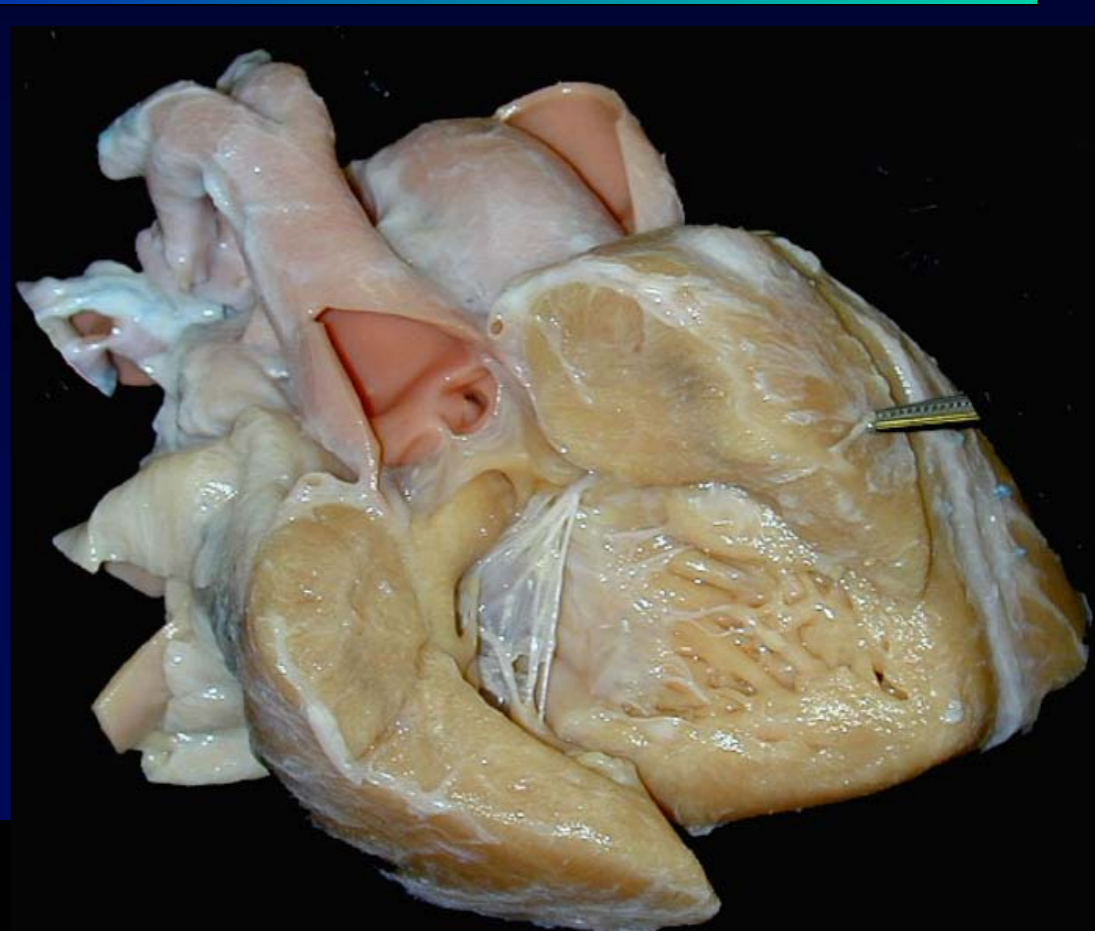
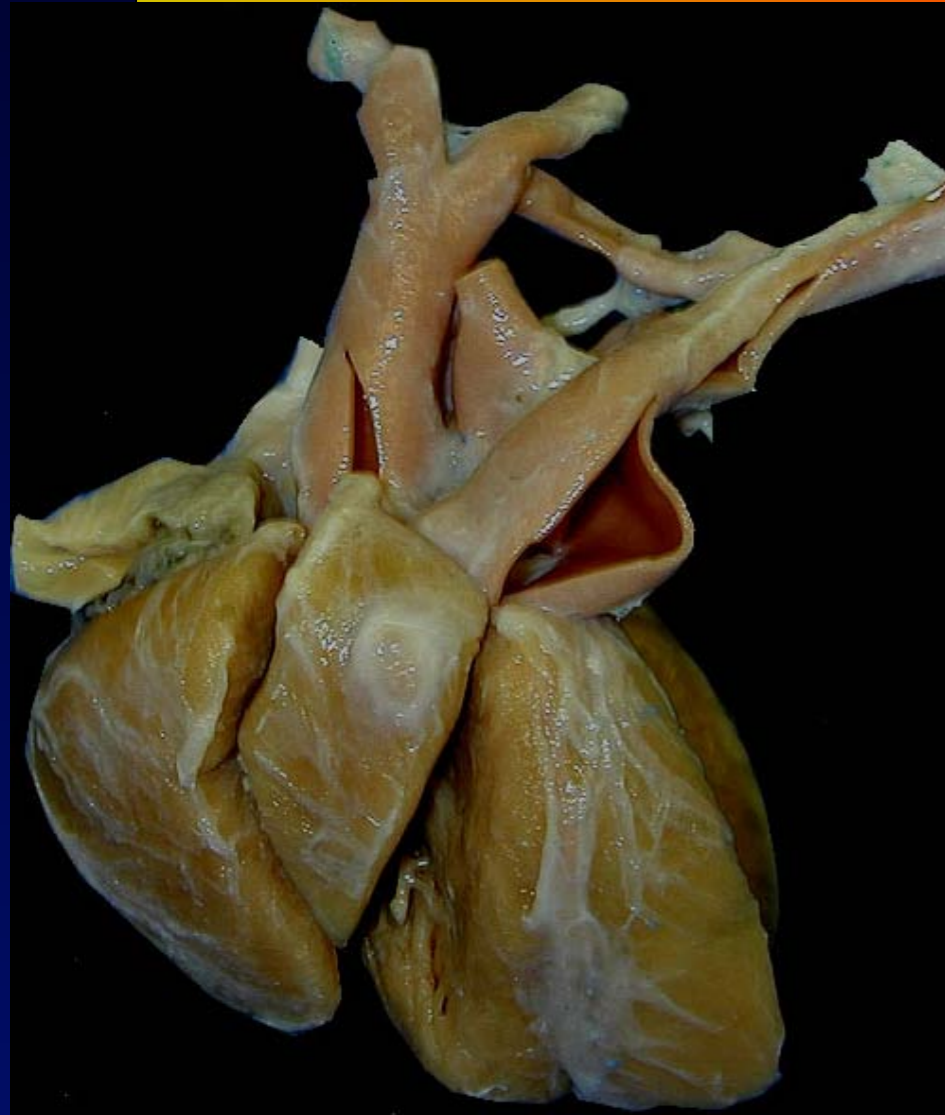Subpulmonary



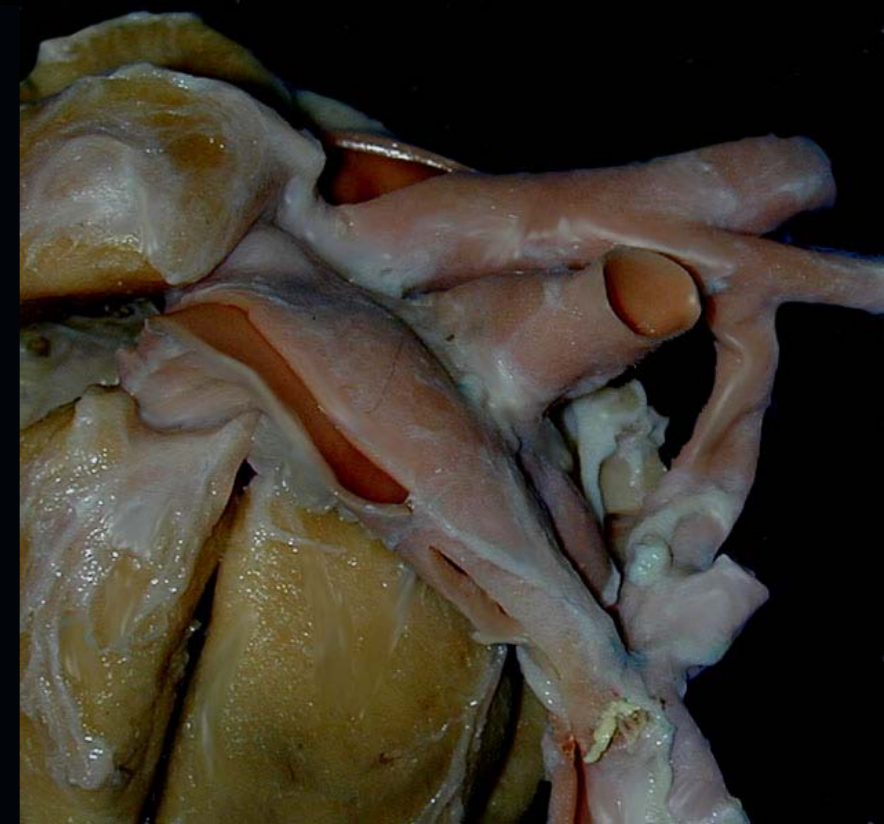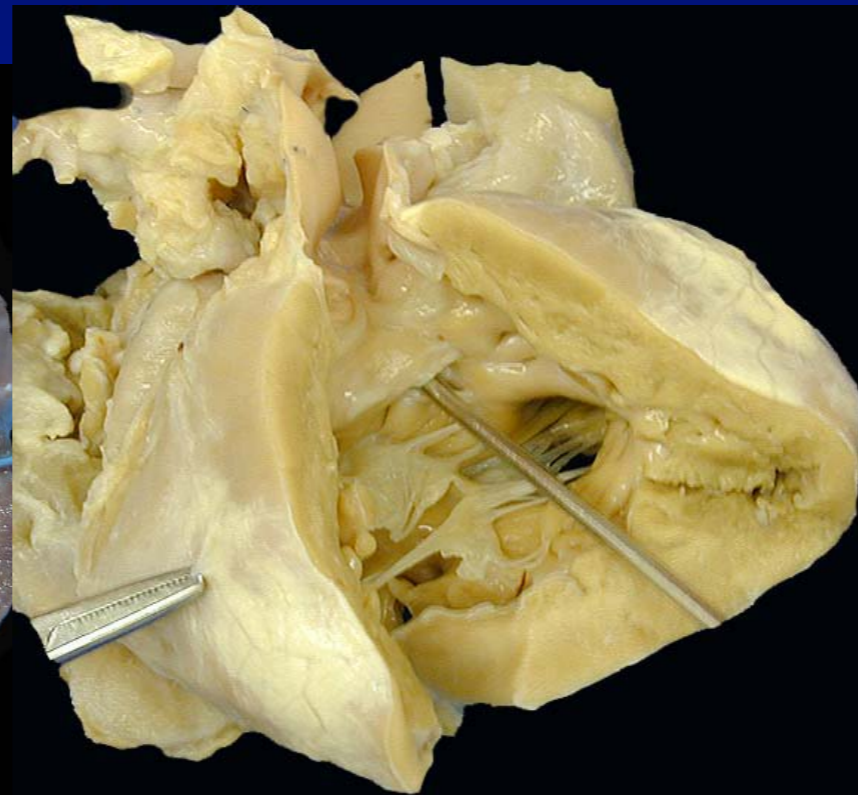
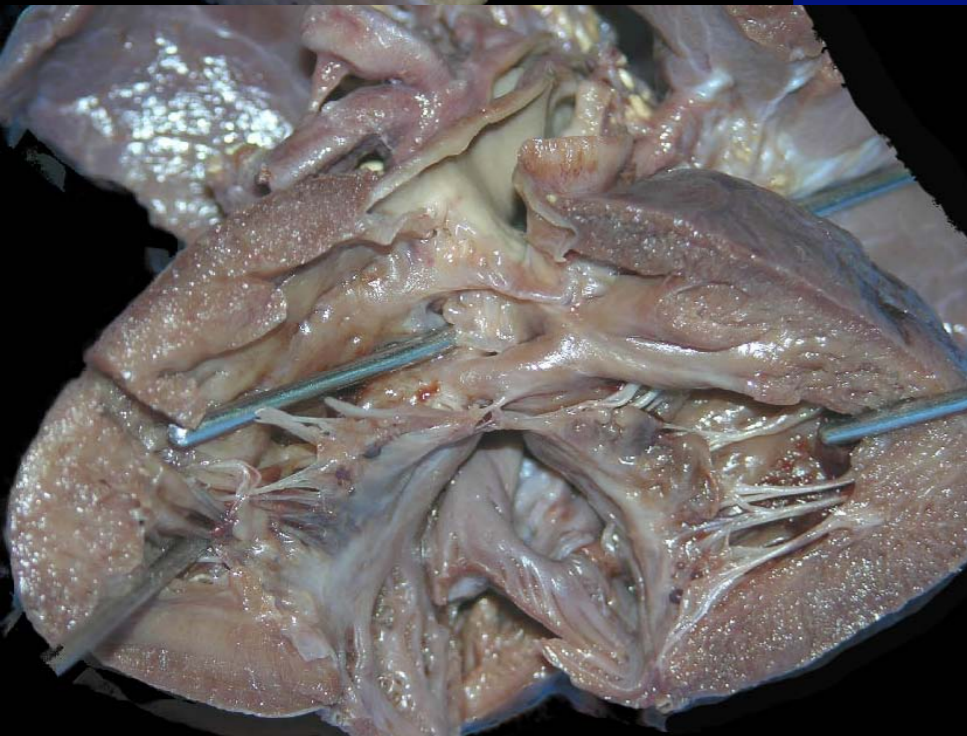
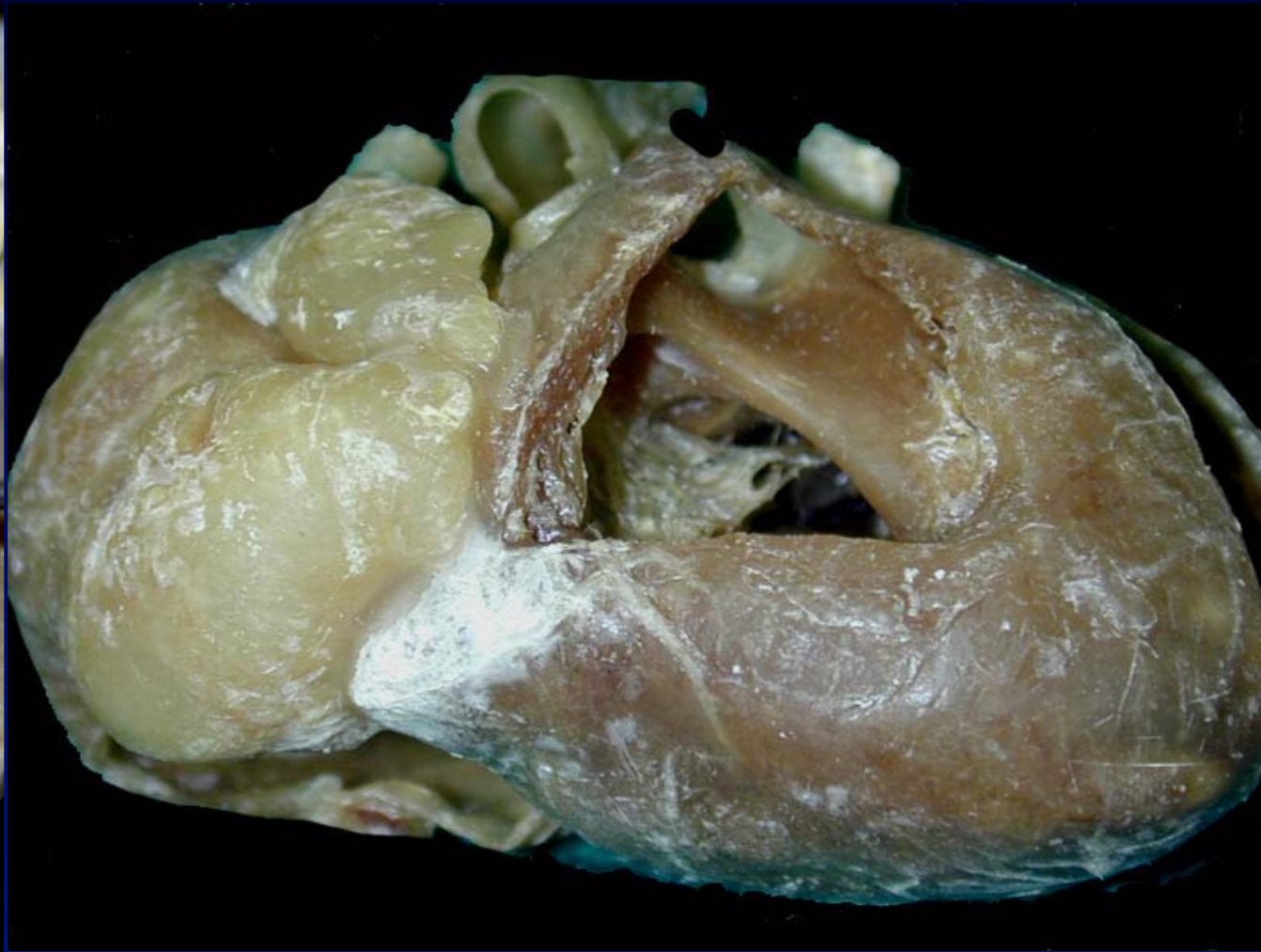
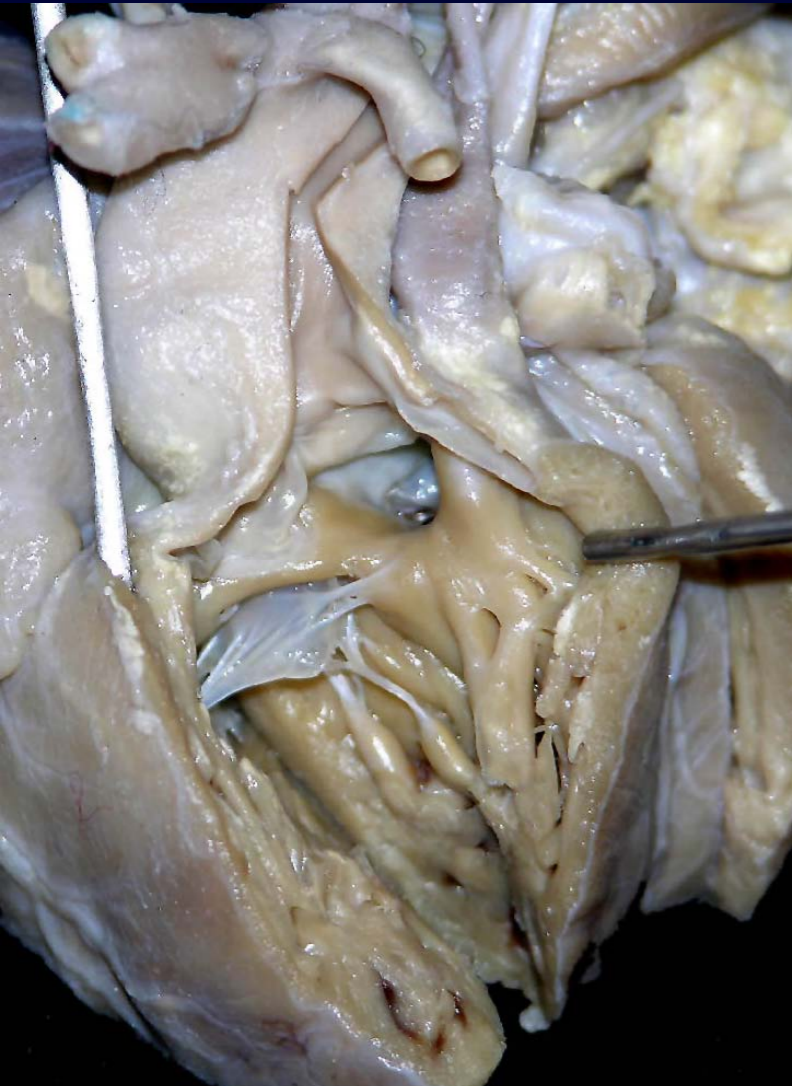
**Doubly
Committed**

Courtesy of Dr Stephen Sanders

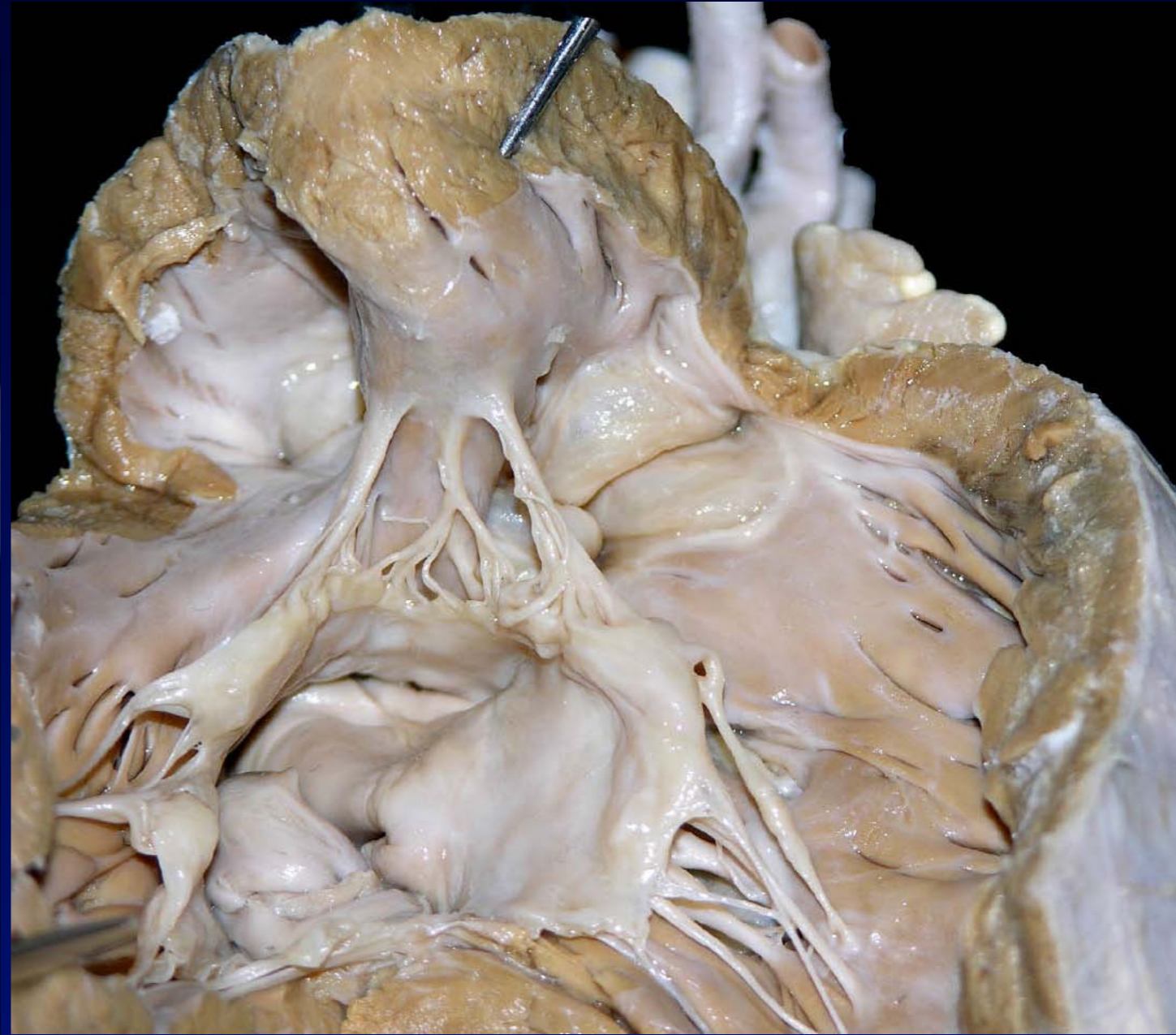
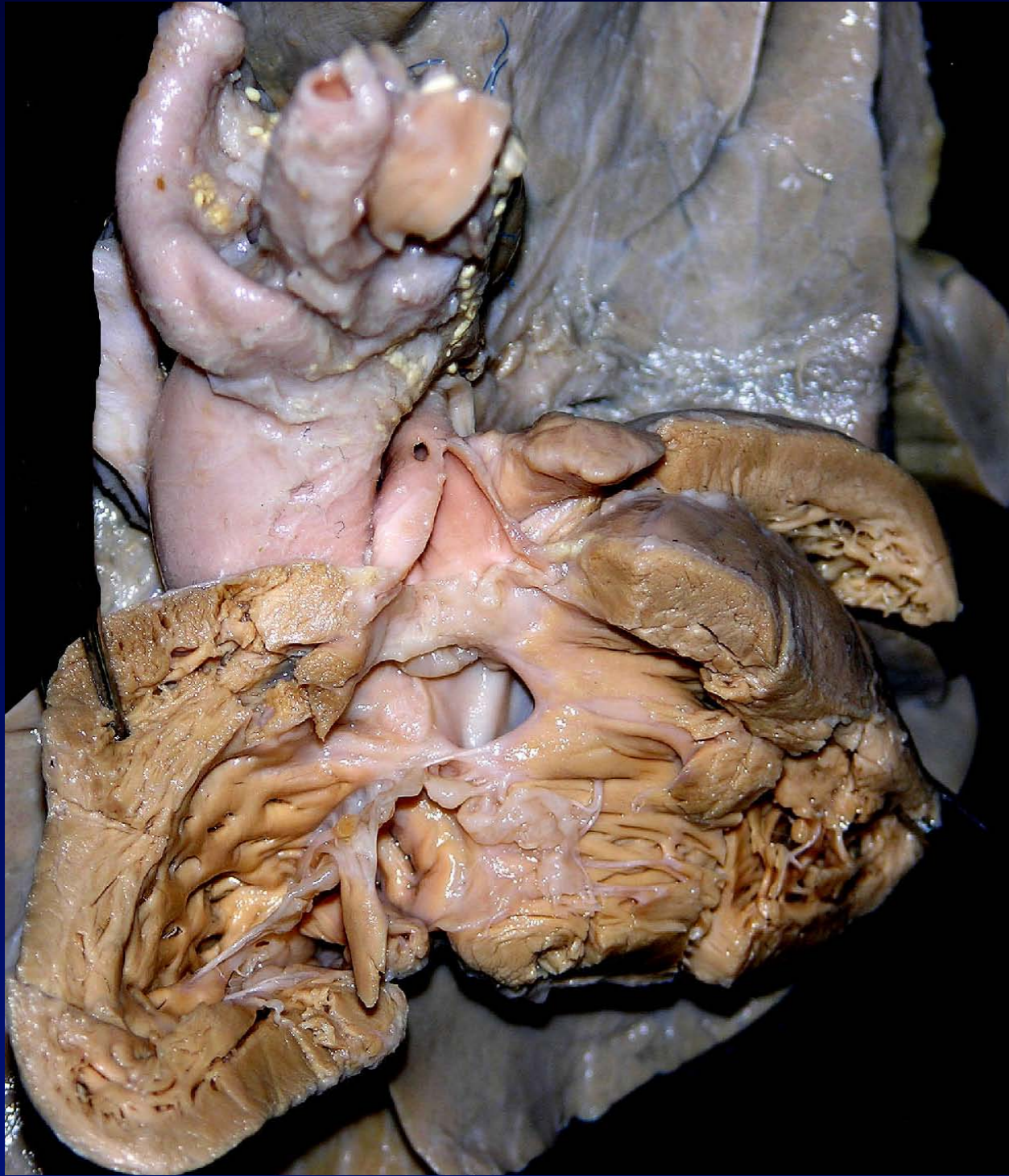
Double outlet Right Ventricle Pathology



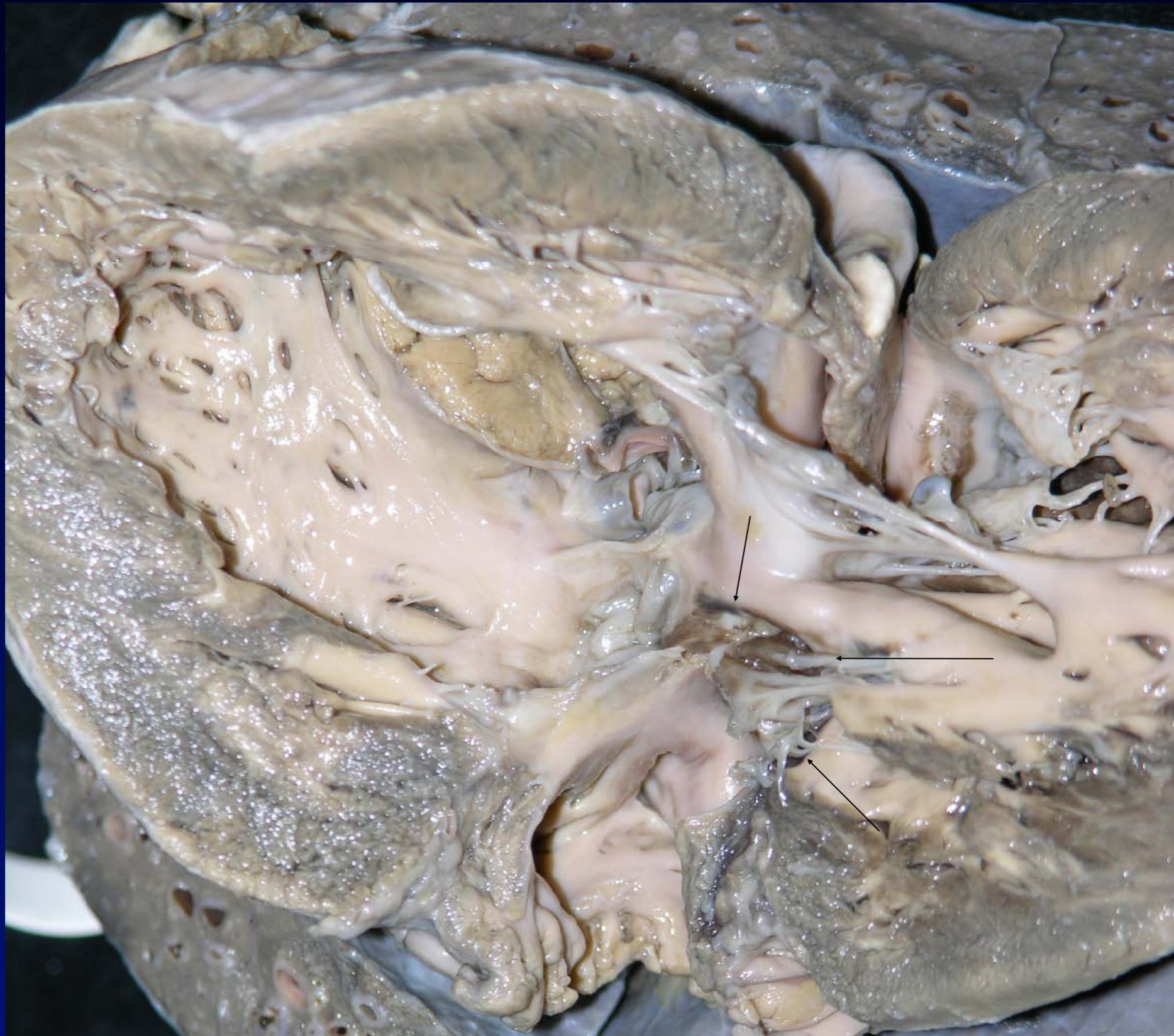
More Pathology



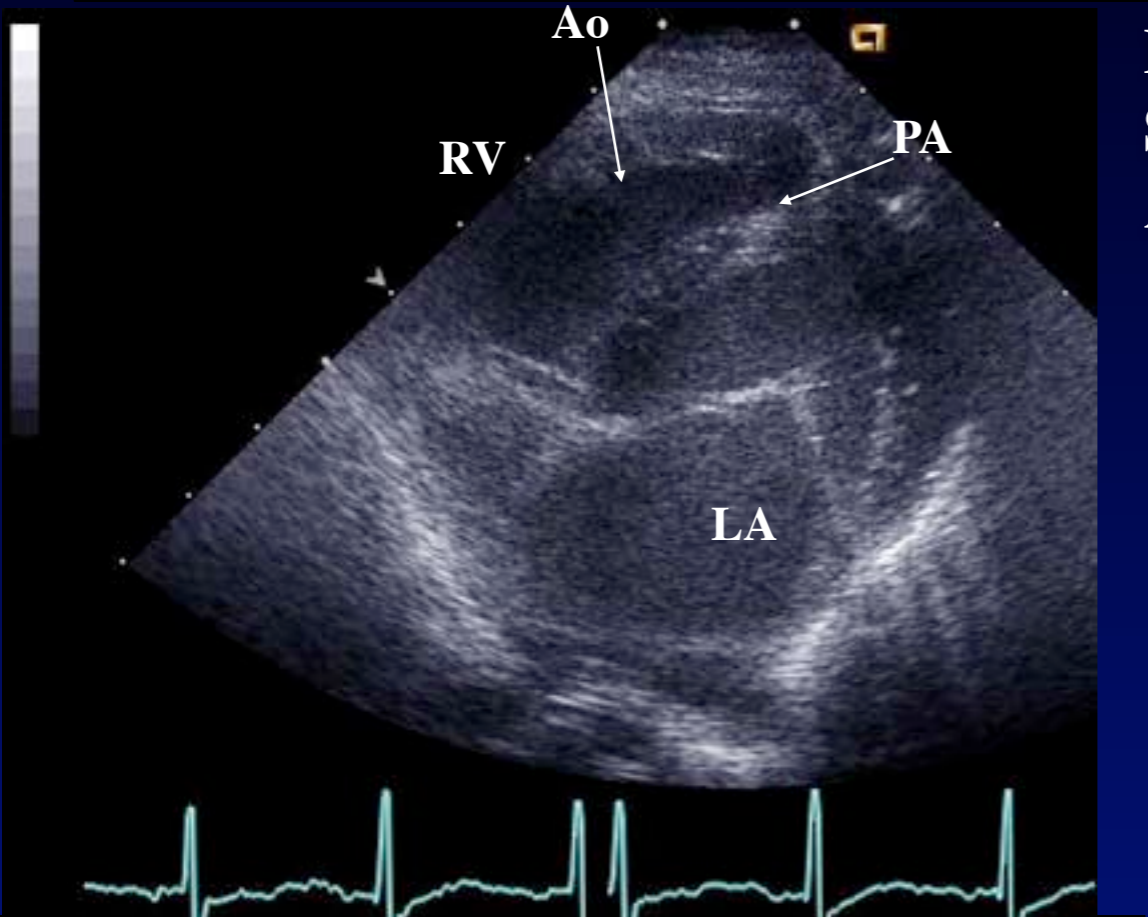
Doubly Committed DORV



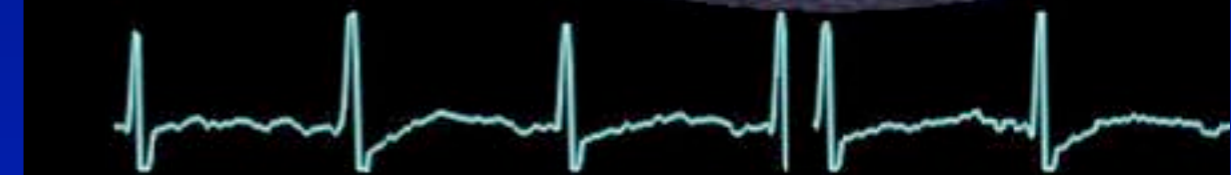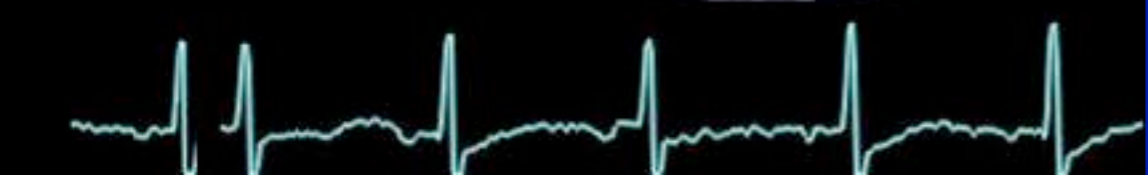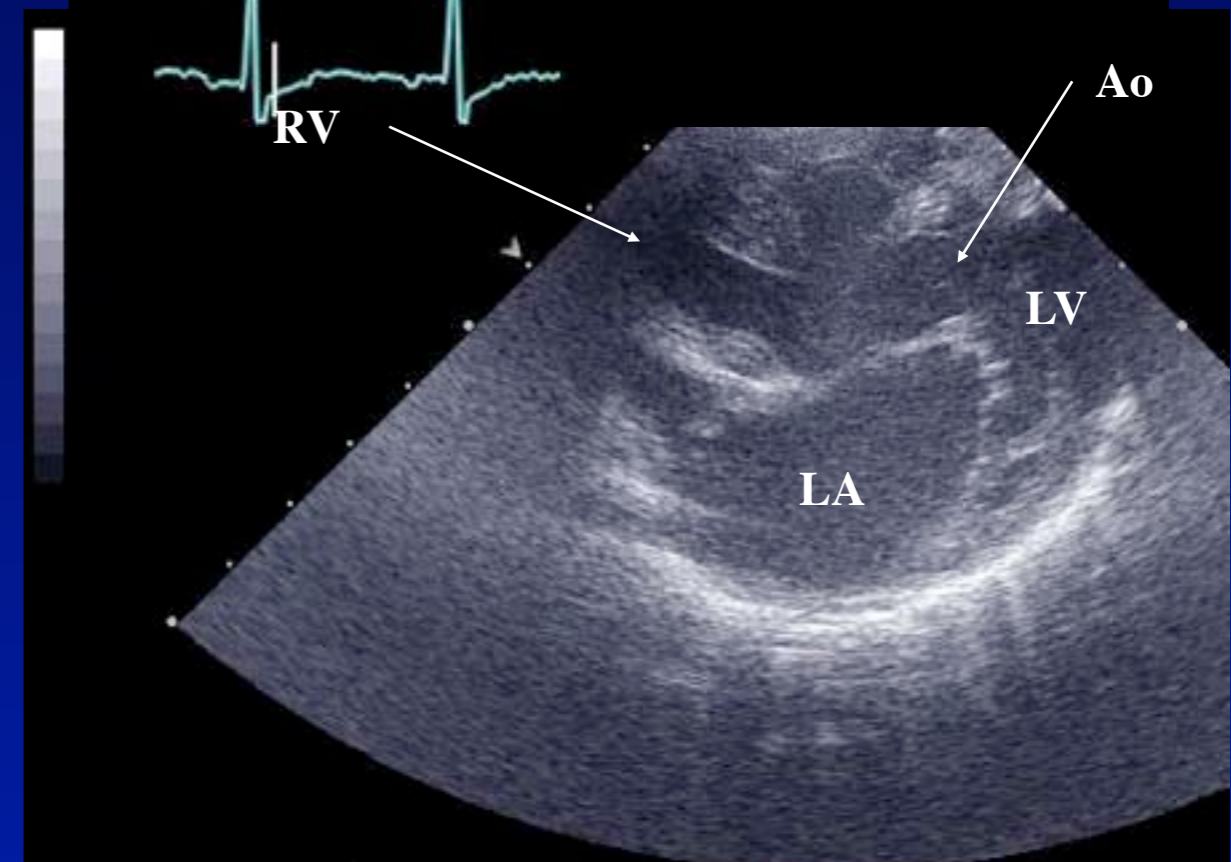
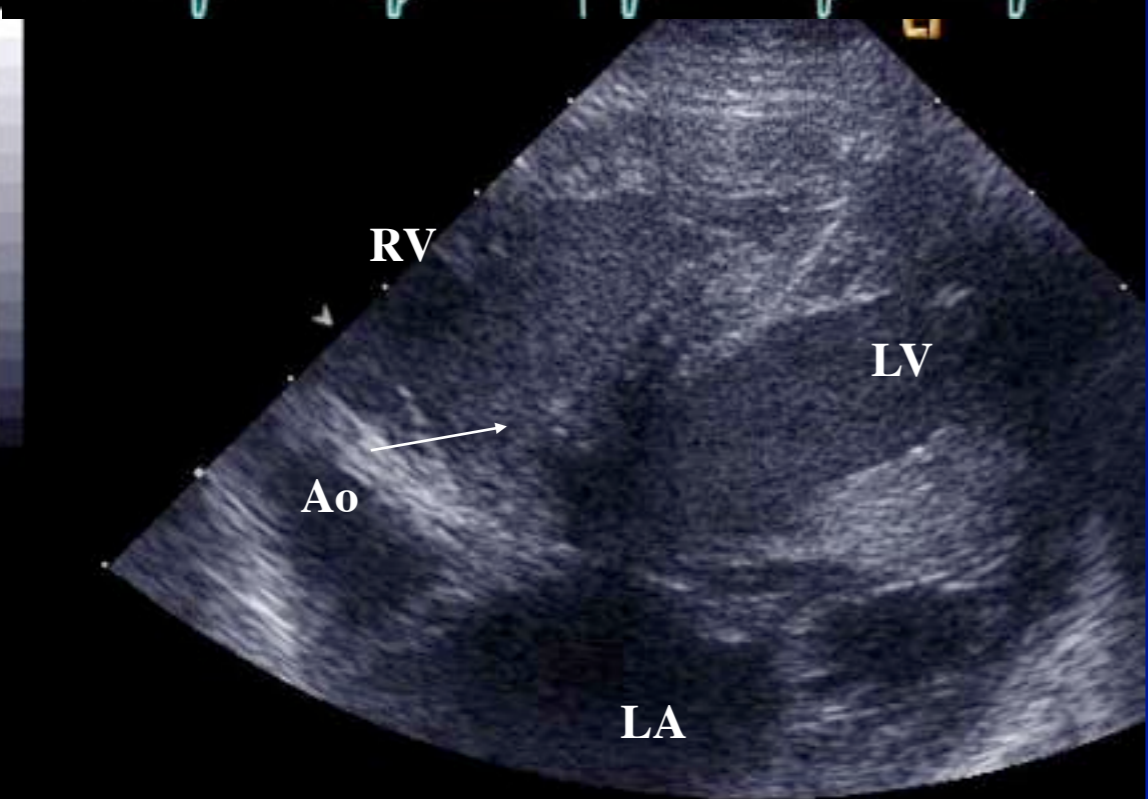
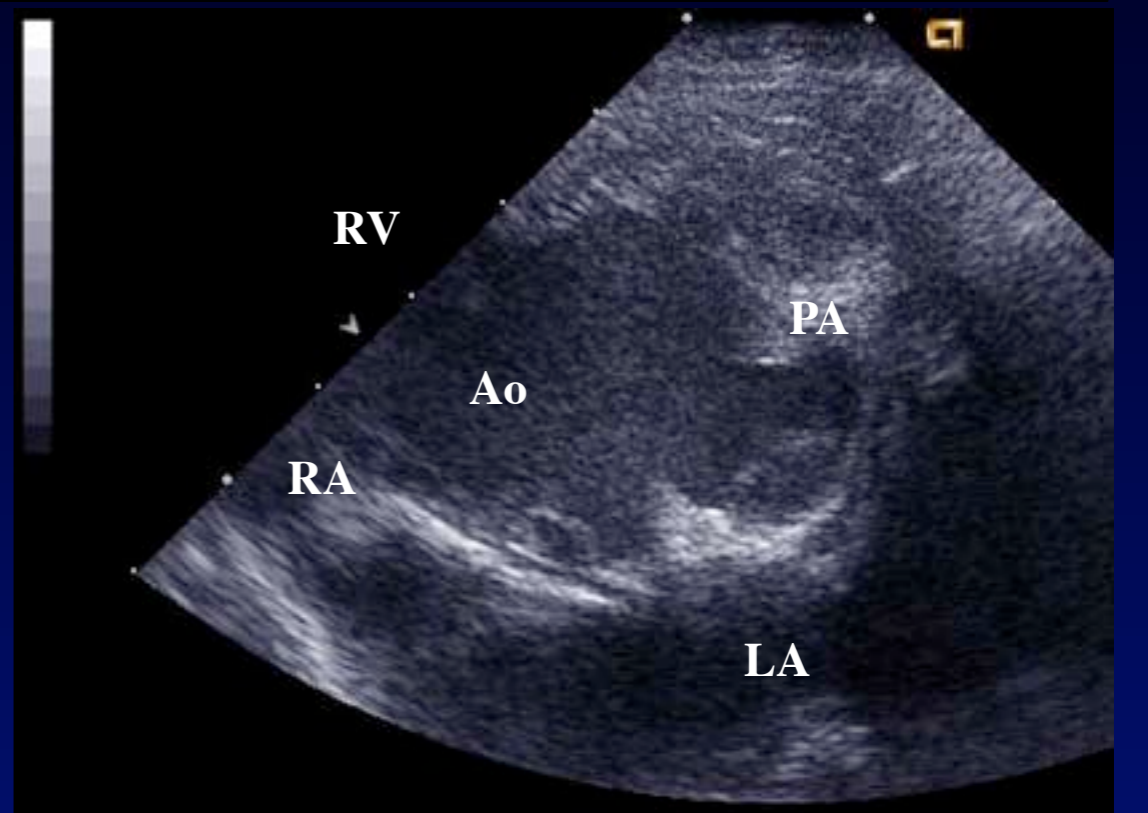
Non Committed VSD



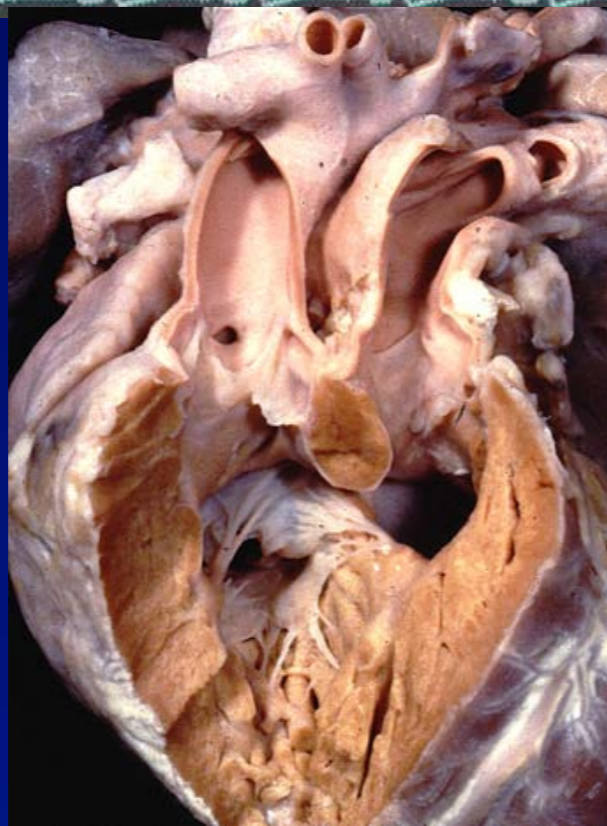
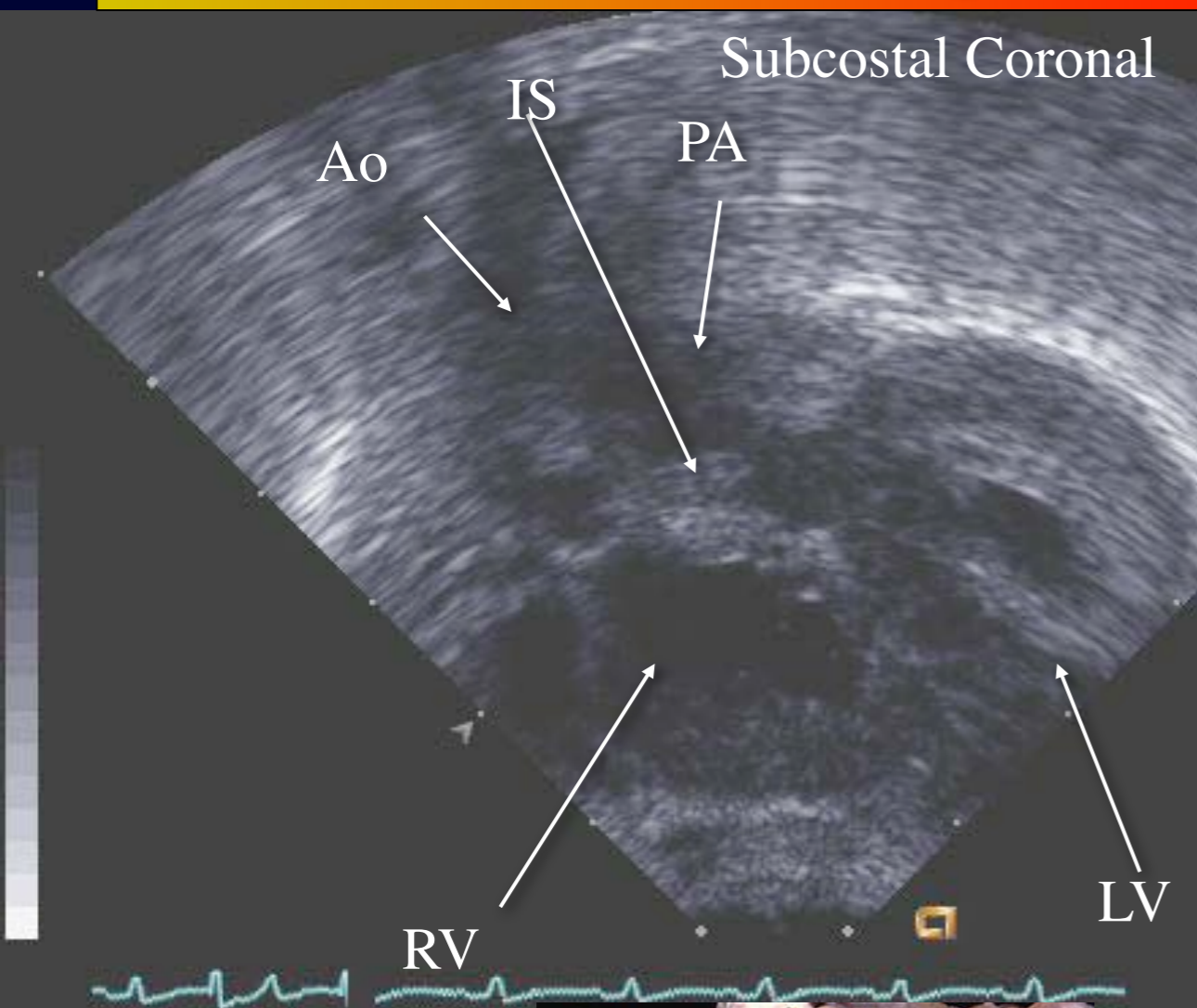
Sub-aortic DORV



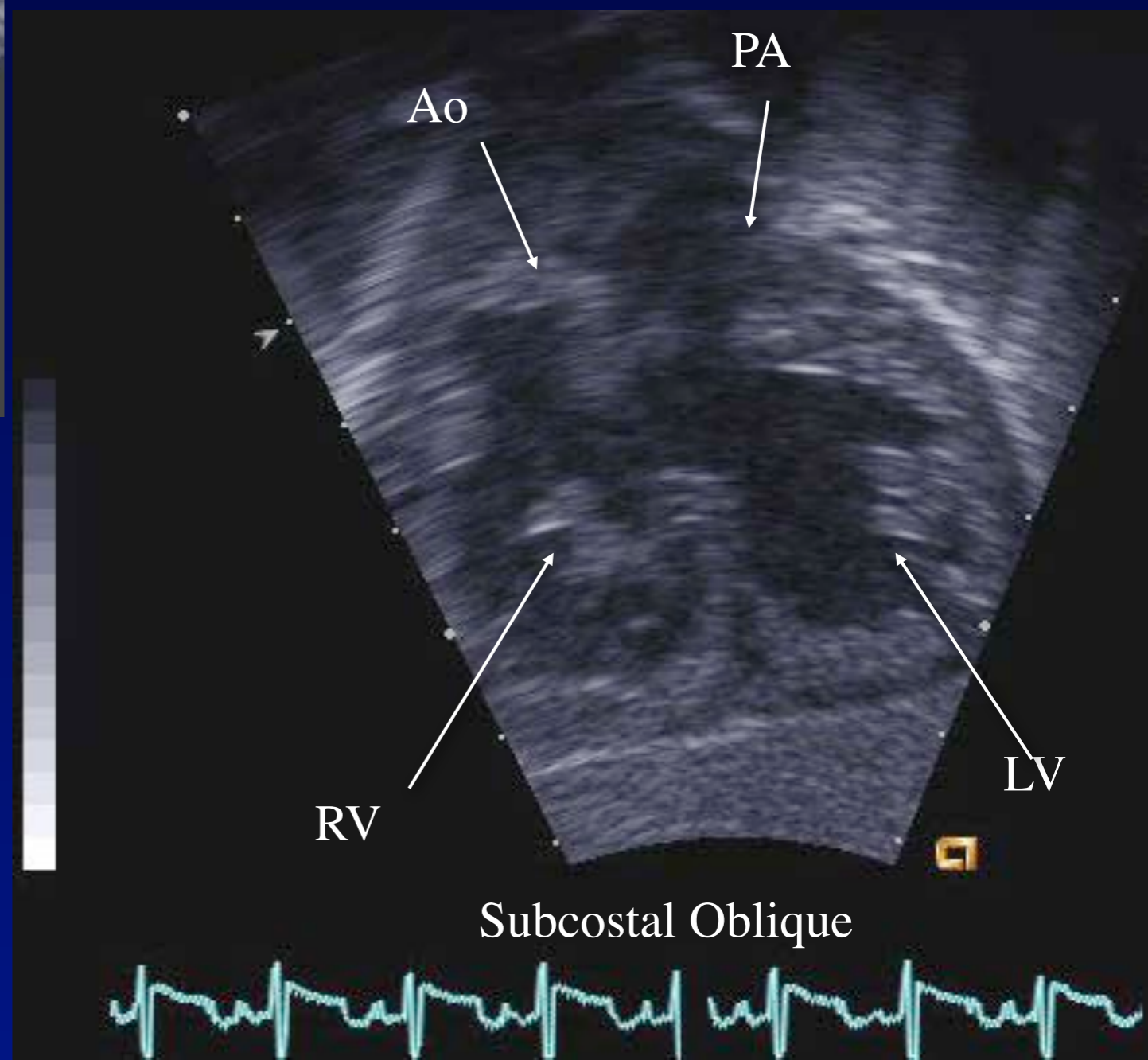
Parast.
Short
Axis



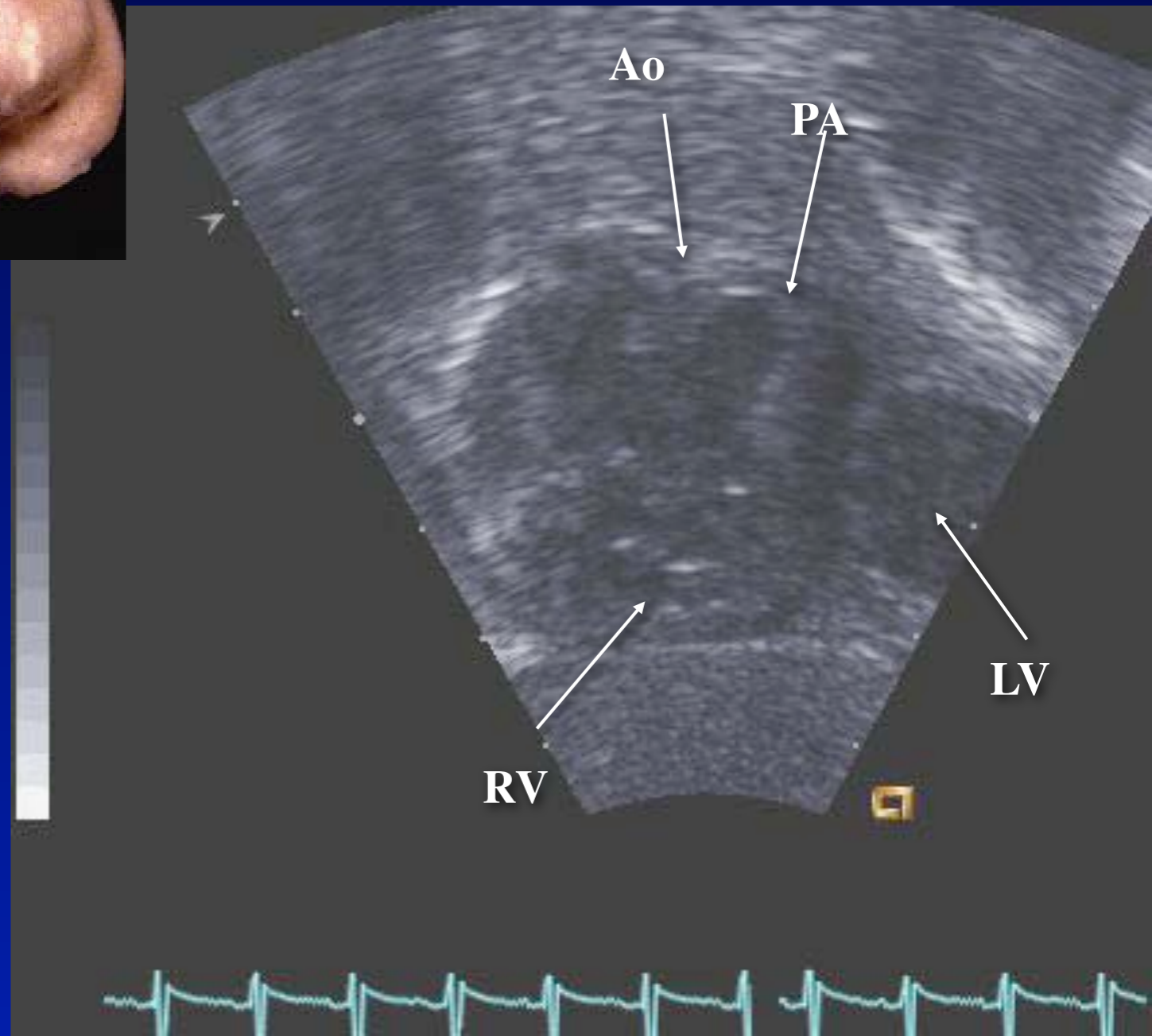
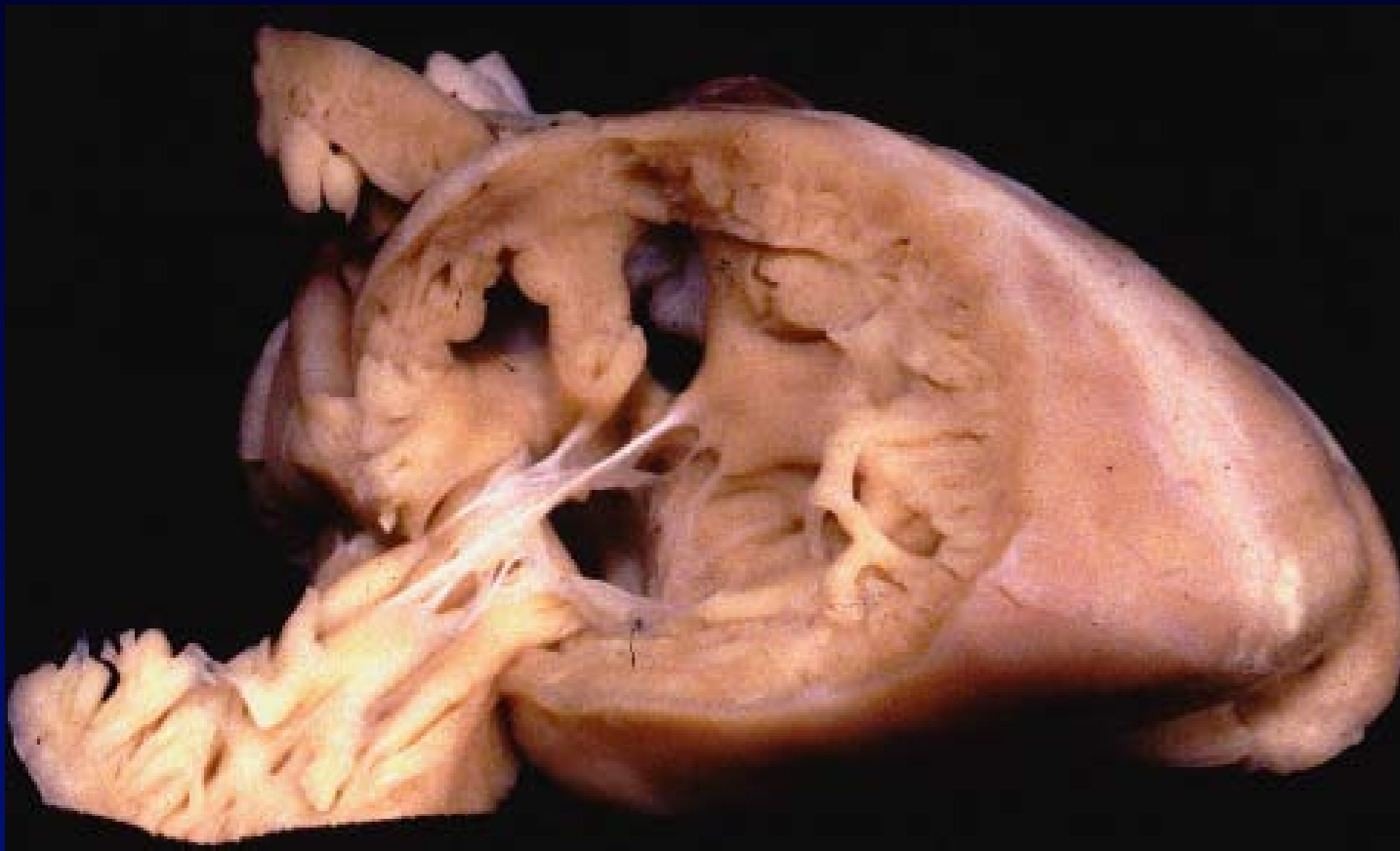
Double Outlet Right Ventricle: Echocardiography



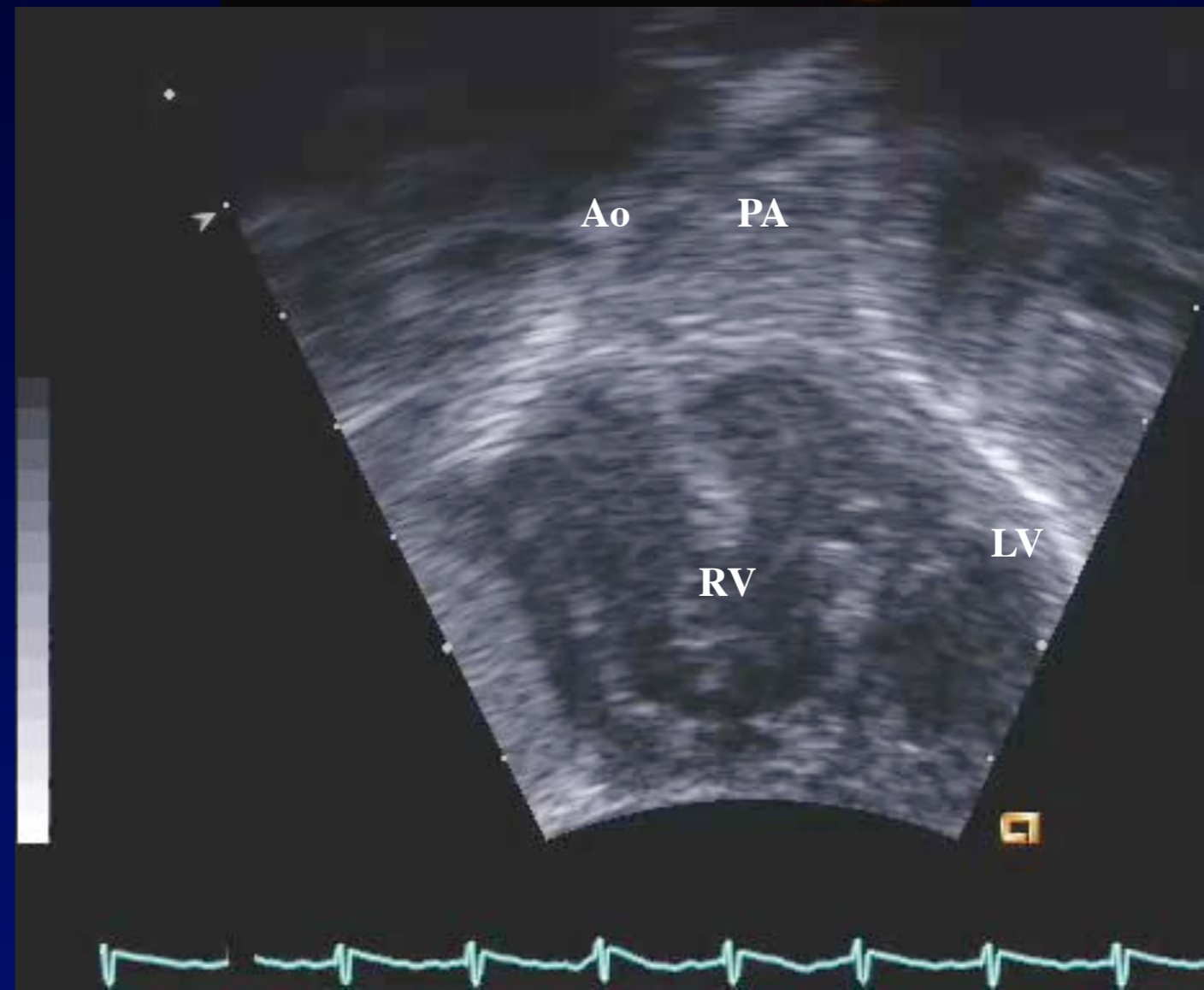
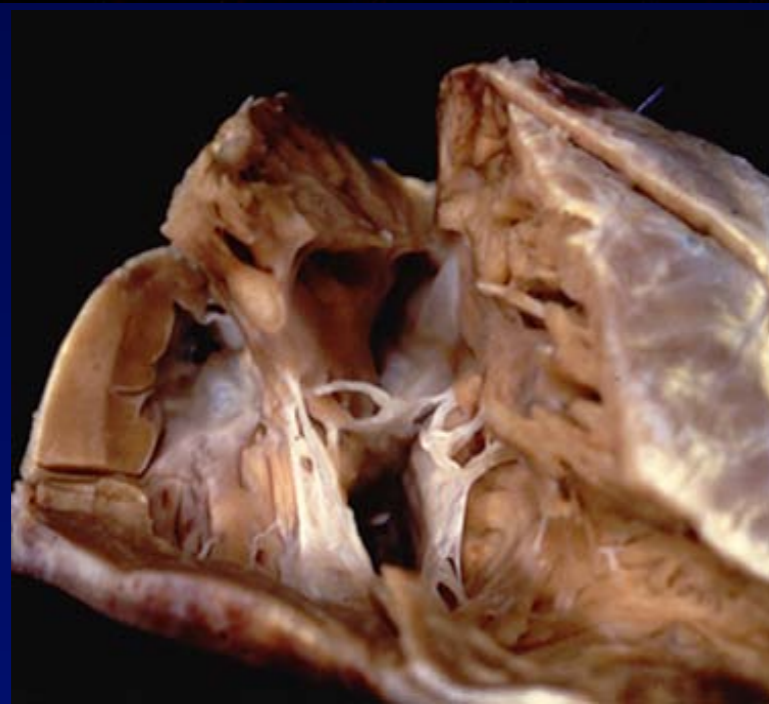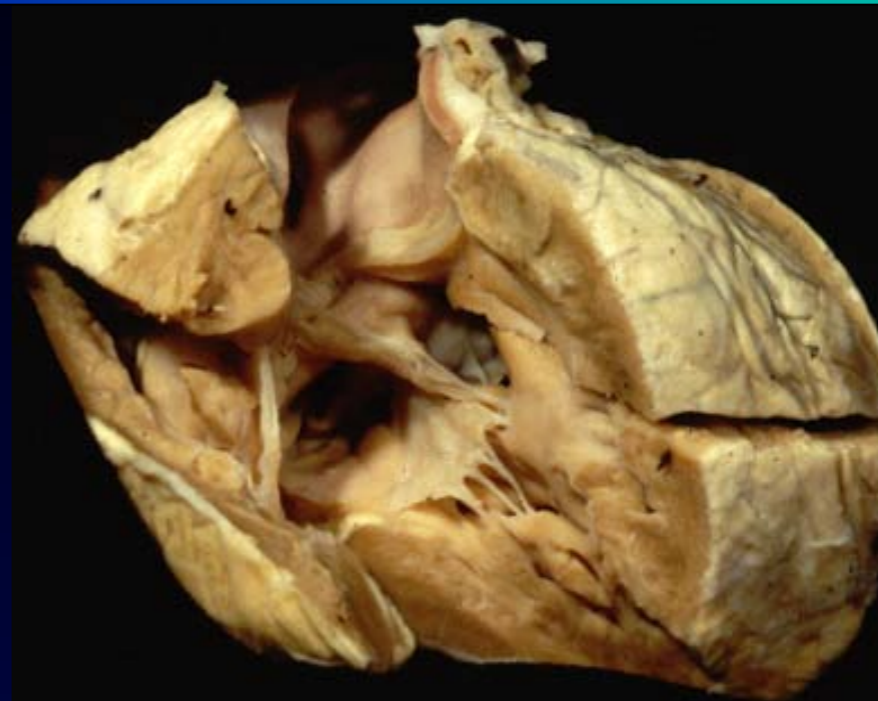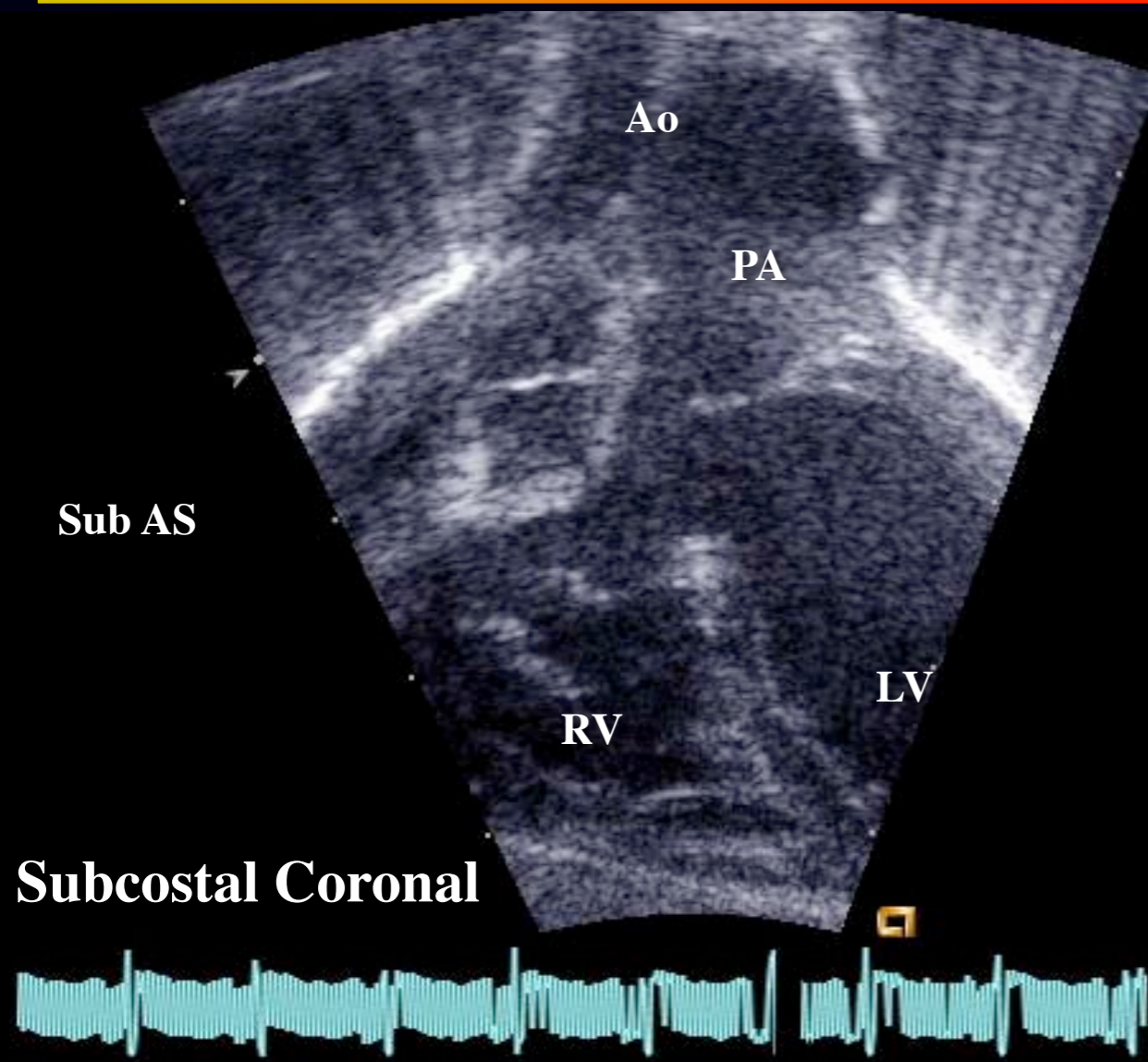
Taussig-Bing Malformation



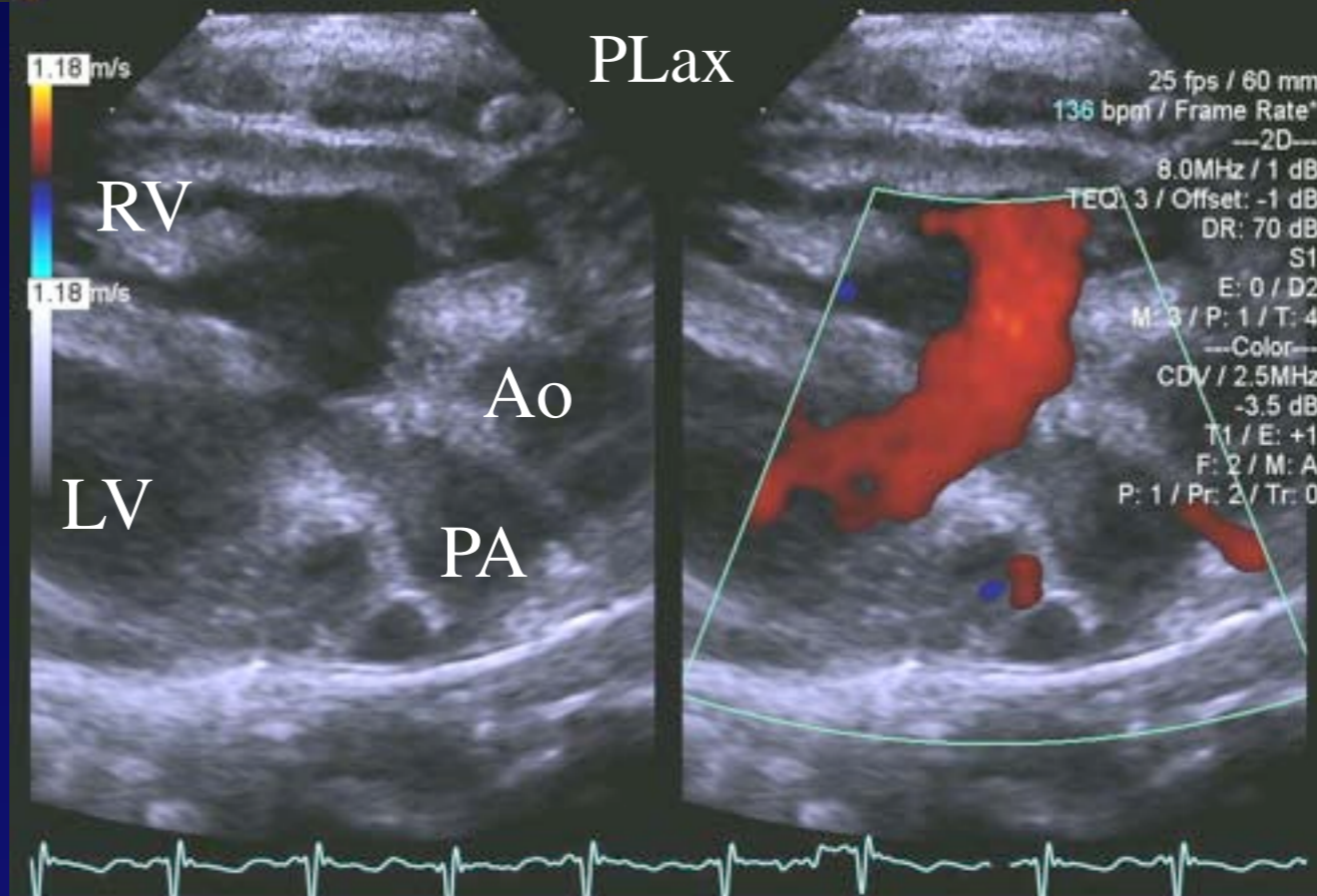
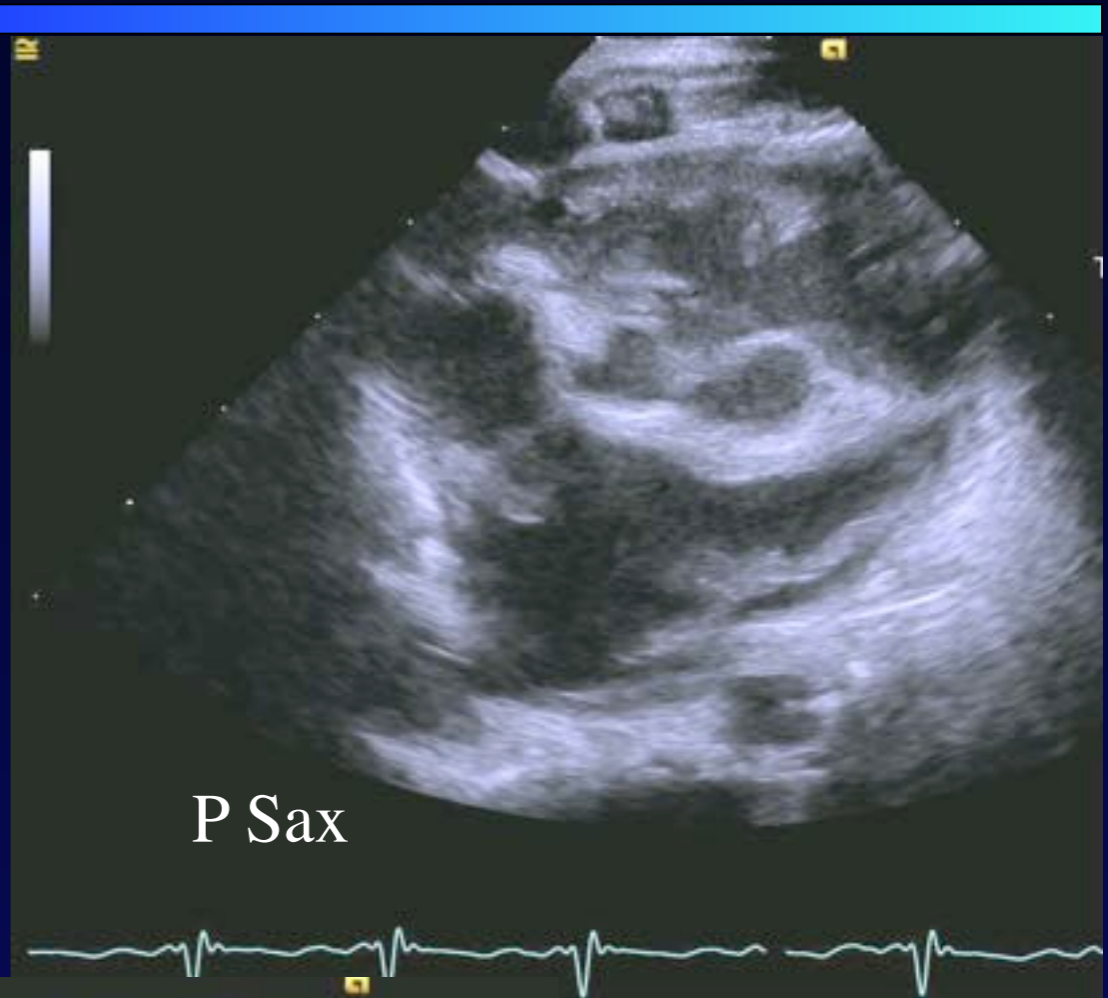
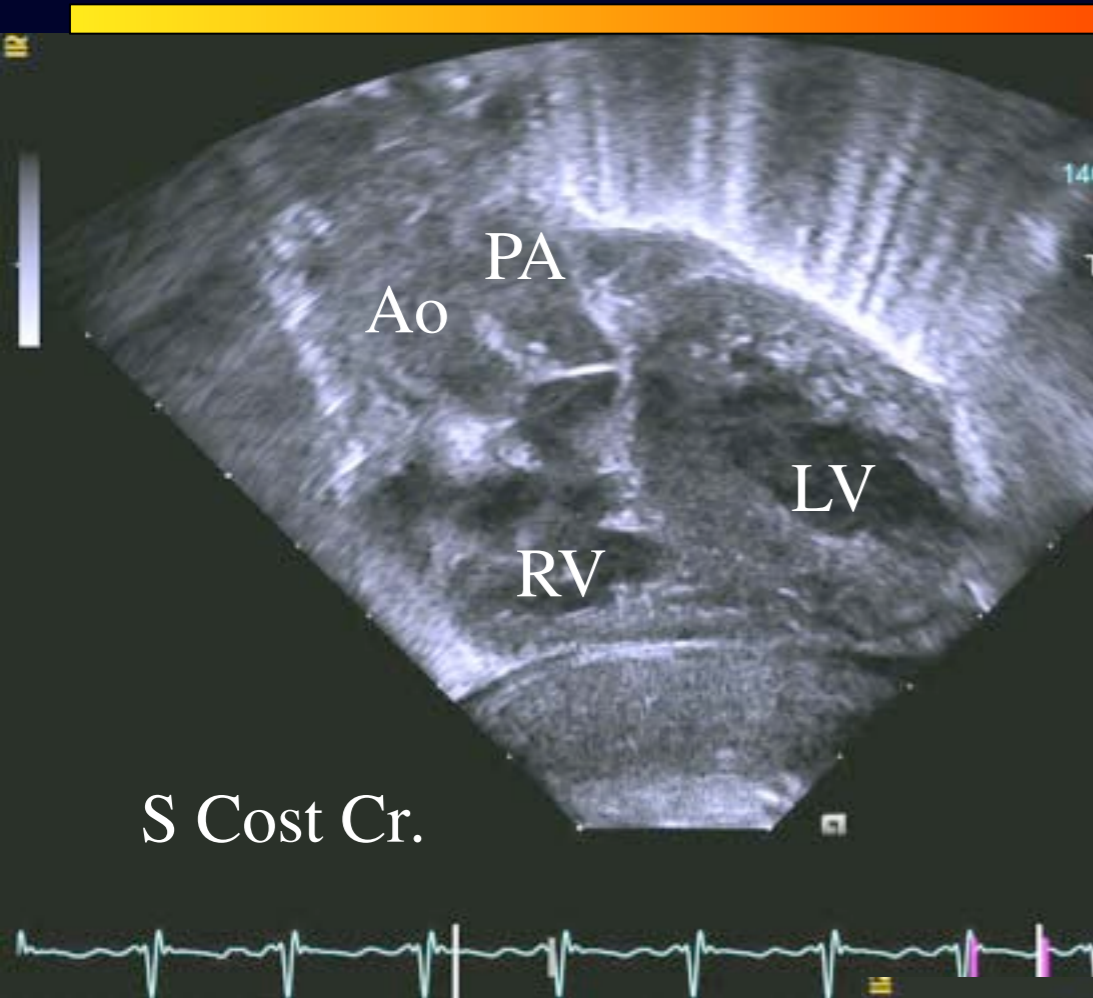
Taussig- Bing: Double Outlet



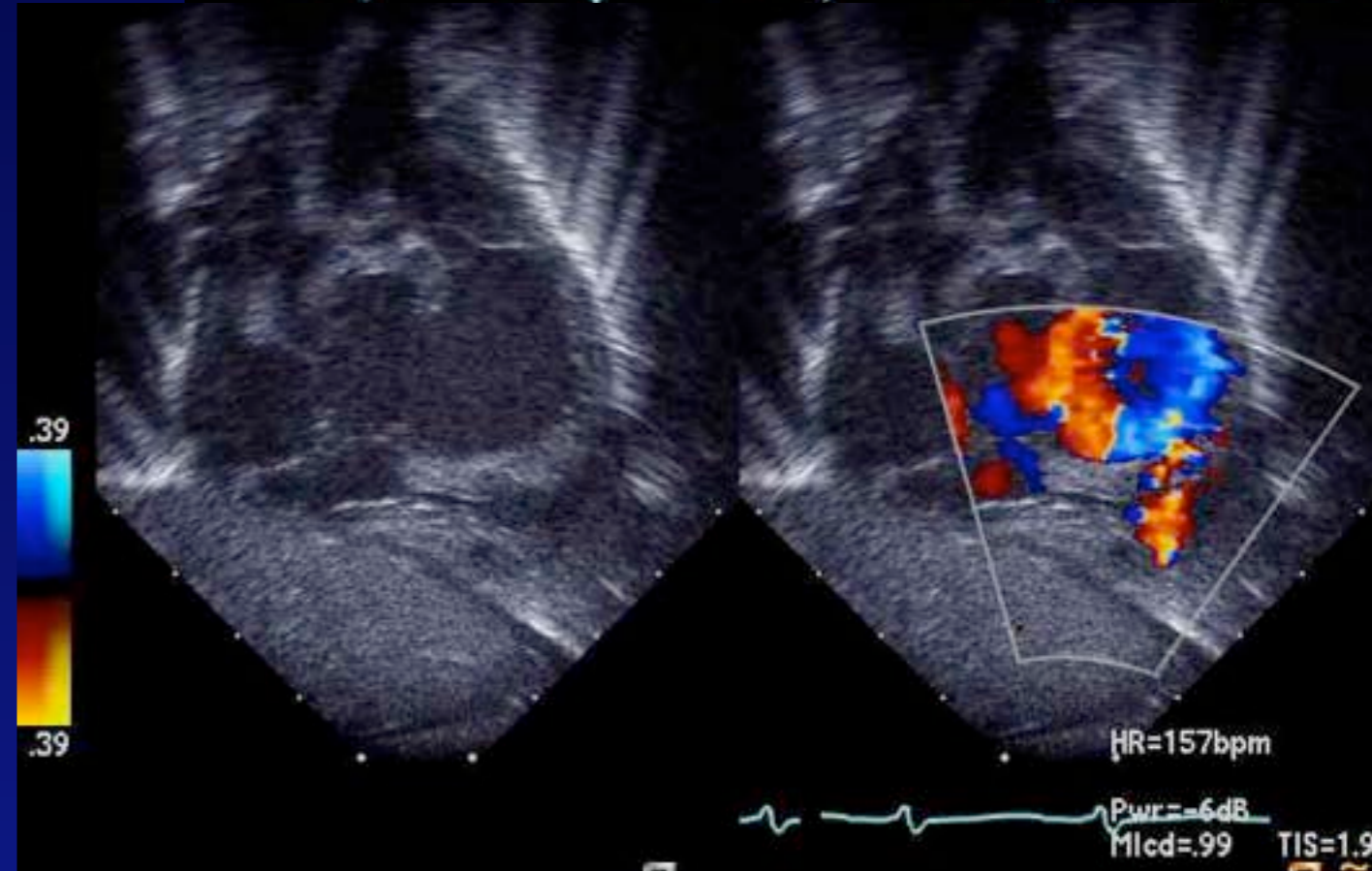
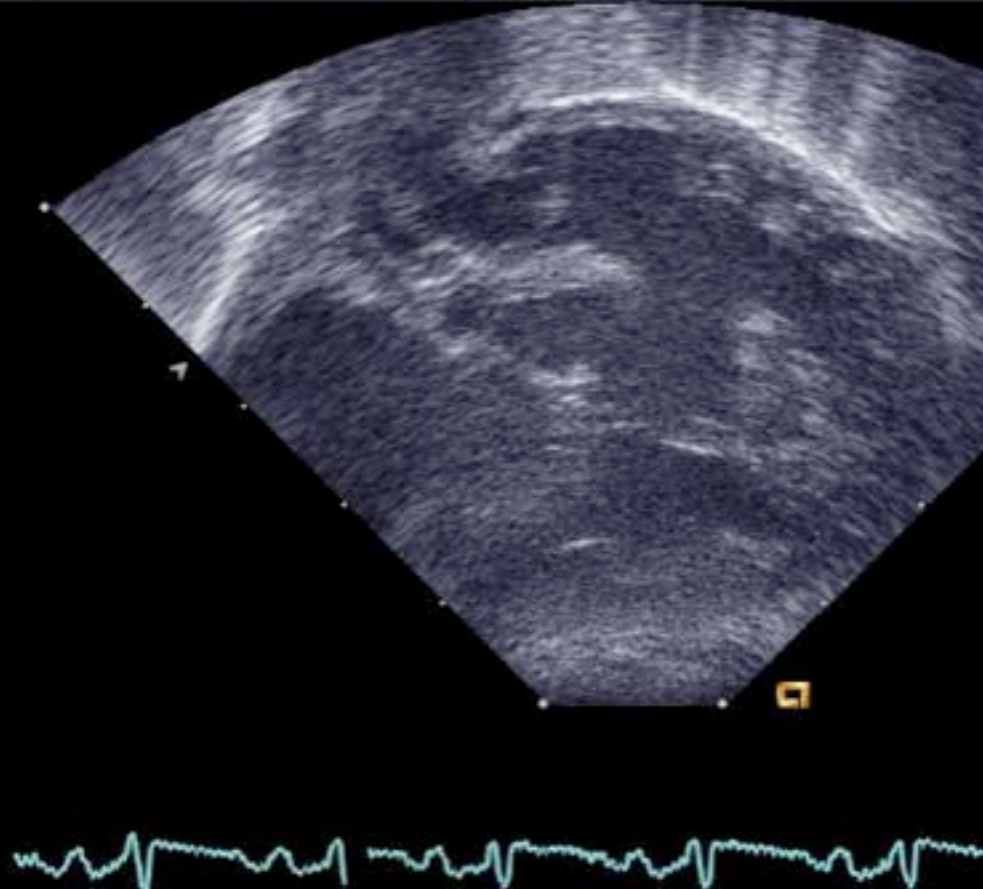
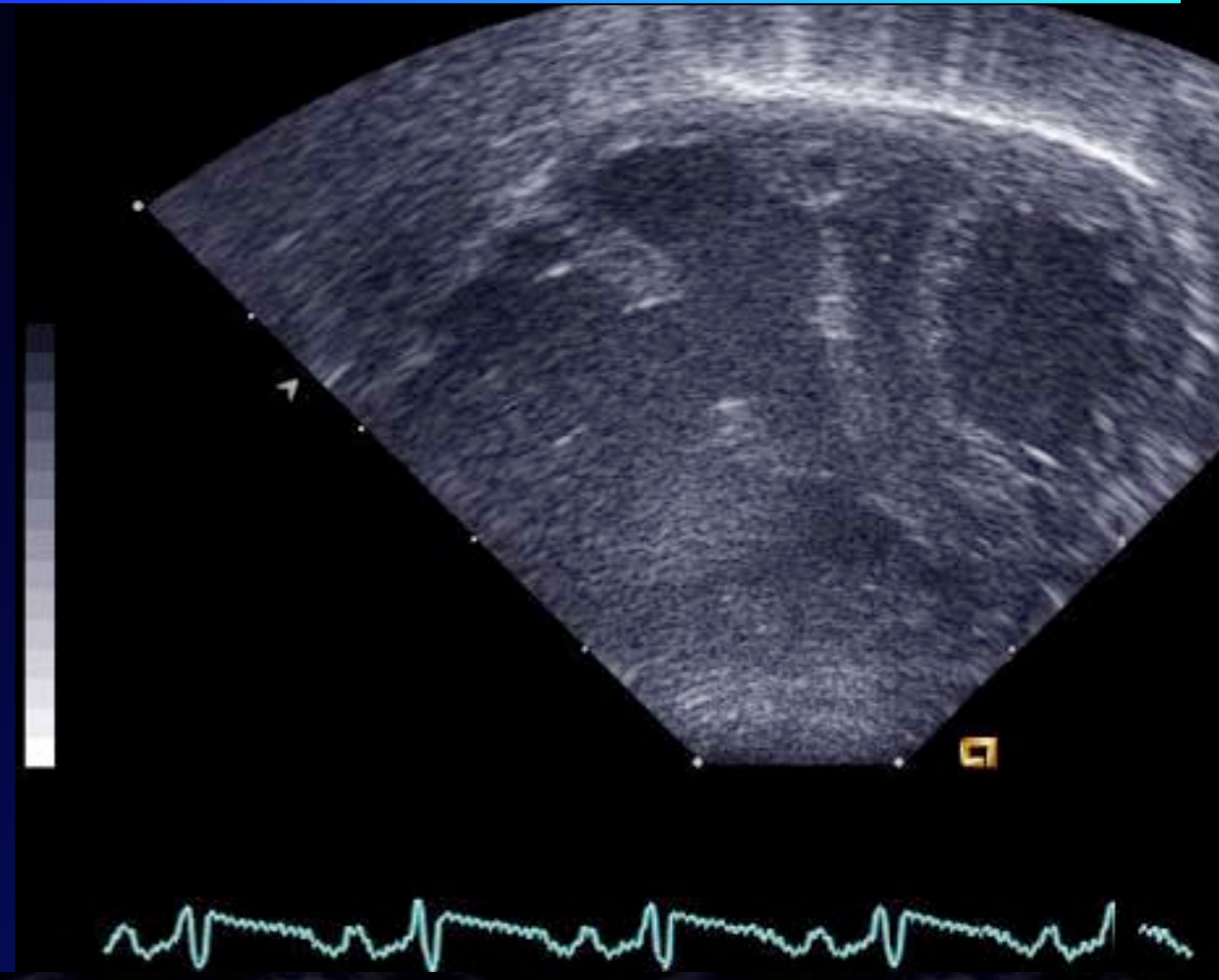
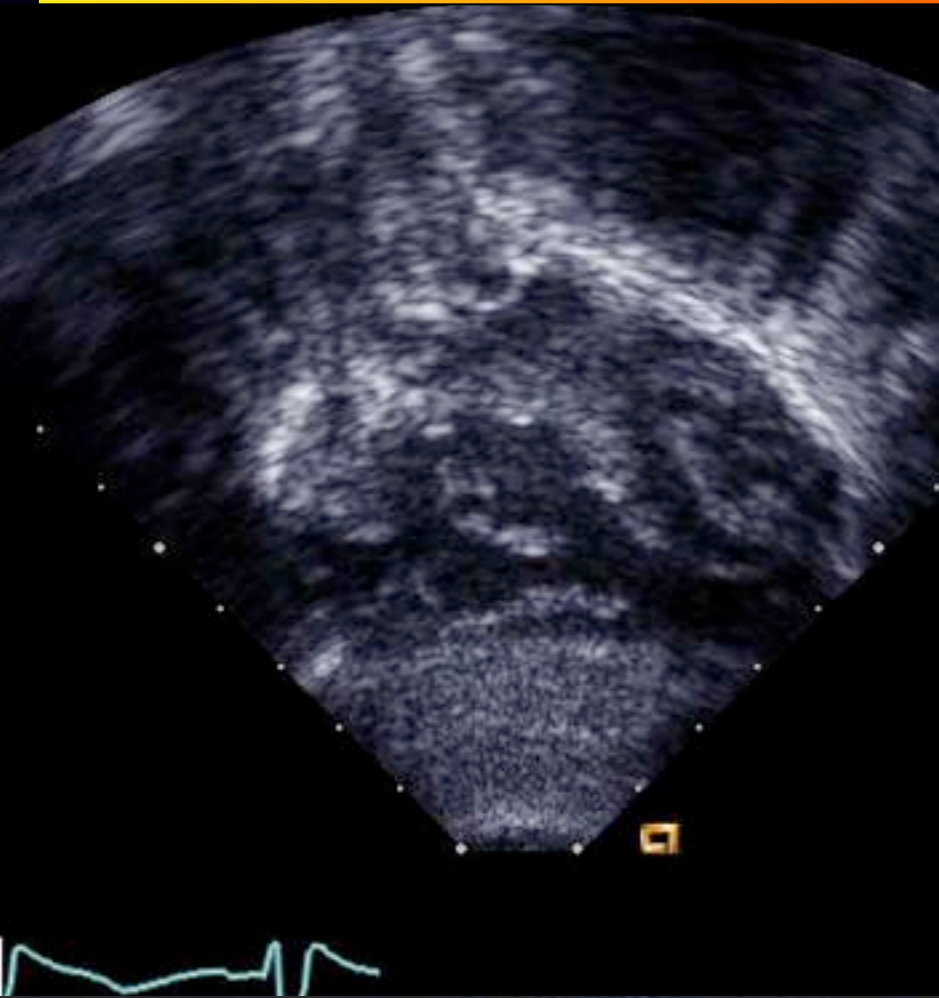
Taussig-Bing Malformation: Sub-aortic Obstruction



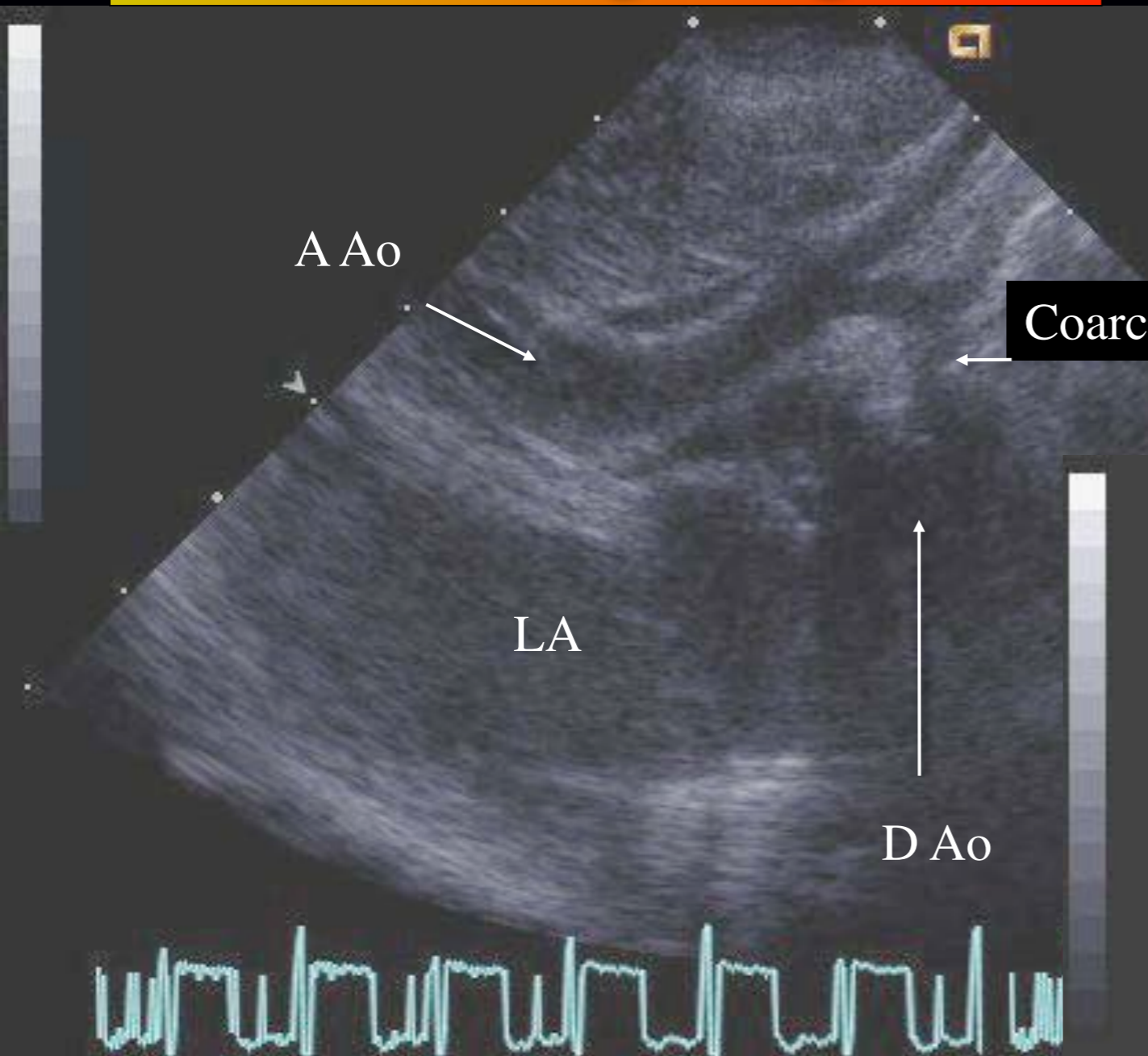
Doubly Committed Defects.



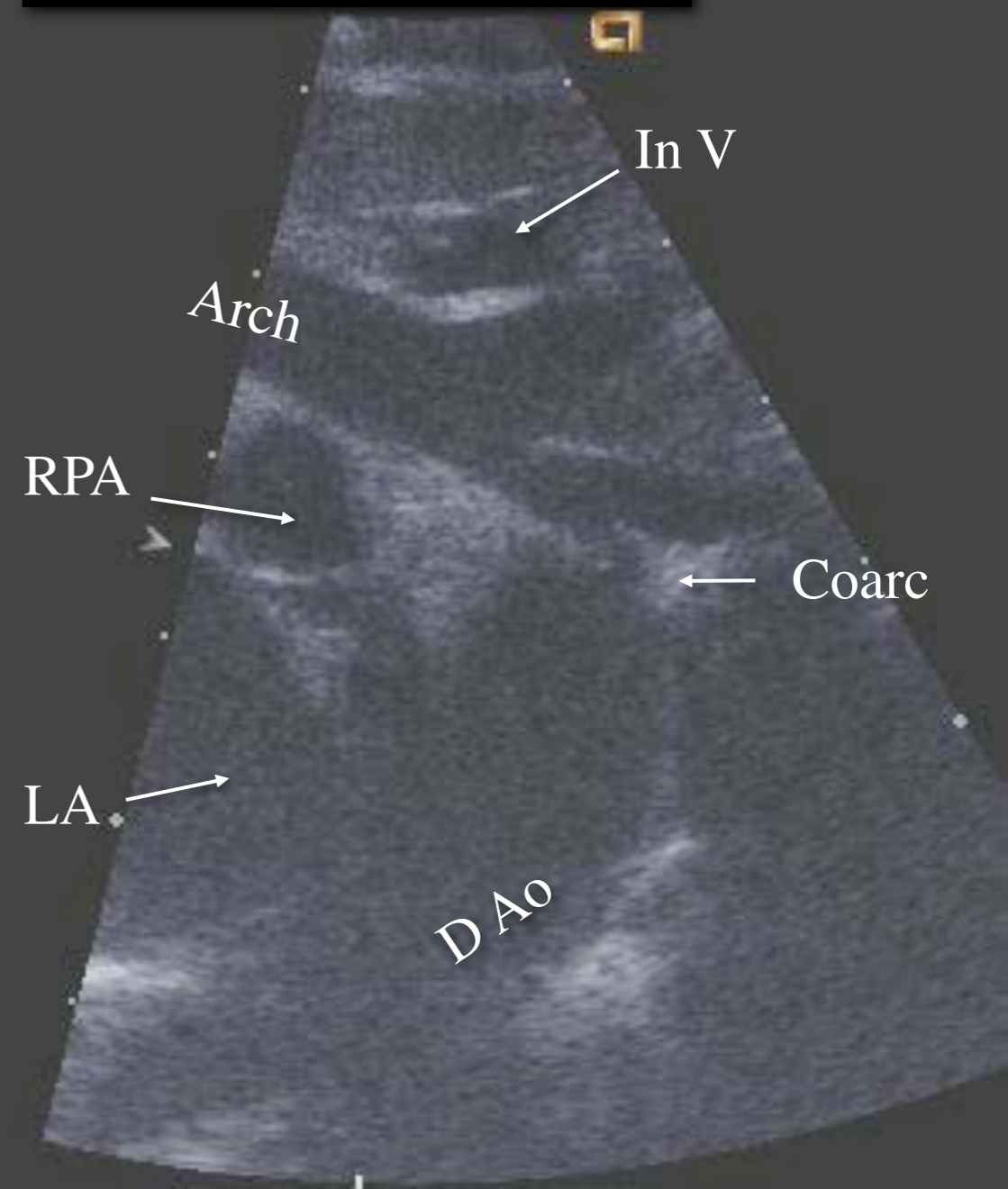
Non-Committed or Remote DORV



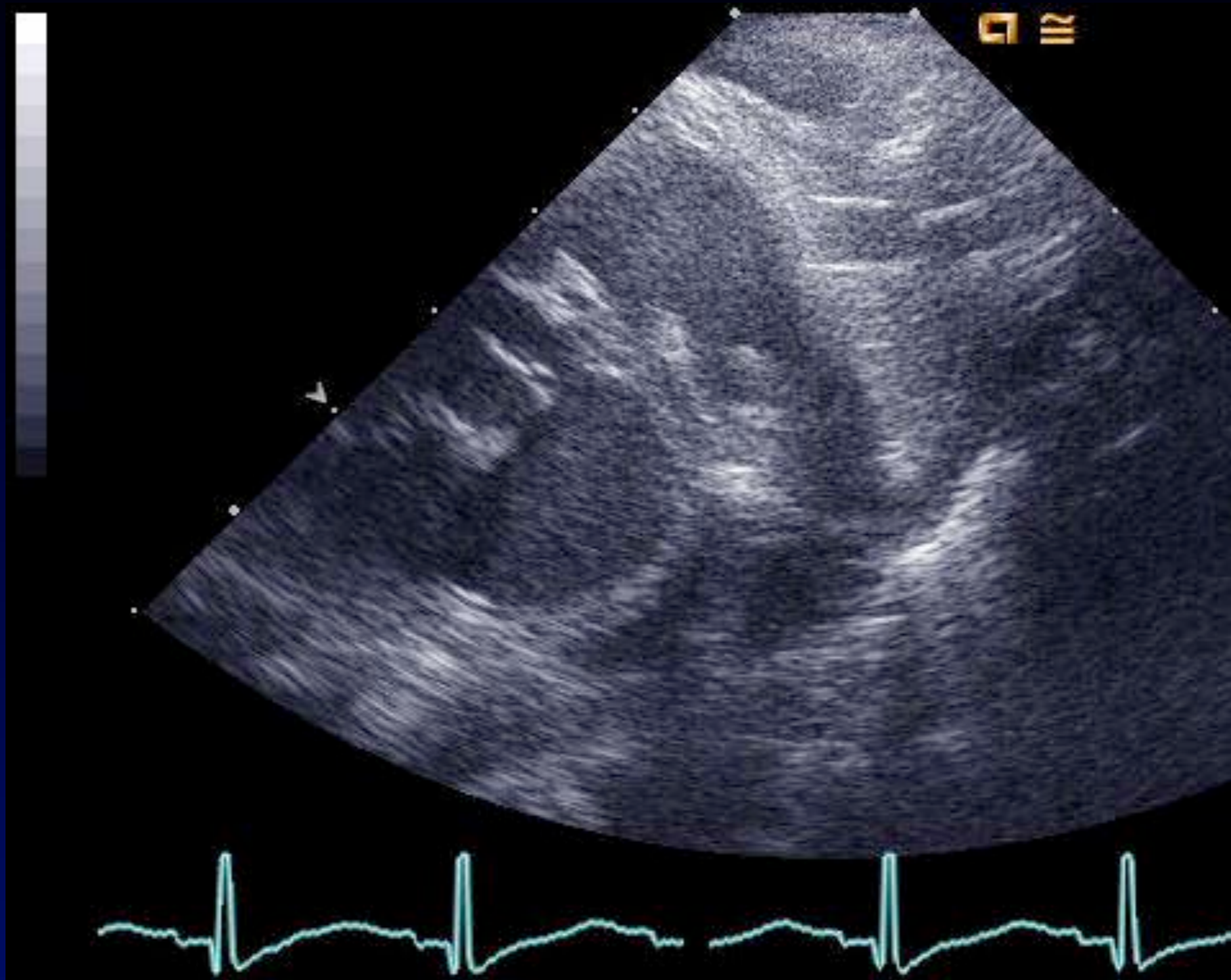
Taussig Bing Malformation: Coarctation



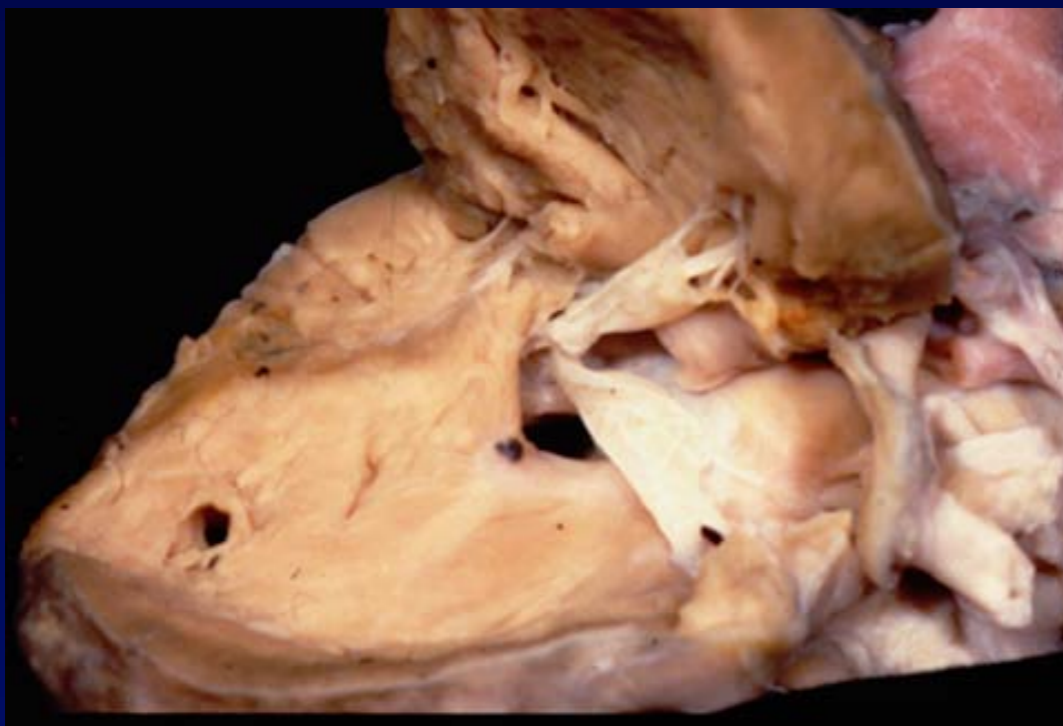
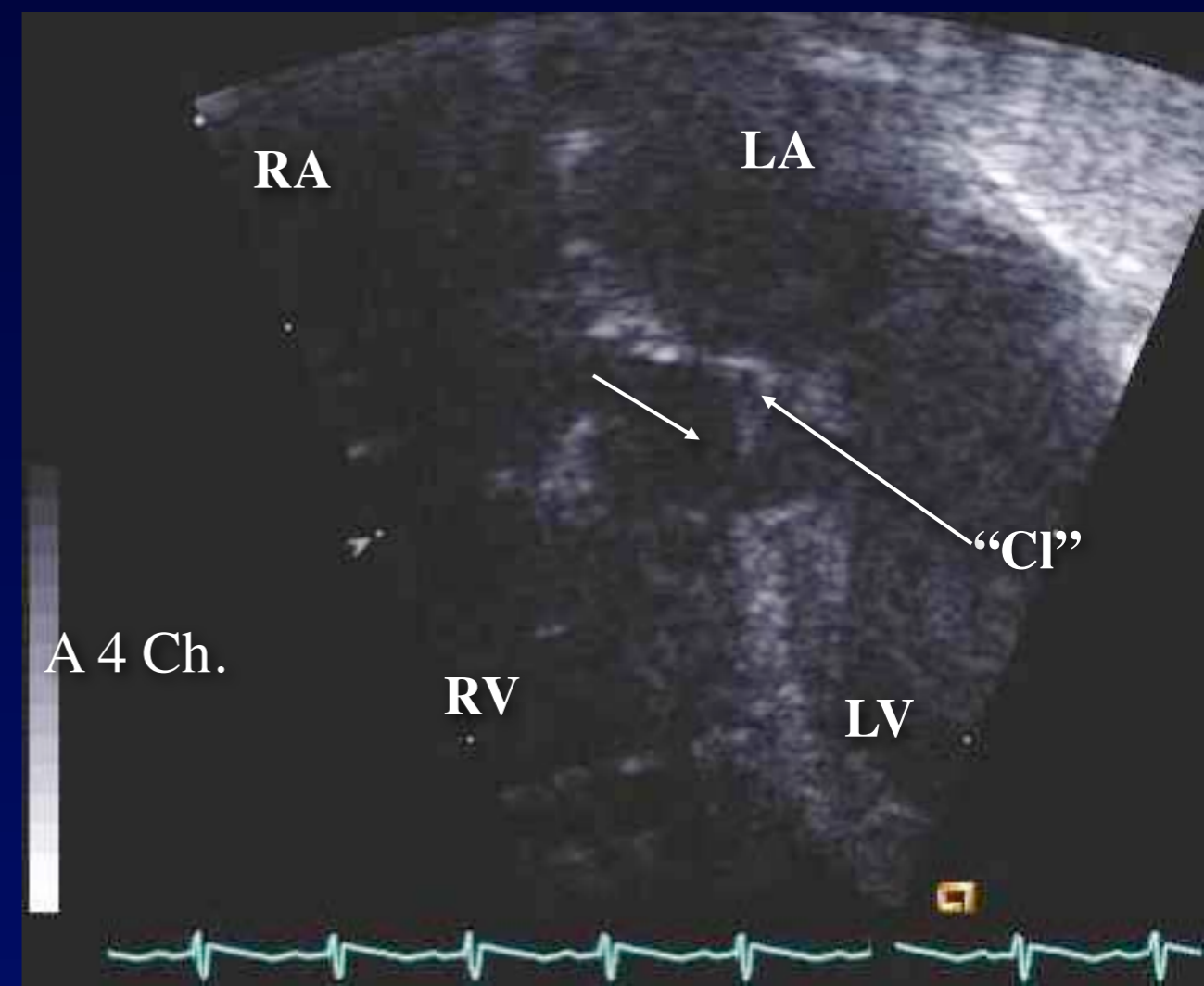
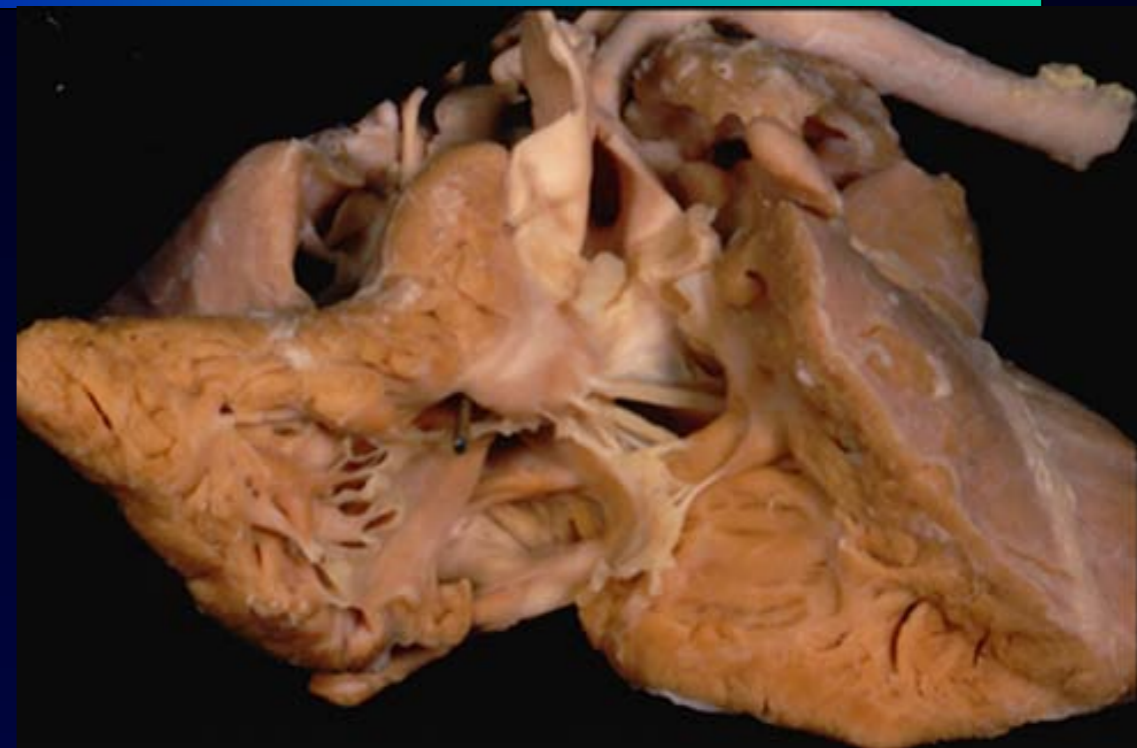
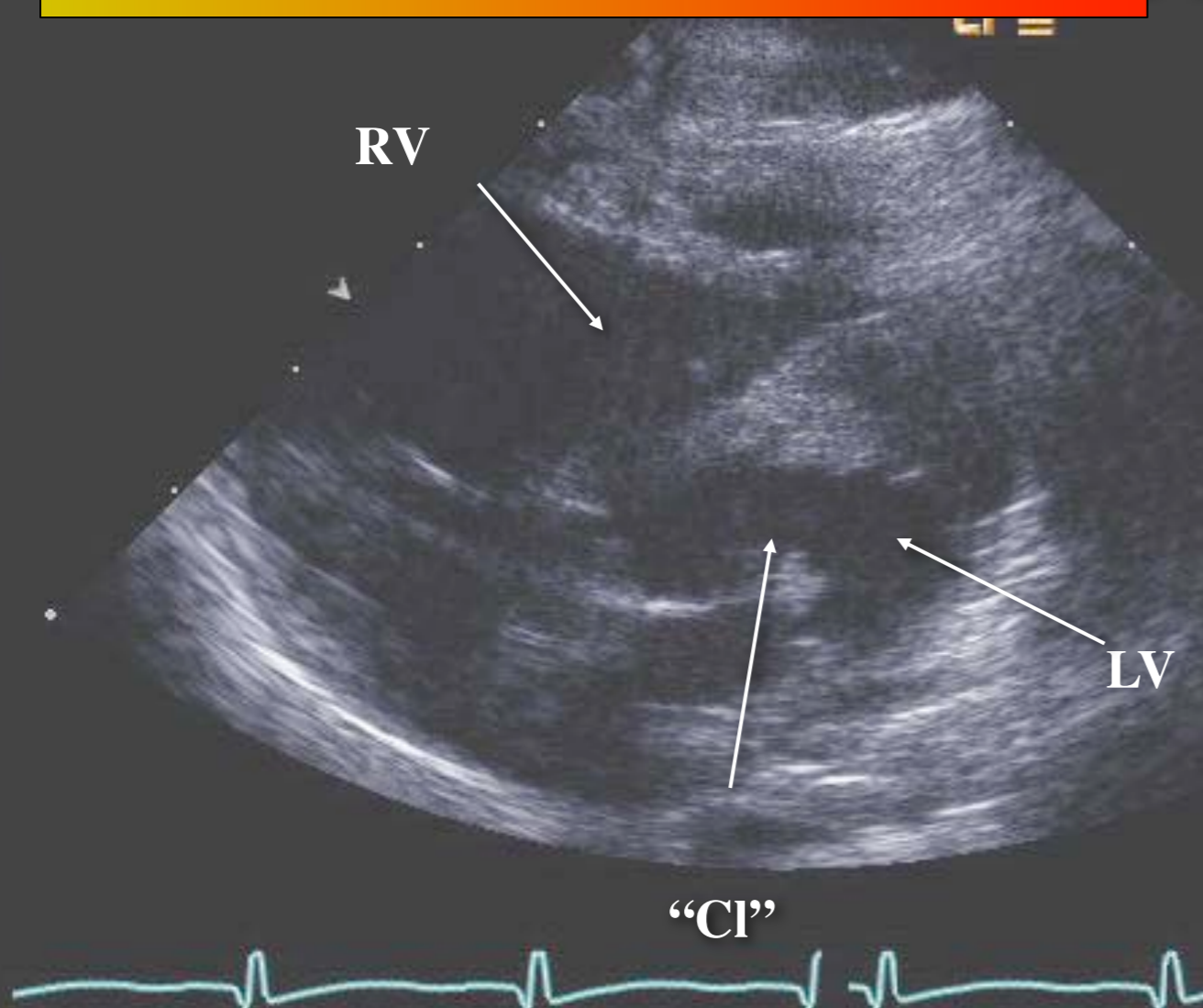
Taussig Bing Malformation



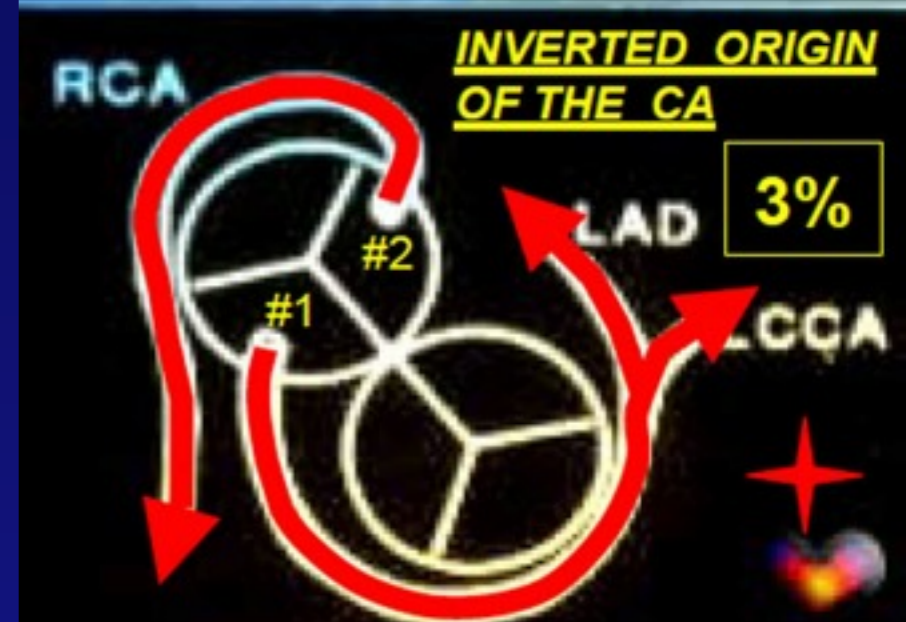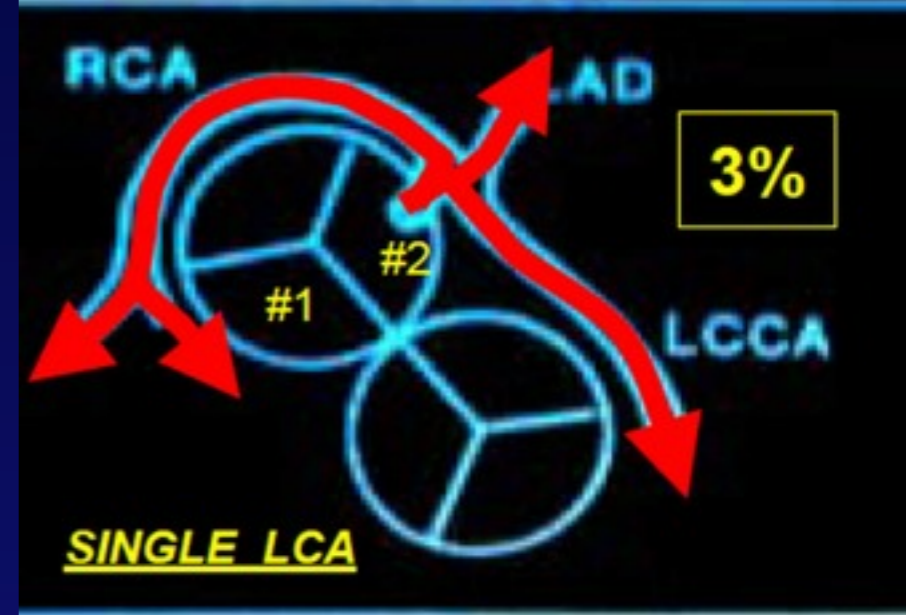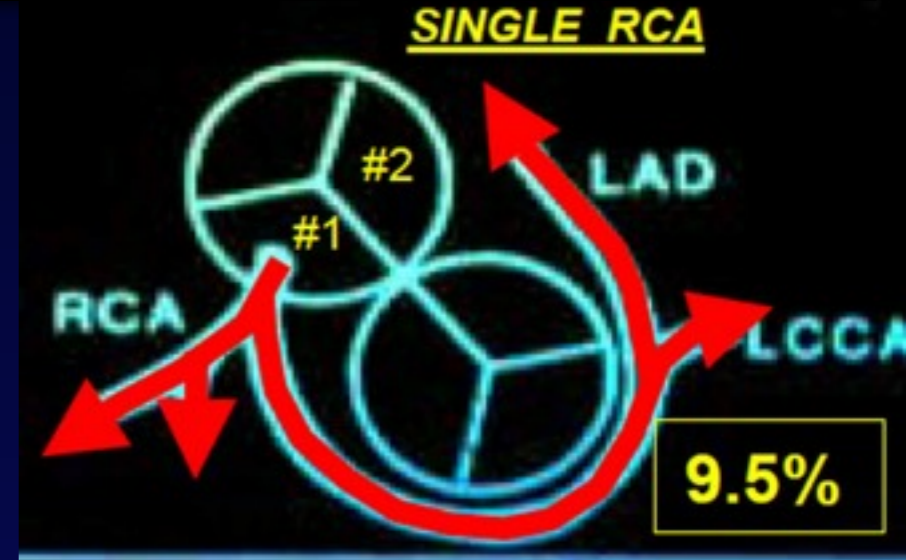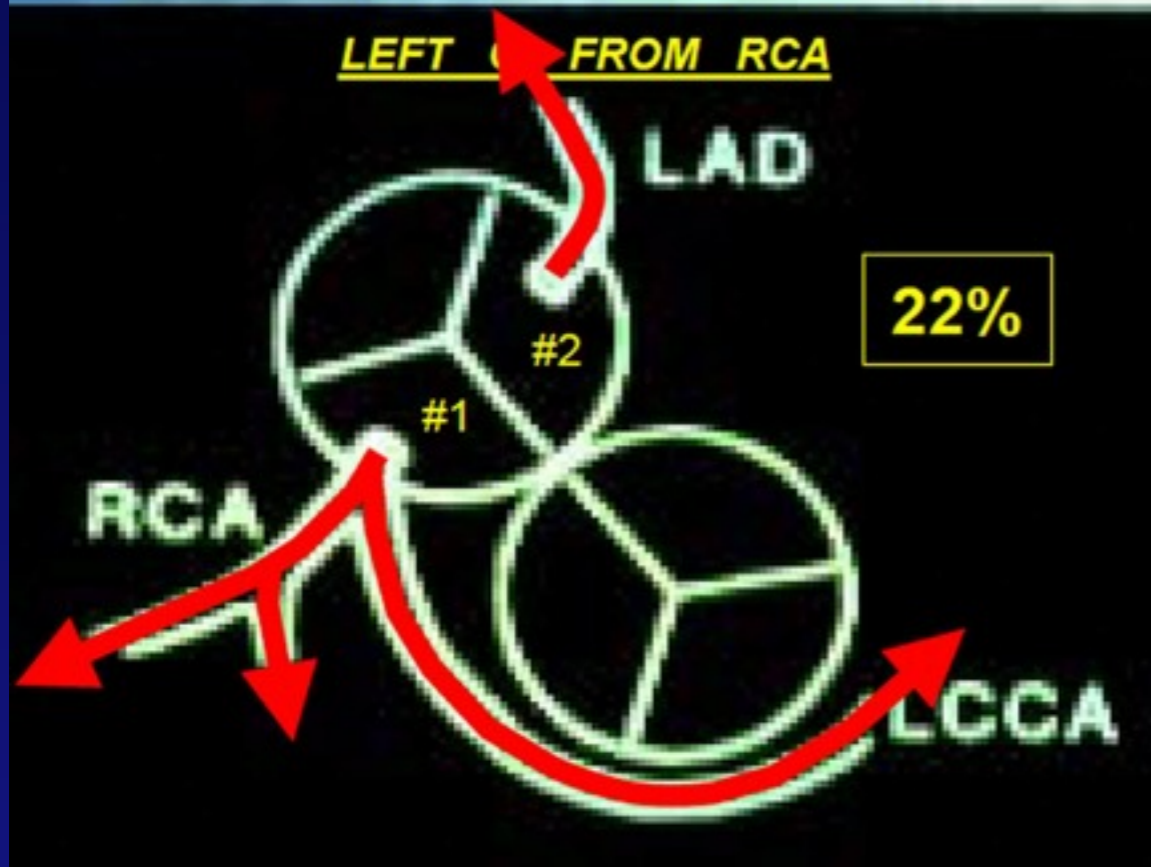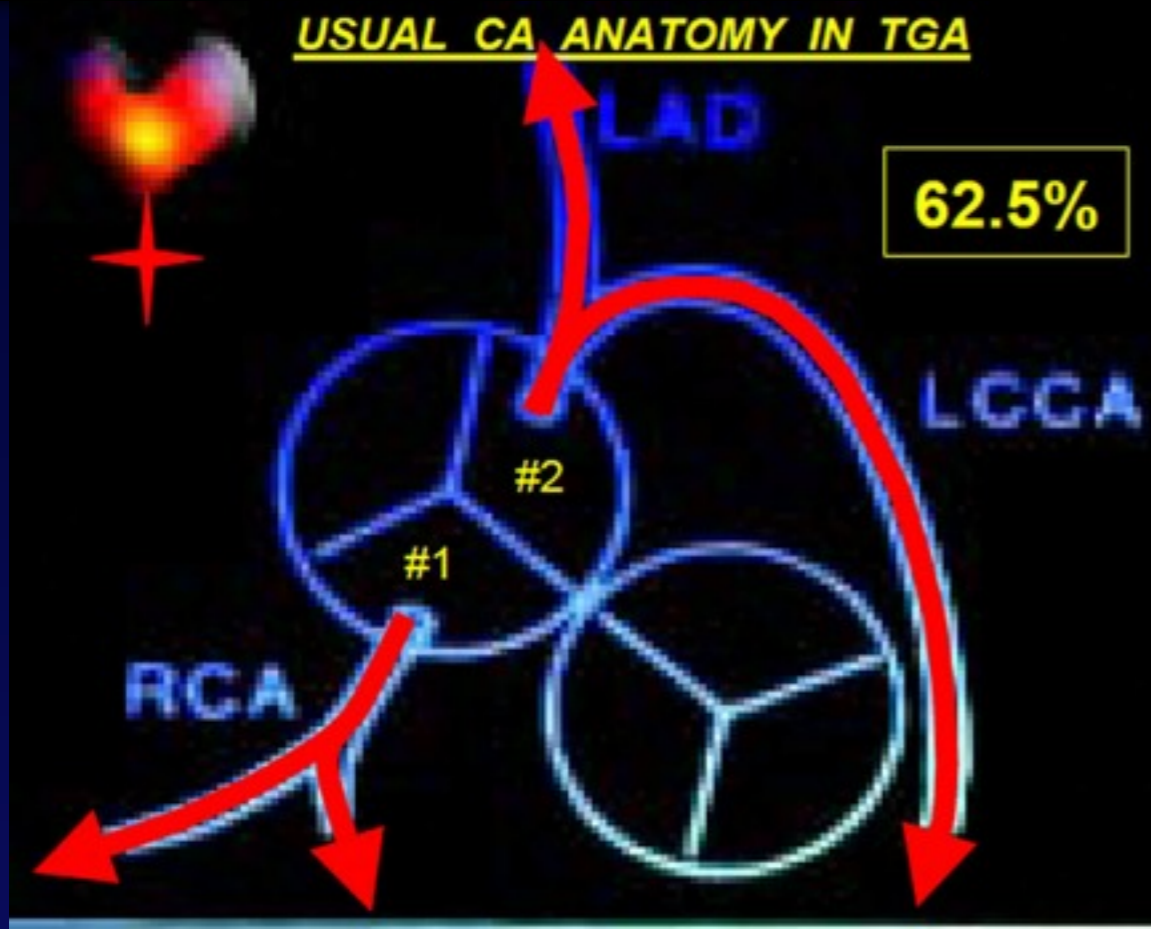
Interrupted Aortic Arch (Type B)



DORV:Cleft Mitral Valve



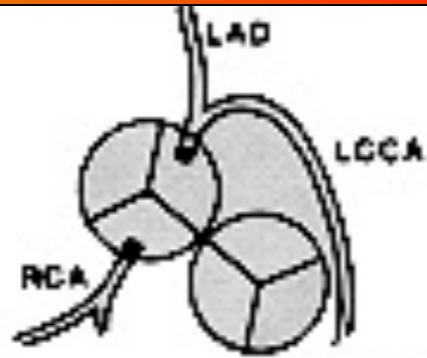
Coronary Artery Patterns in TGA



After Pasquini

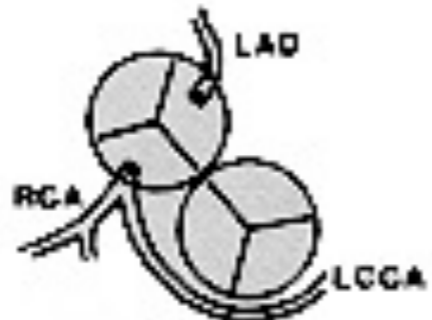
Coronary Arterial Course in Transposition

1
Usual Coronary Anatomy
in TGA



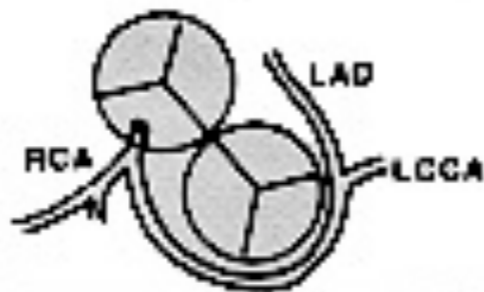20/32
(62.5%)

2
Left Circumflex Coronary
from the
Right Coronary Artery



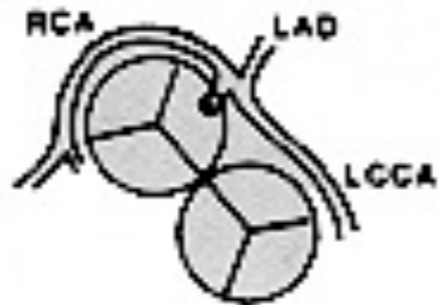
7/32
(22%)

3
Single
Right Coronary Artery



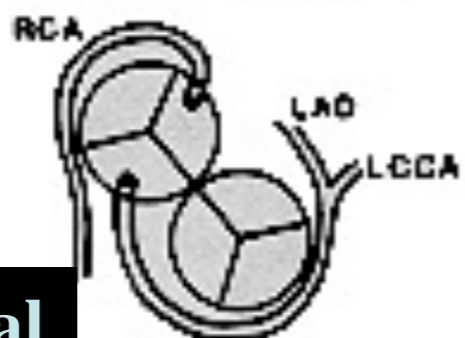
3/32
(9.5%)

4
Single
Left Coronary Artery




1/32
(3%)

5
Inverted Origin of
the Coronary Arteries



1/32
(3%)

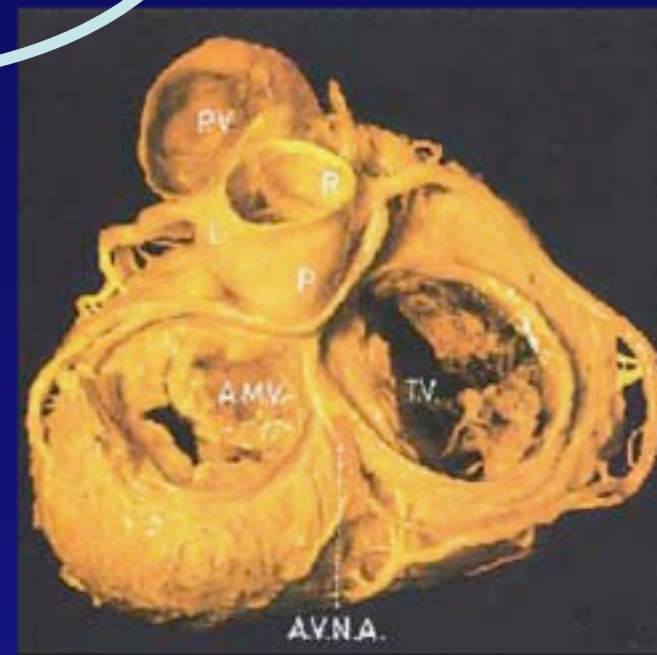
No Posterior Coronary Artery



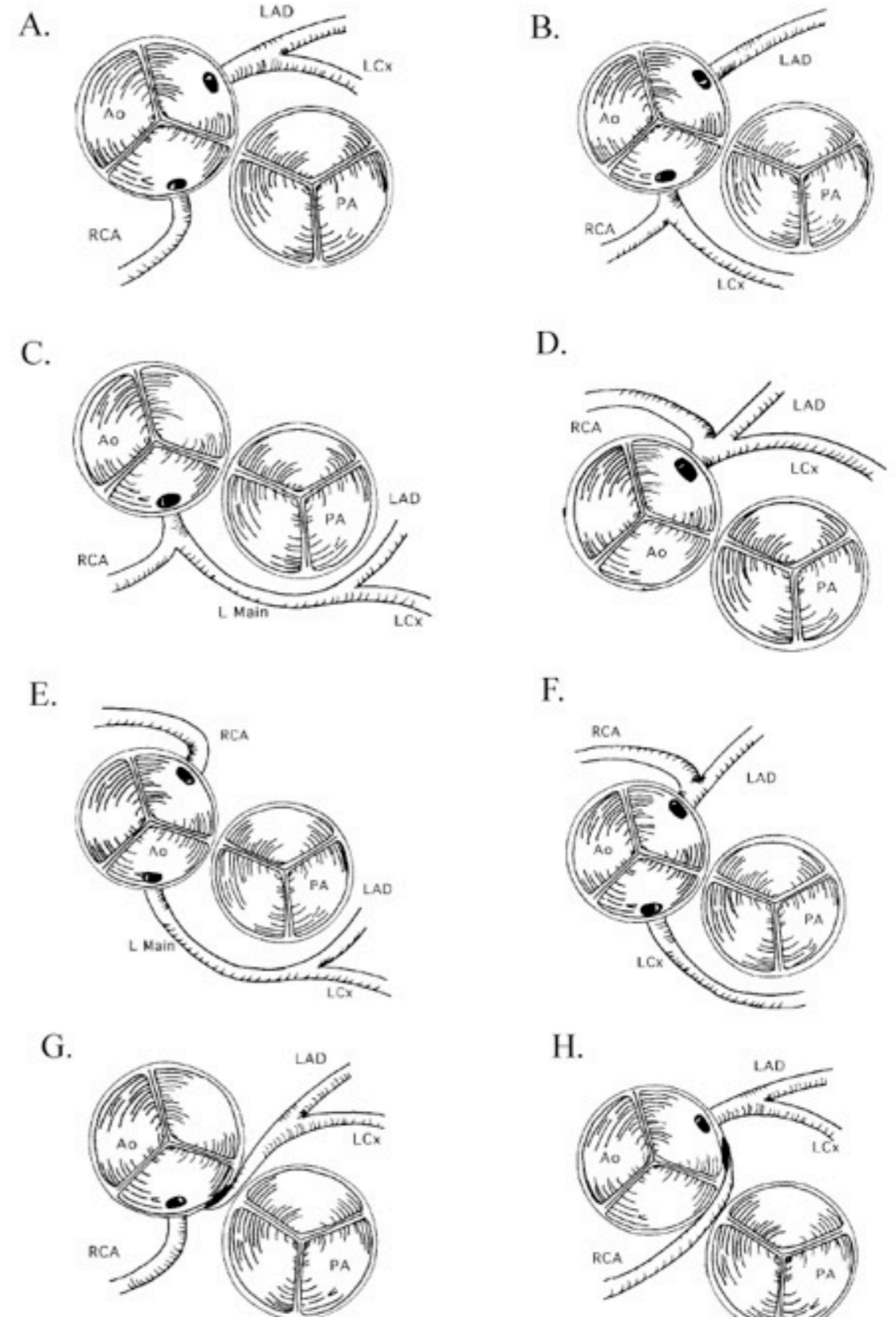
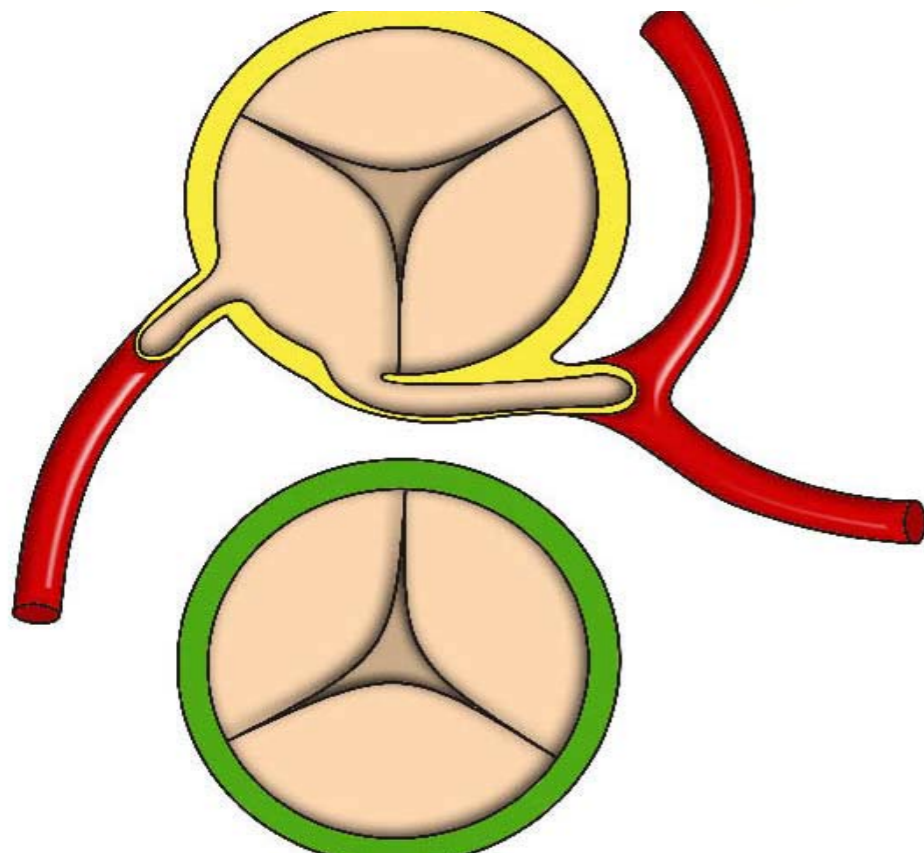
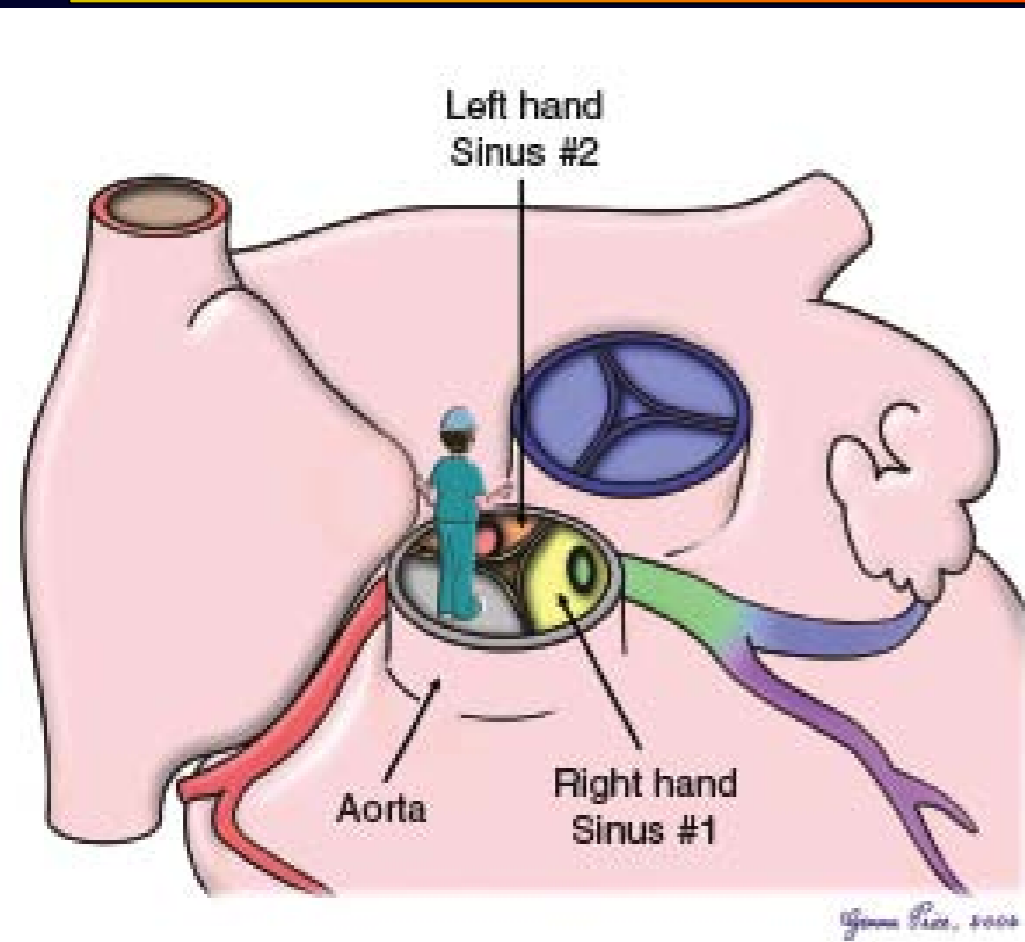
Options: 1 or 4

Posterior Coronary Artery

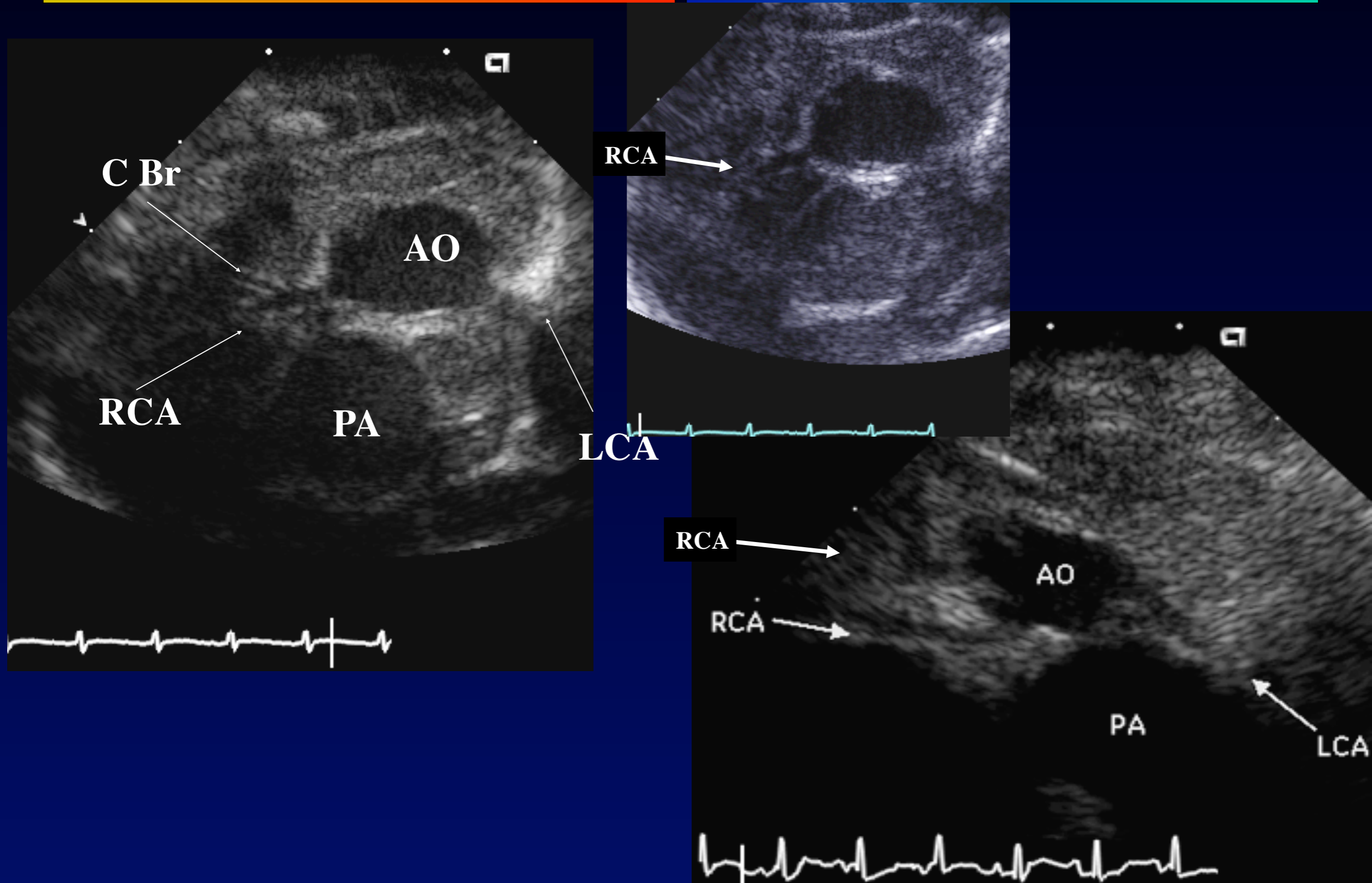
Options: 2, 3 or 5



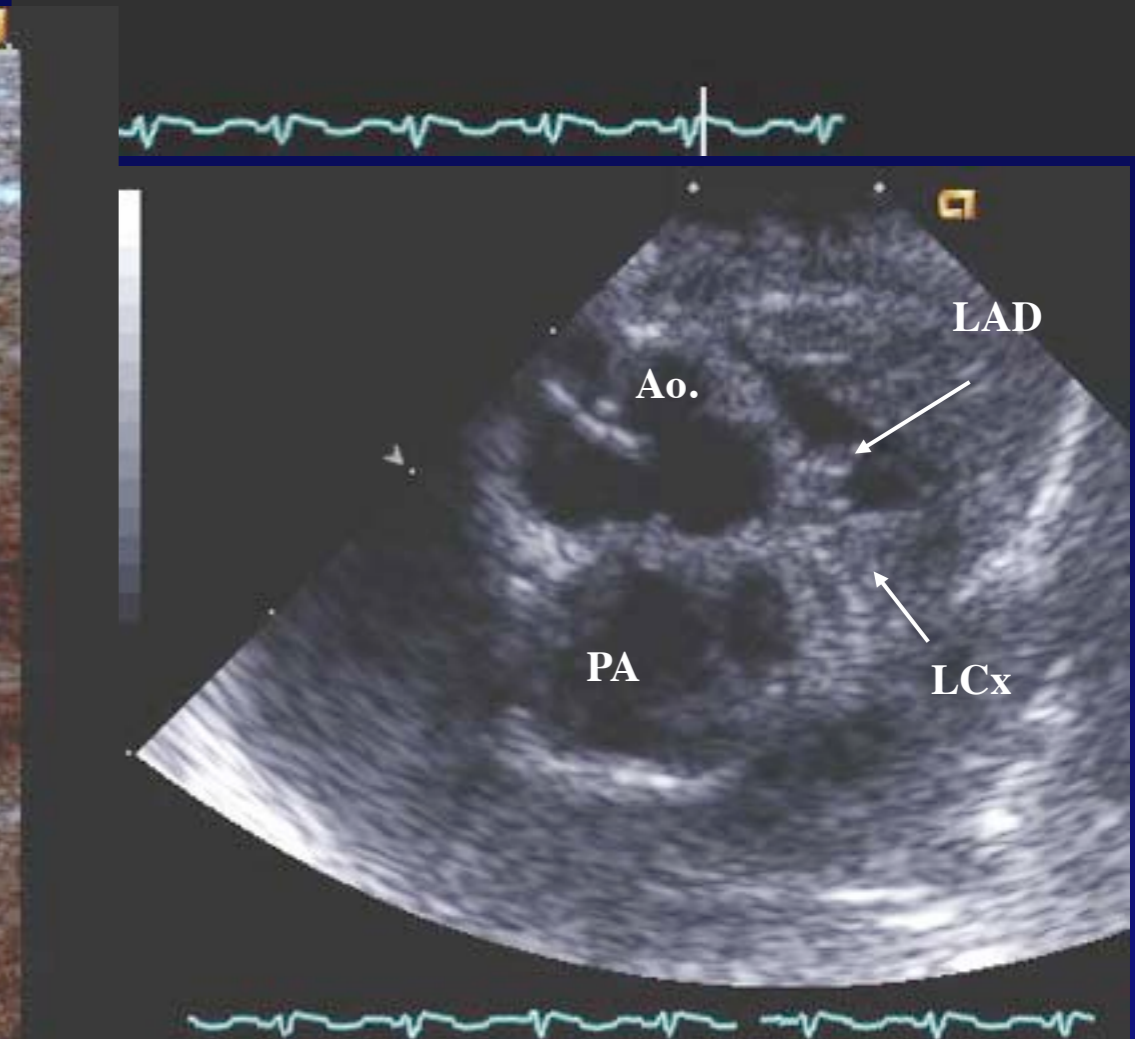
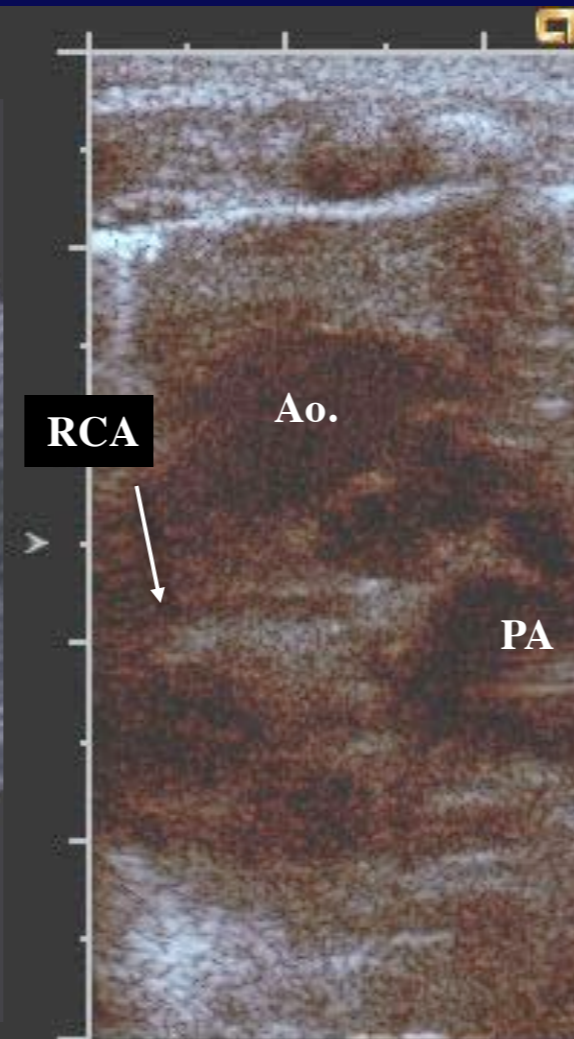
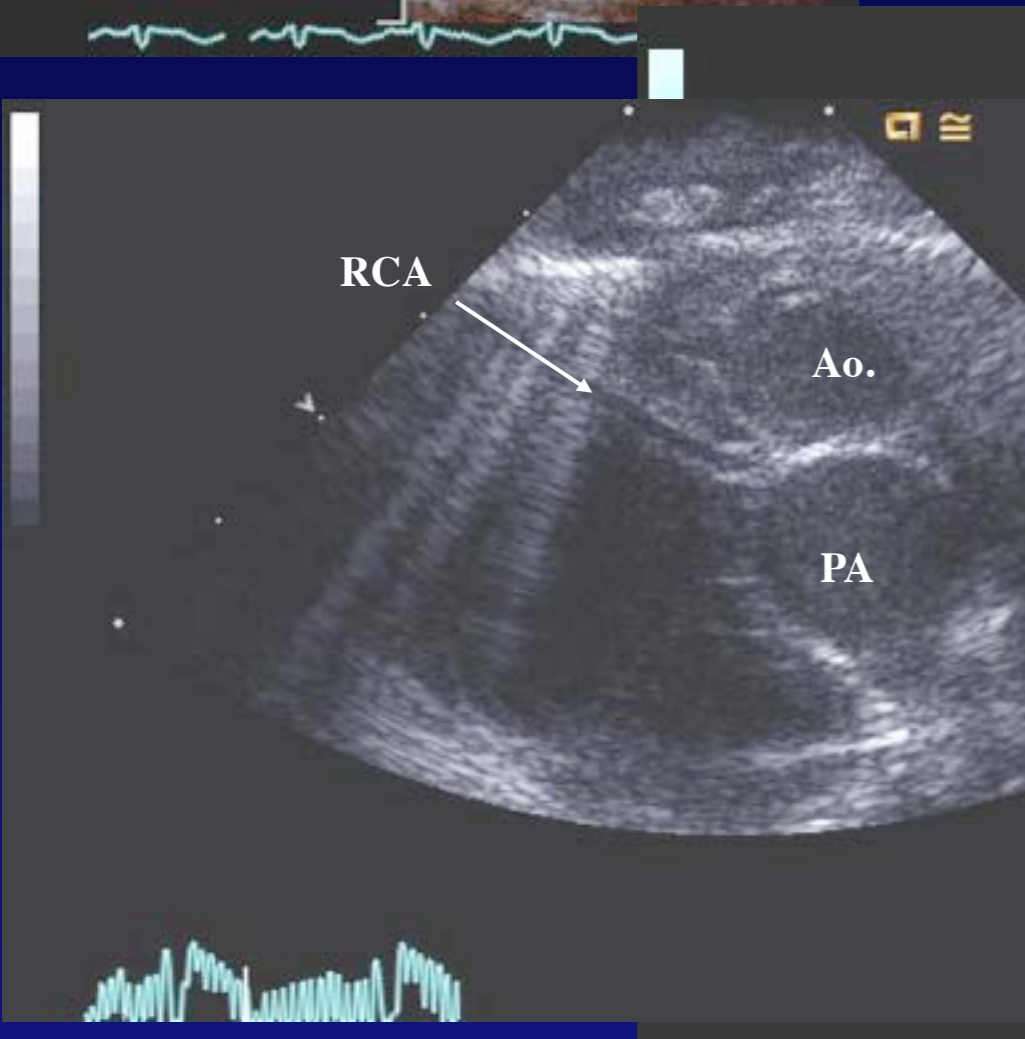
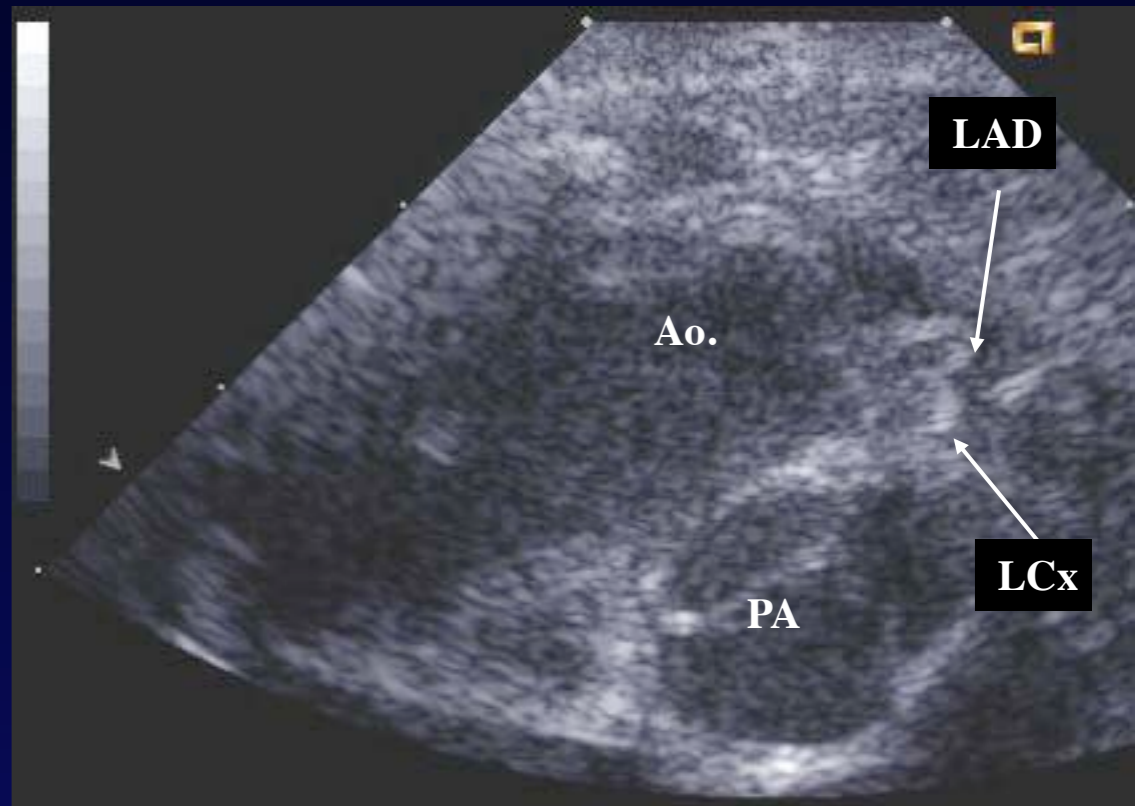
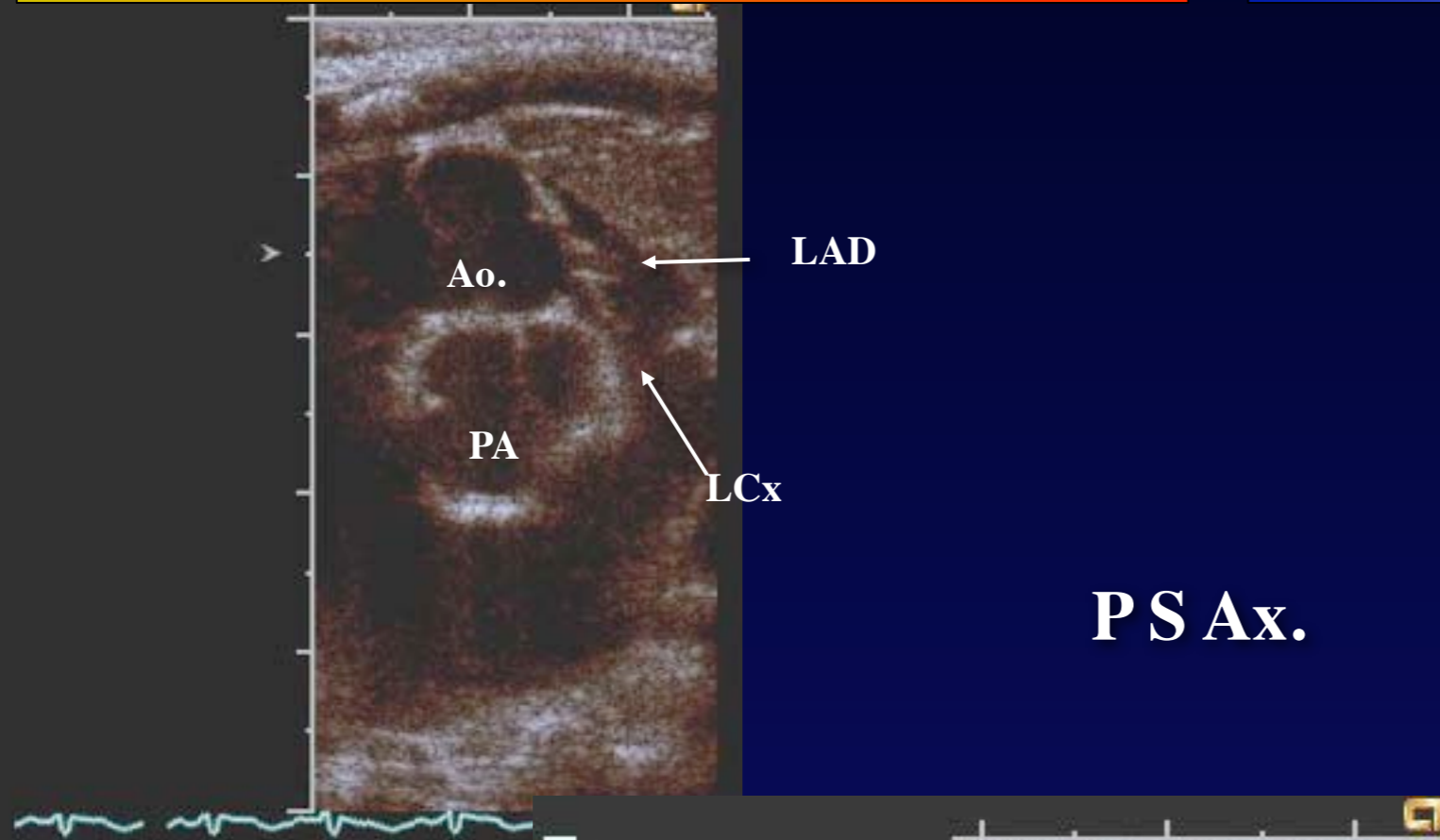
TGA: Coronary Arteries.



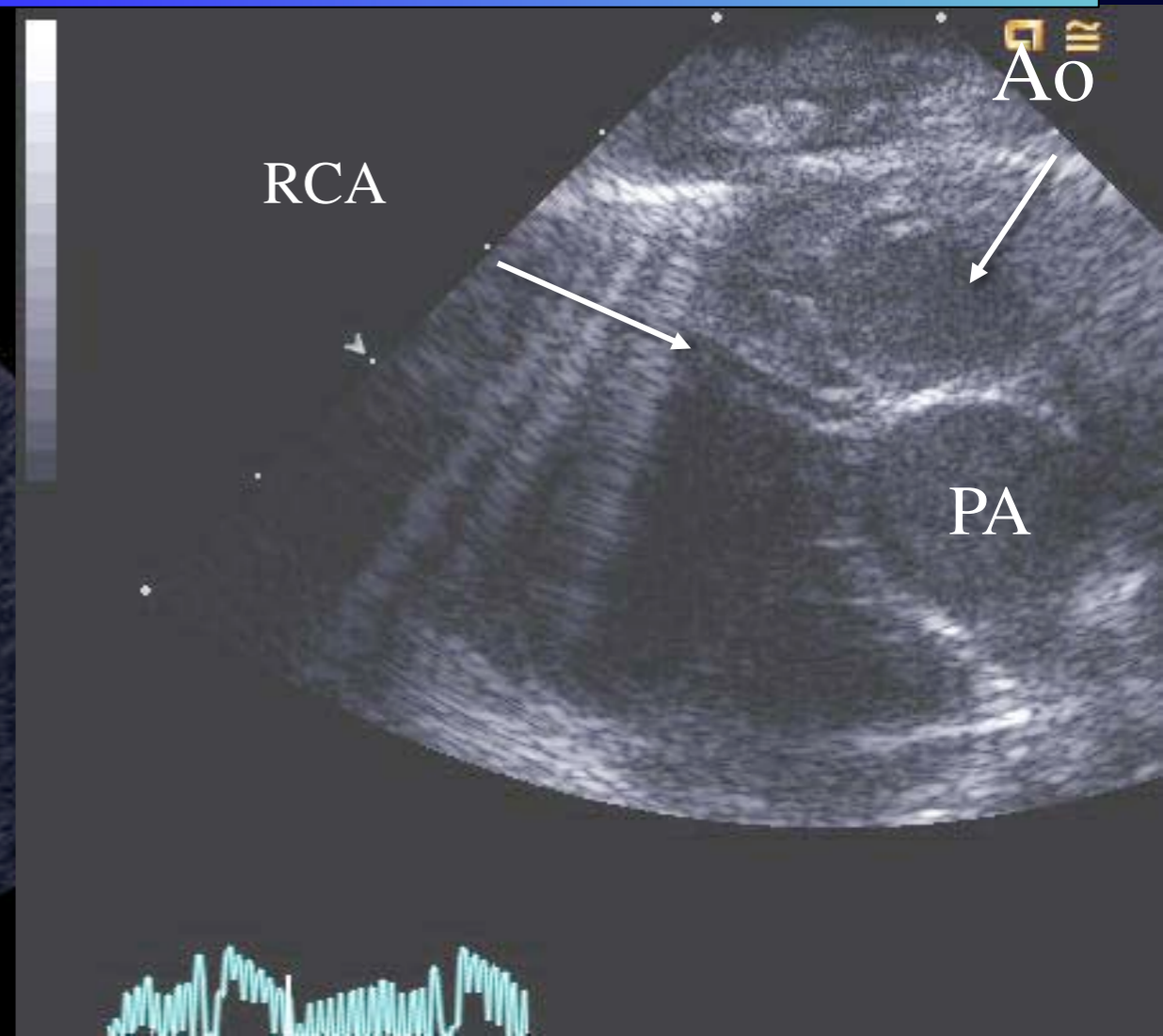
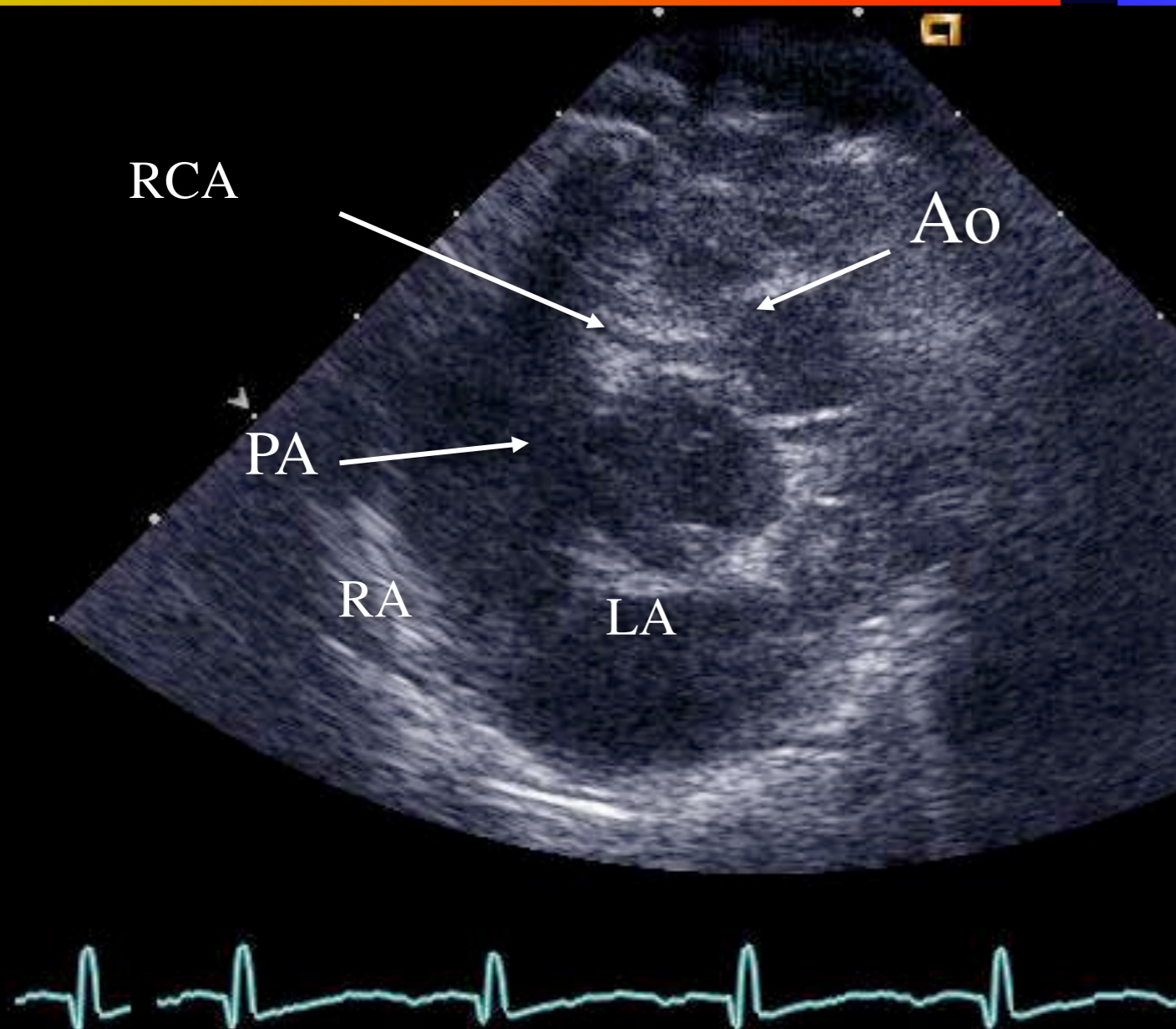
Coronary Arteries in TGA



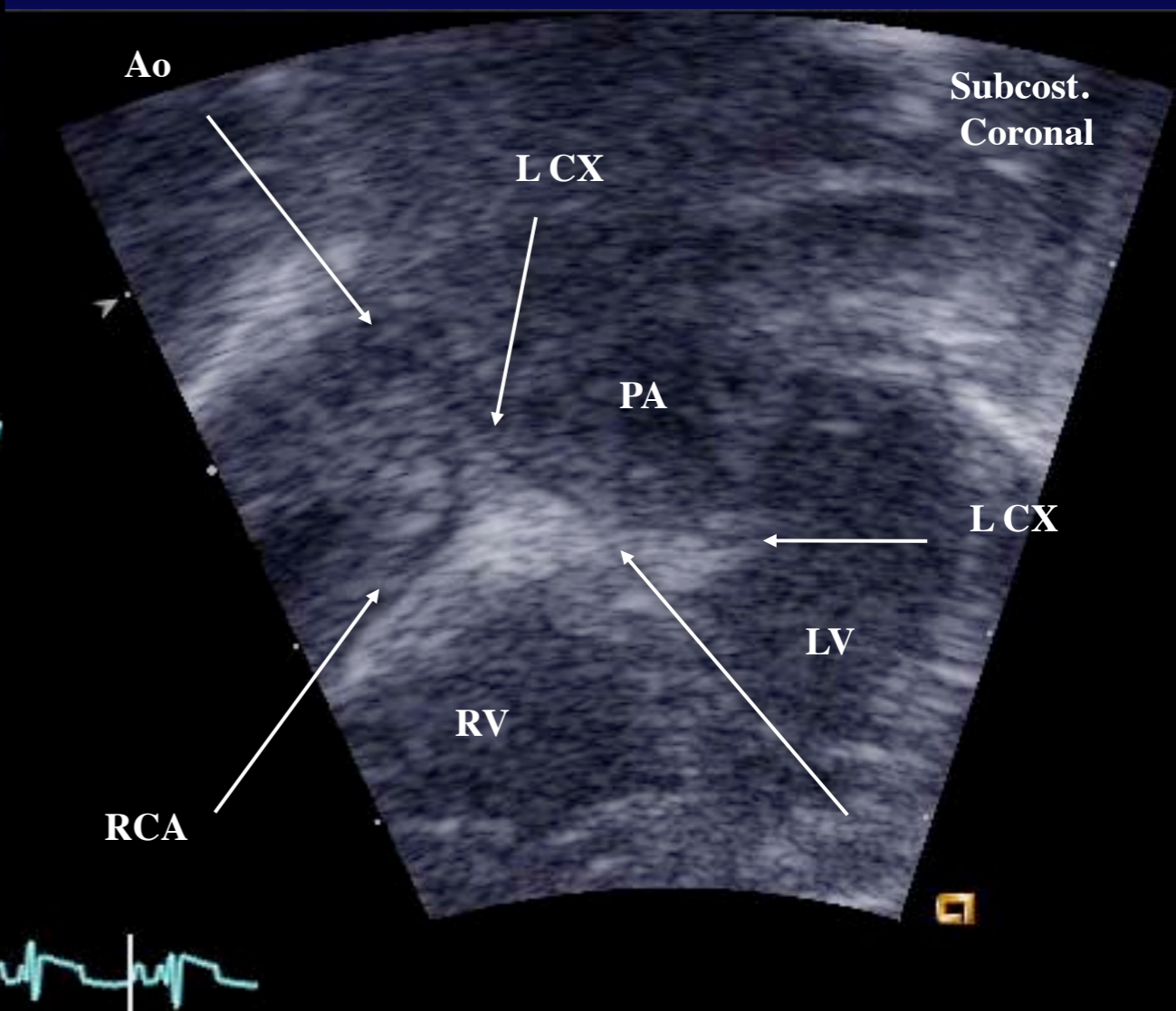
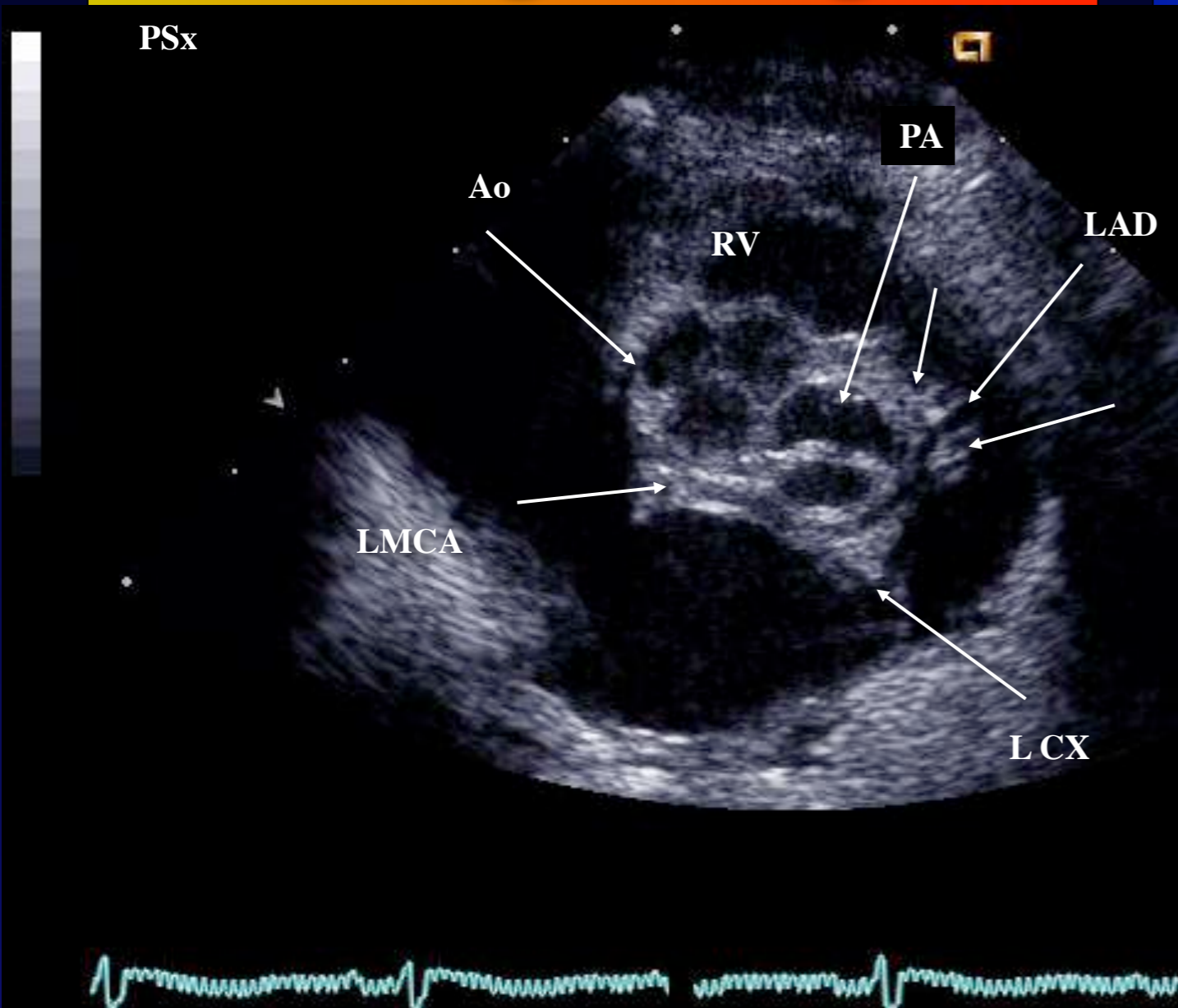
TGA : Normal Coronary Arteries



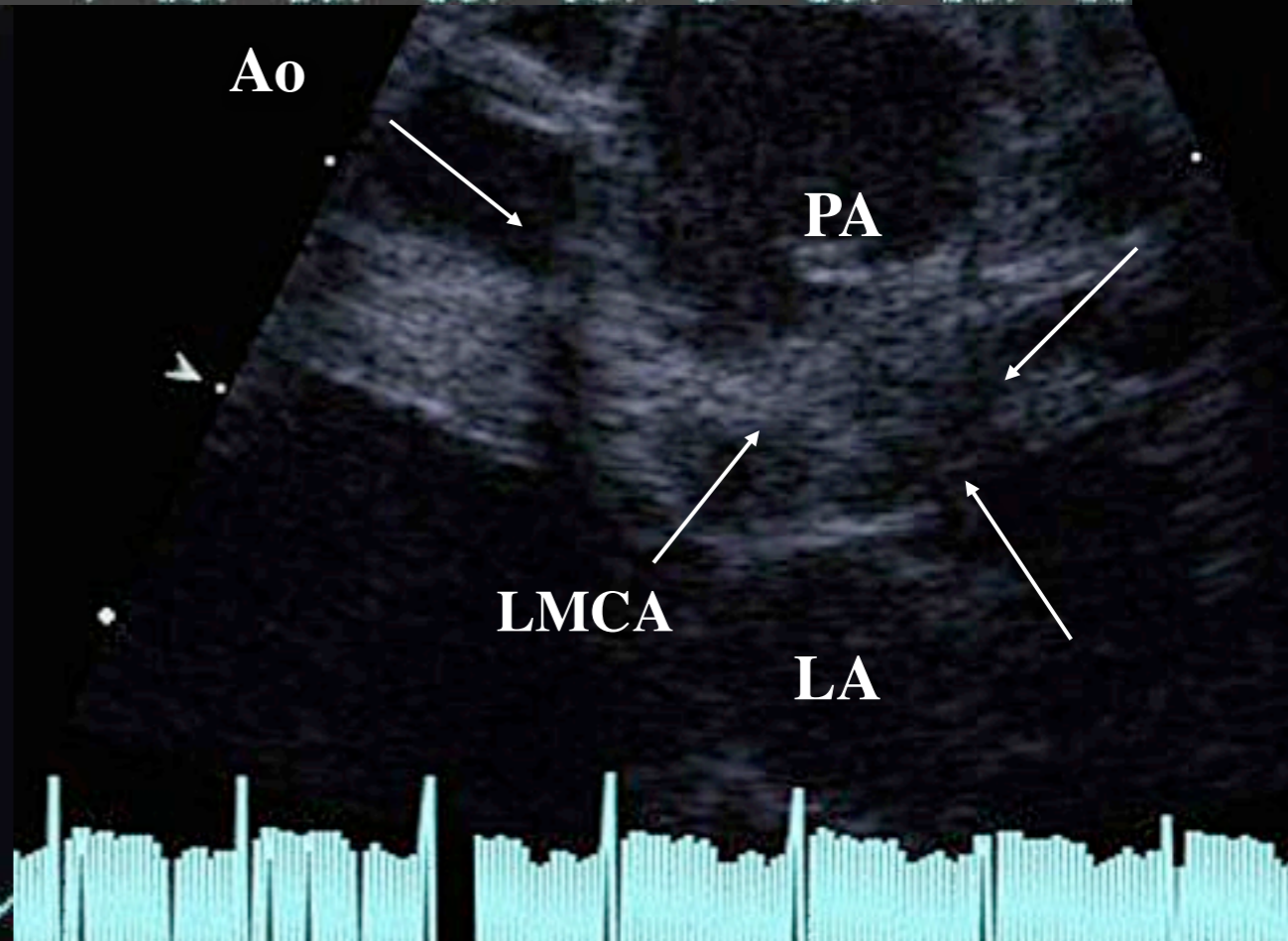
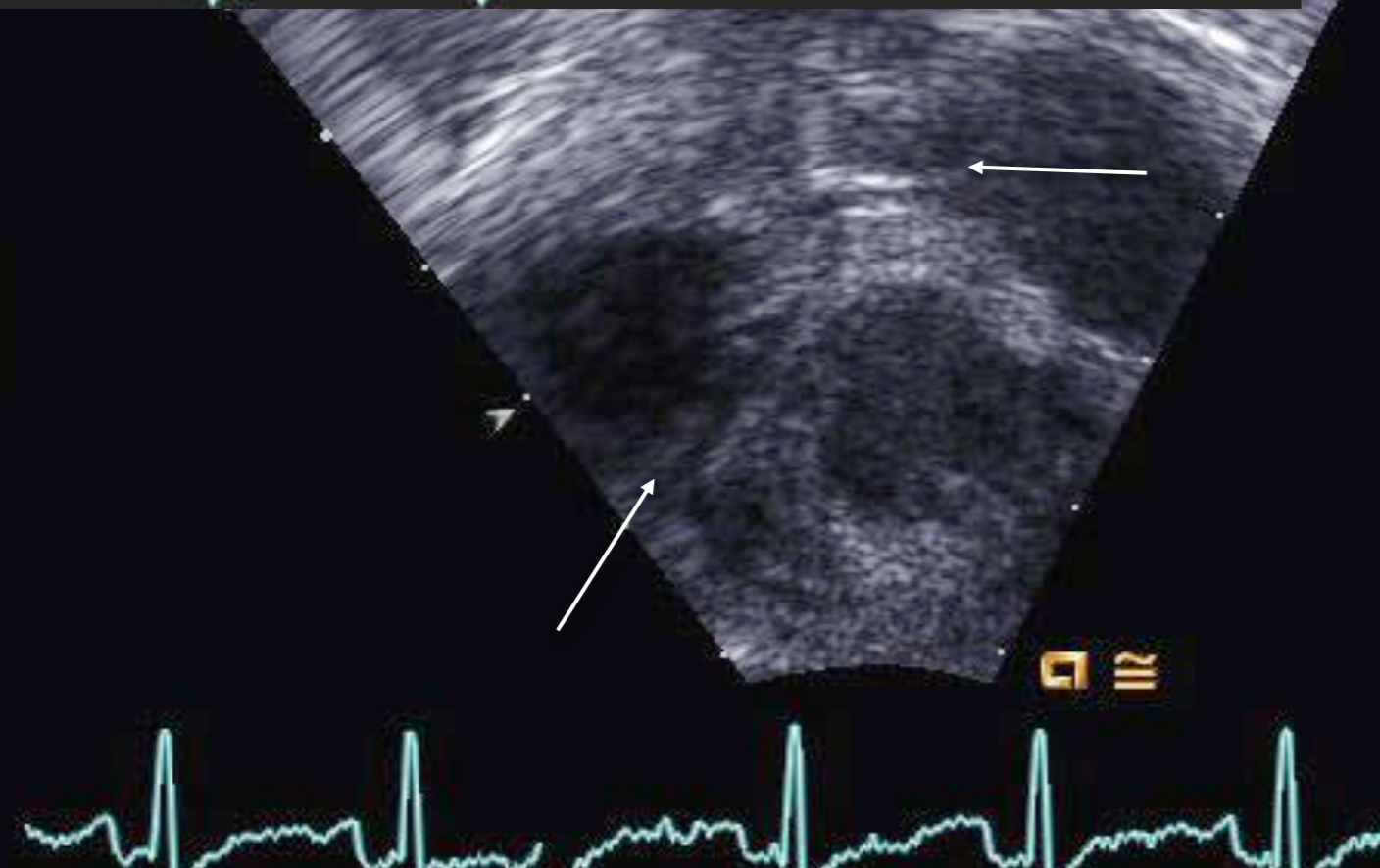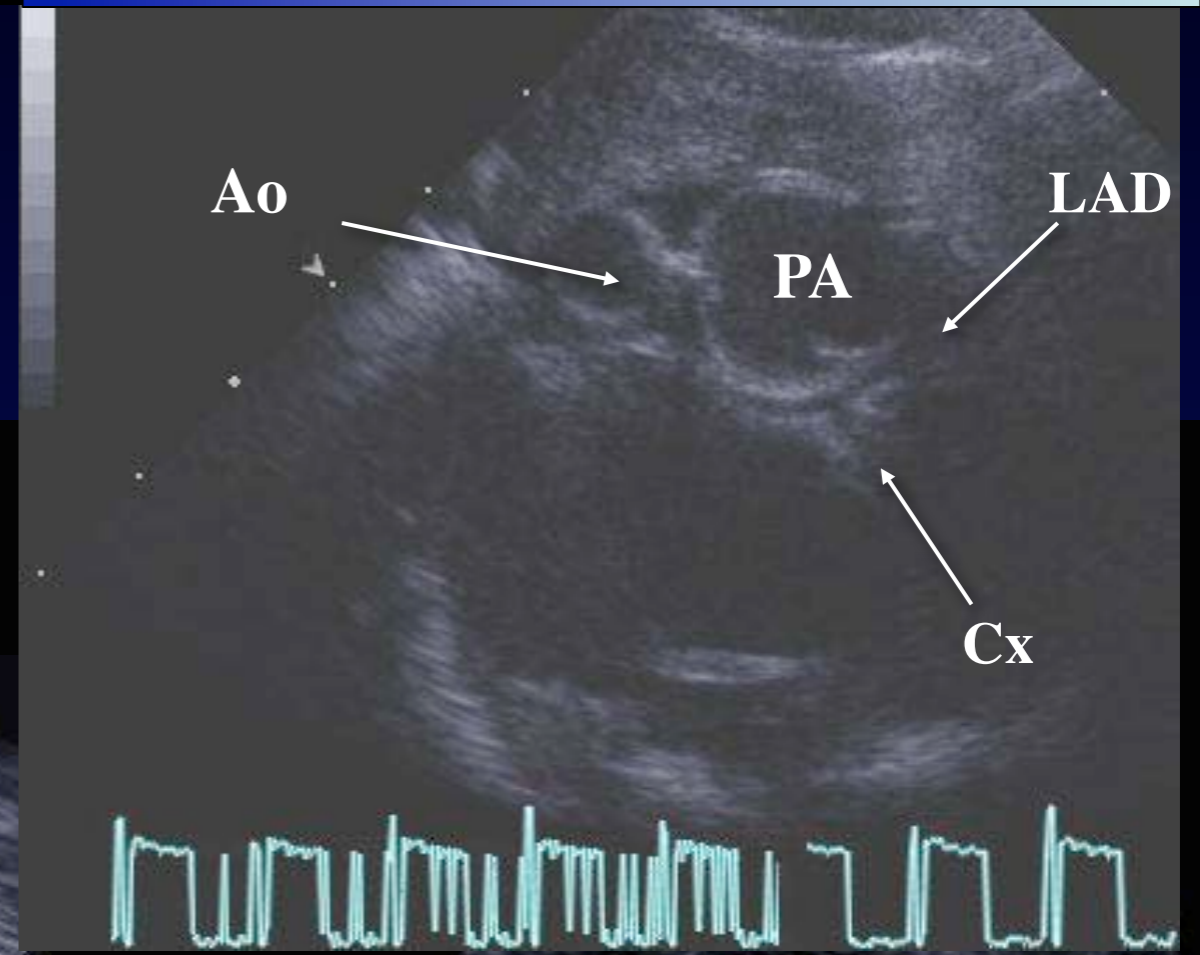
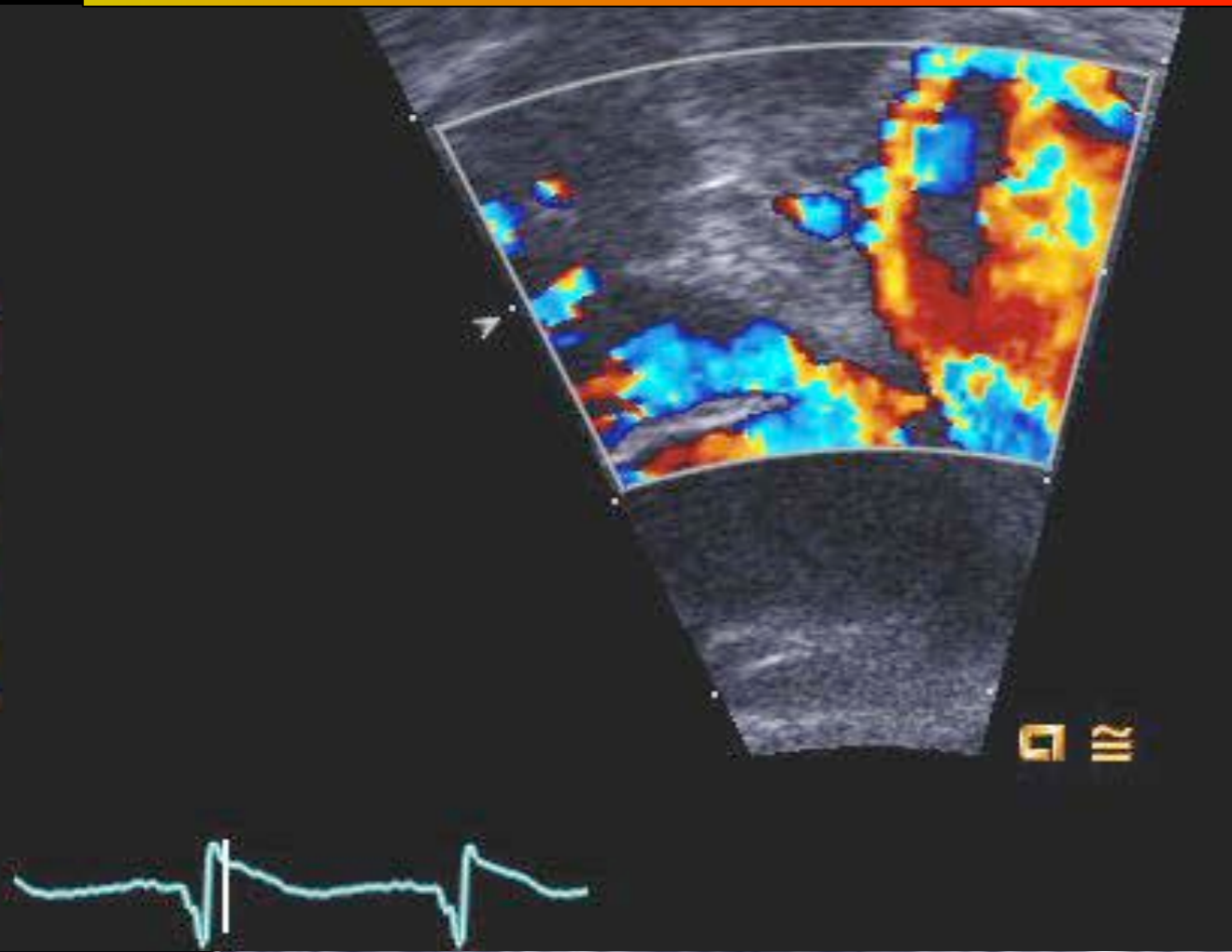
Right Coronary Artery Images



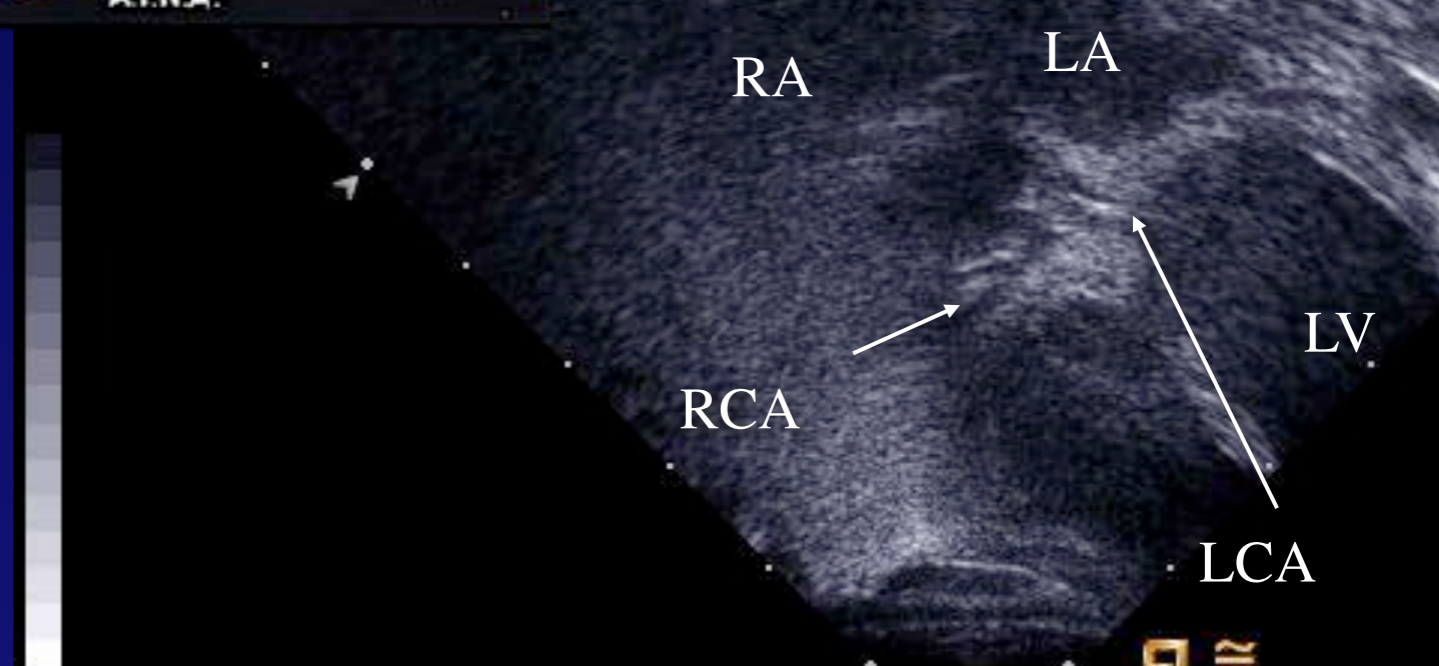
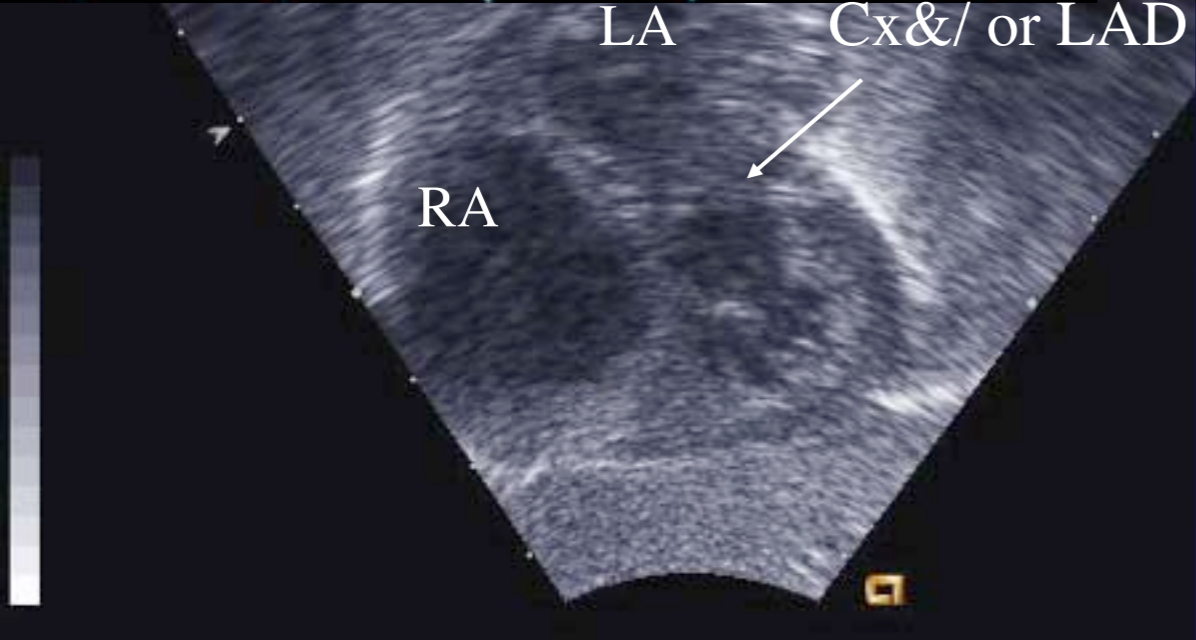
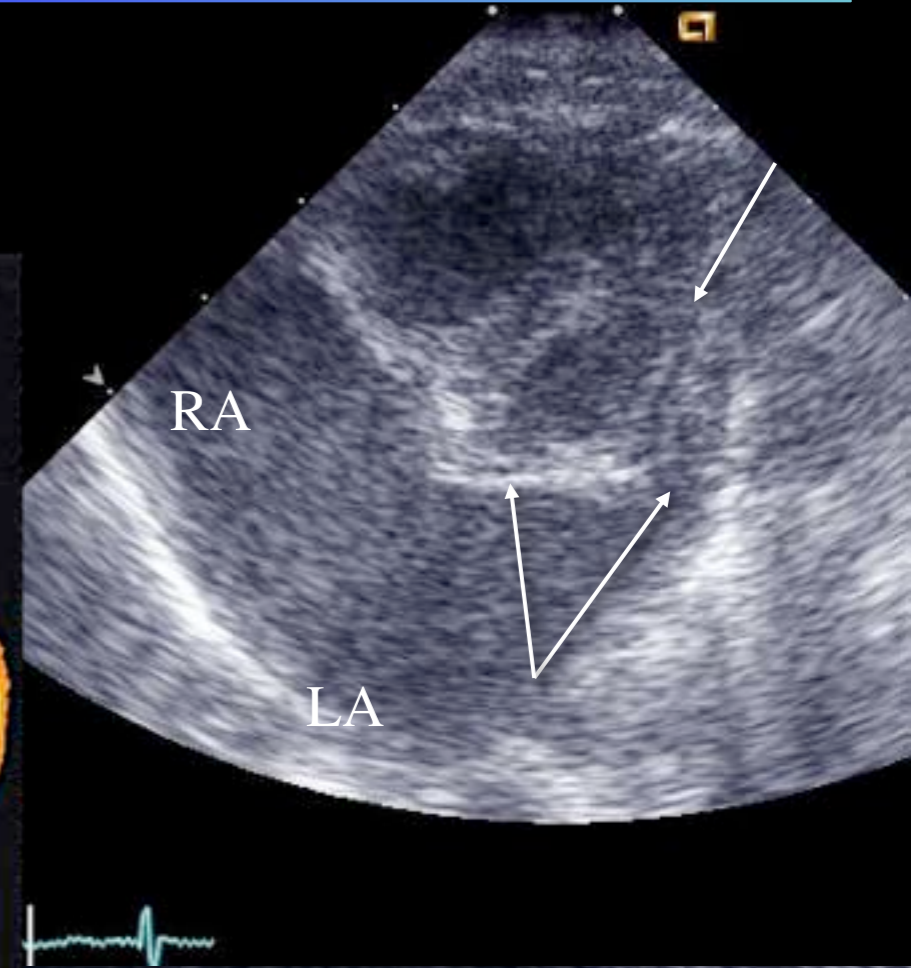
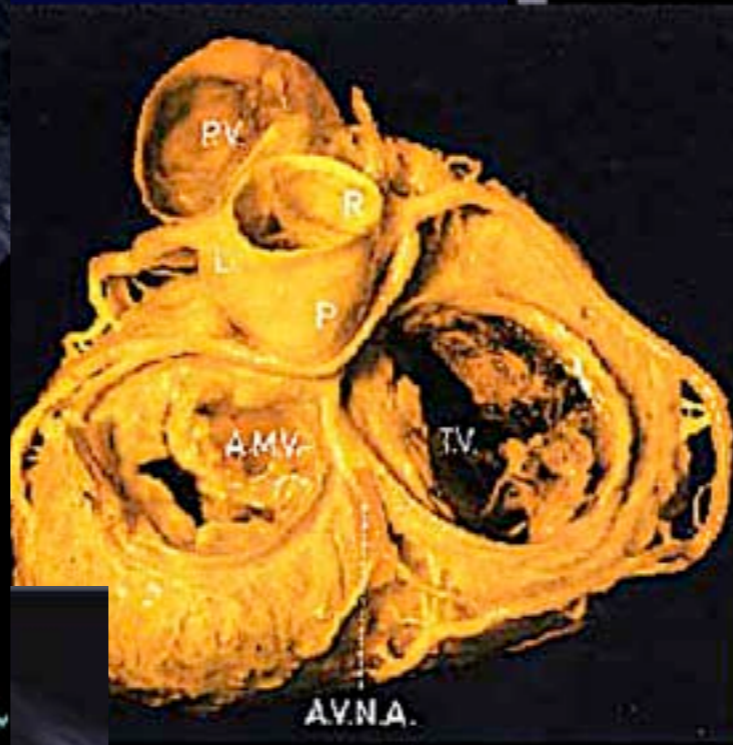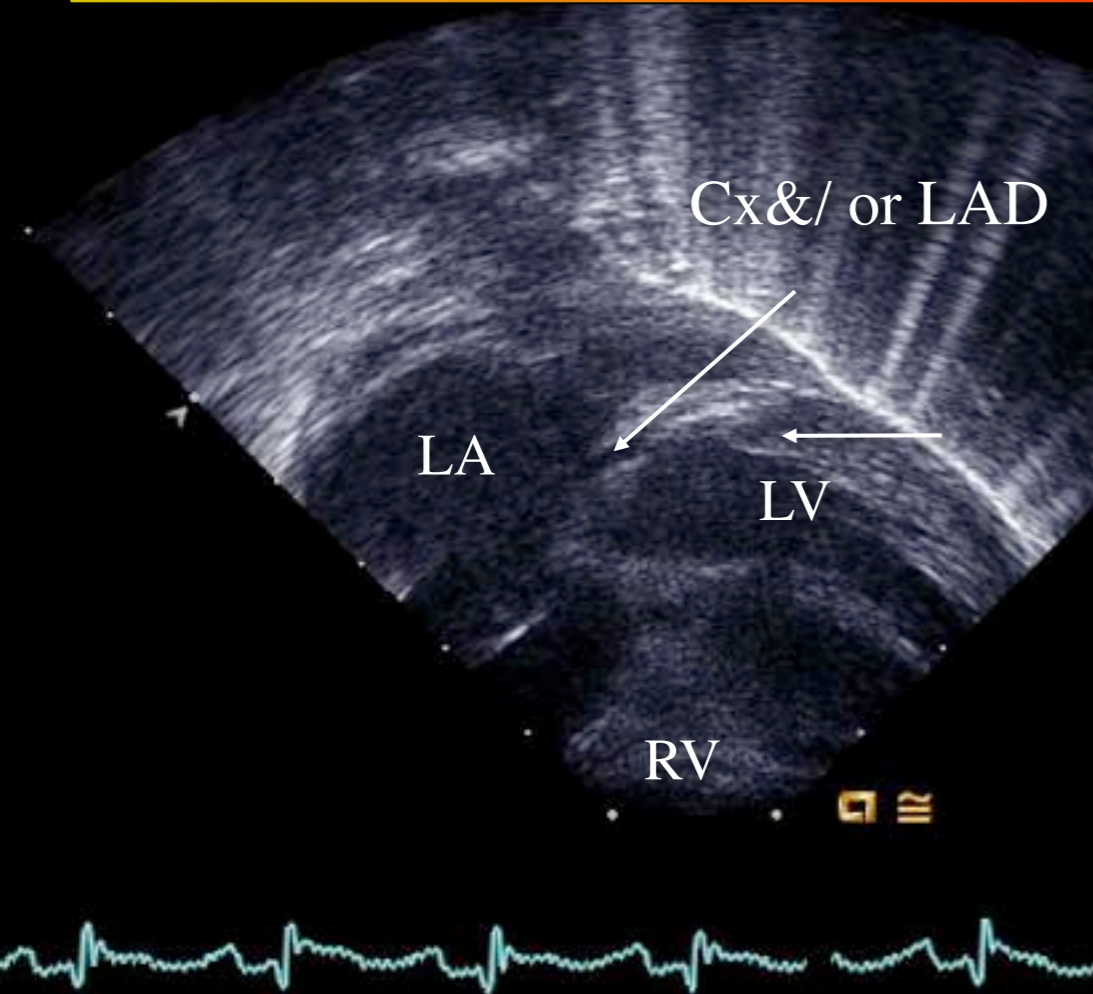
Single Right Coronary Artery



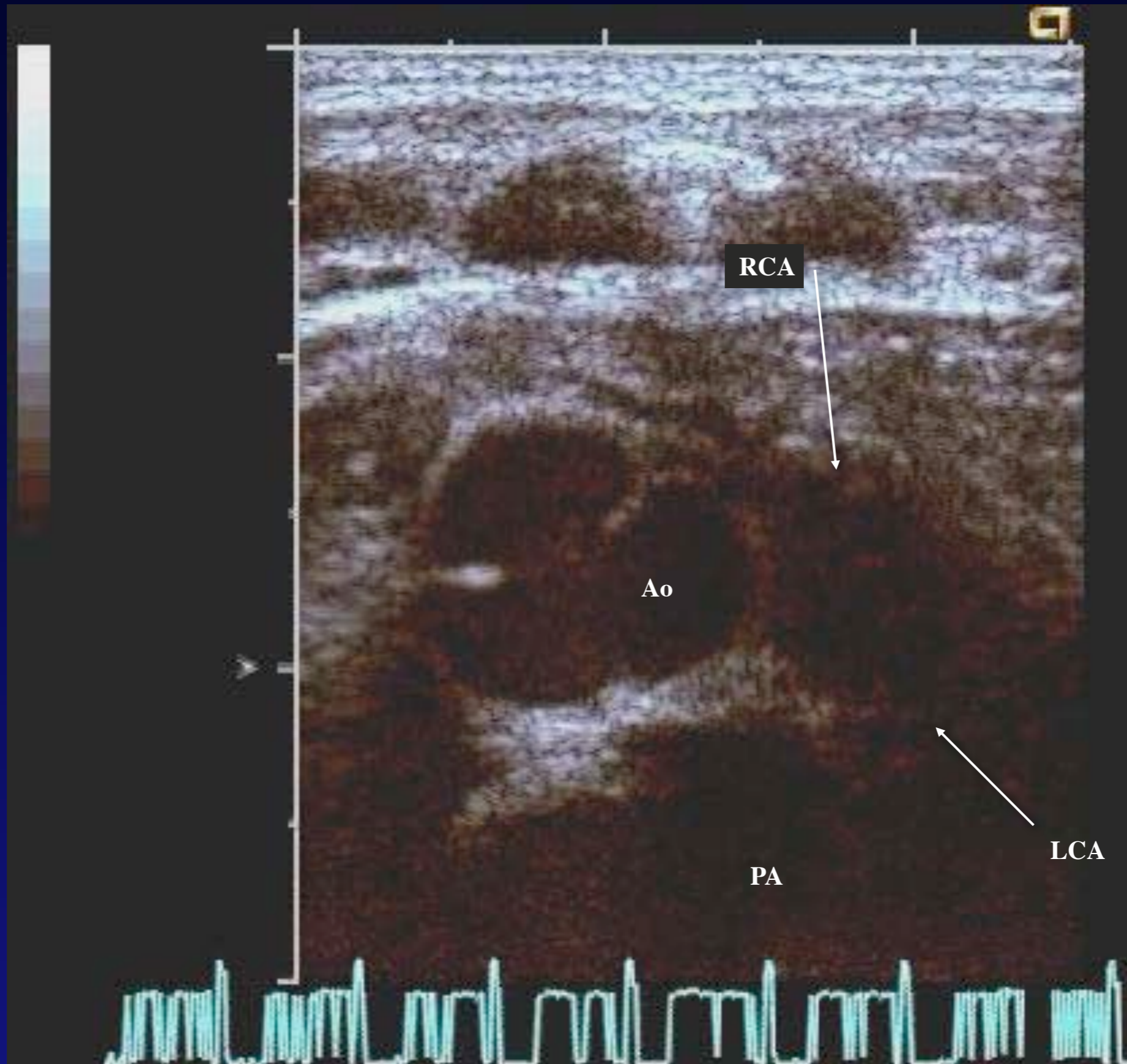
Single Right Coronary Artery



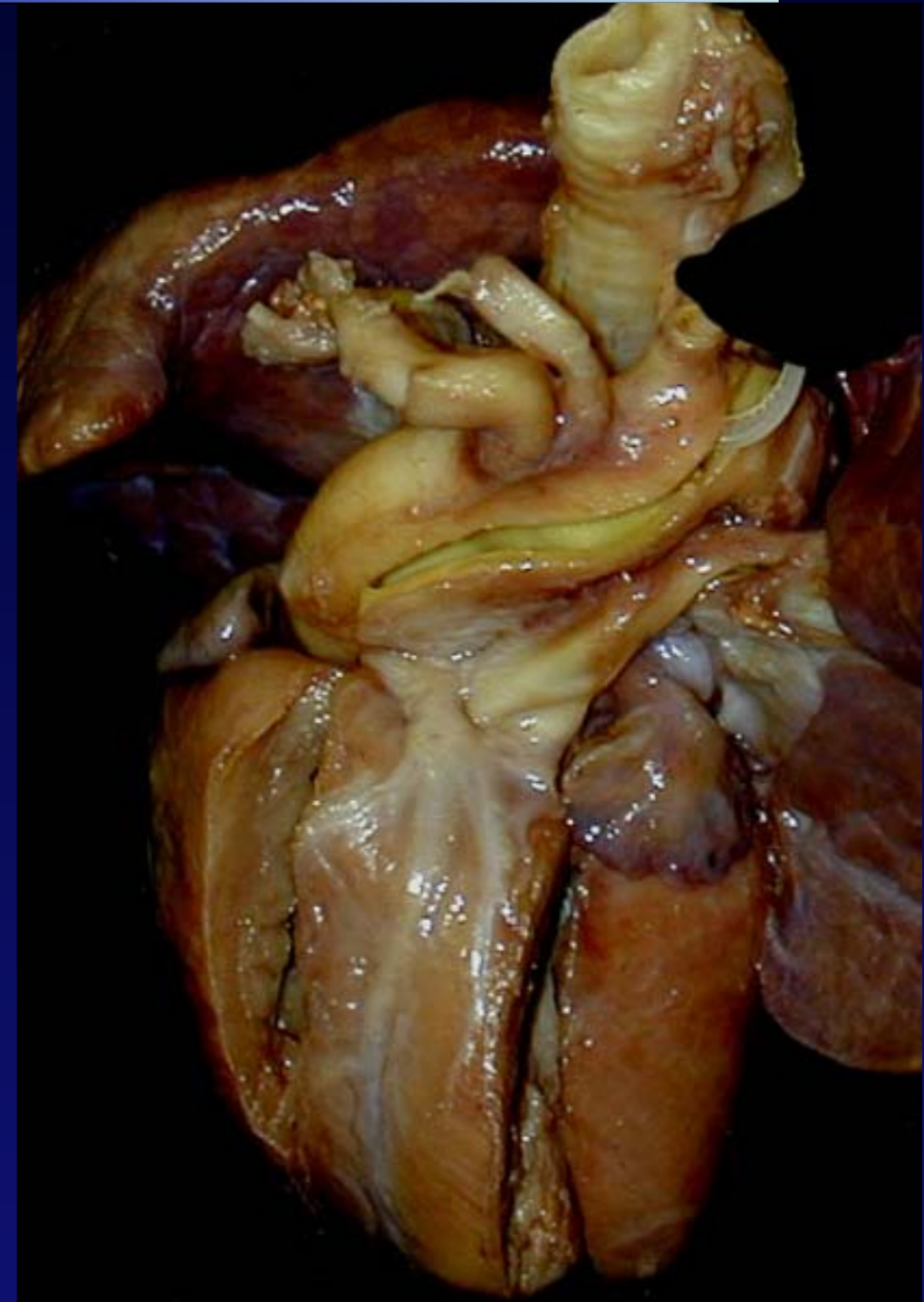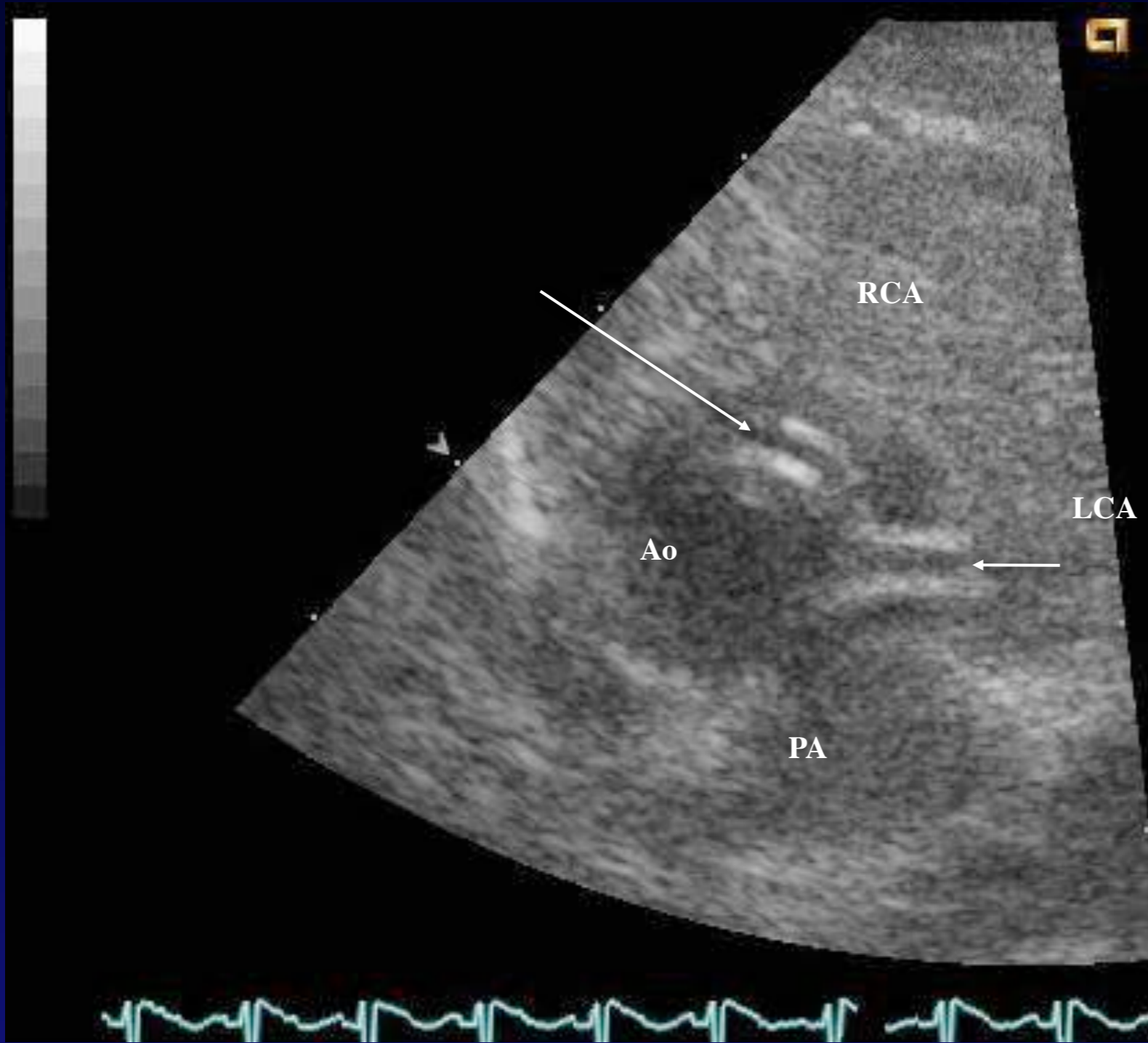Single Right Coronary Artery.



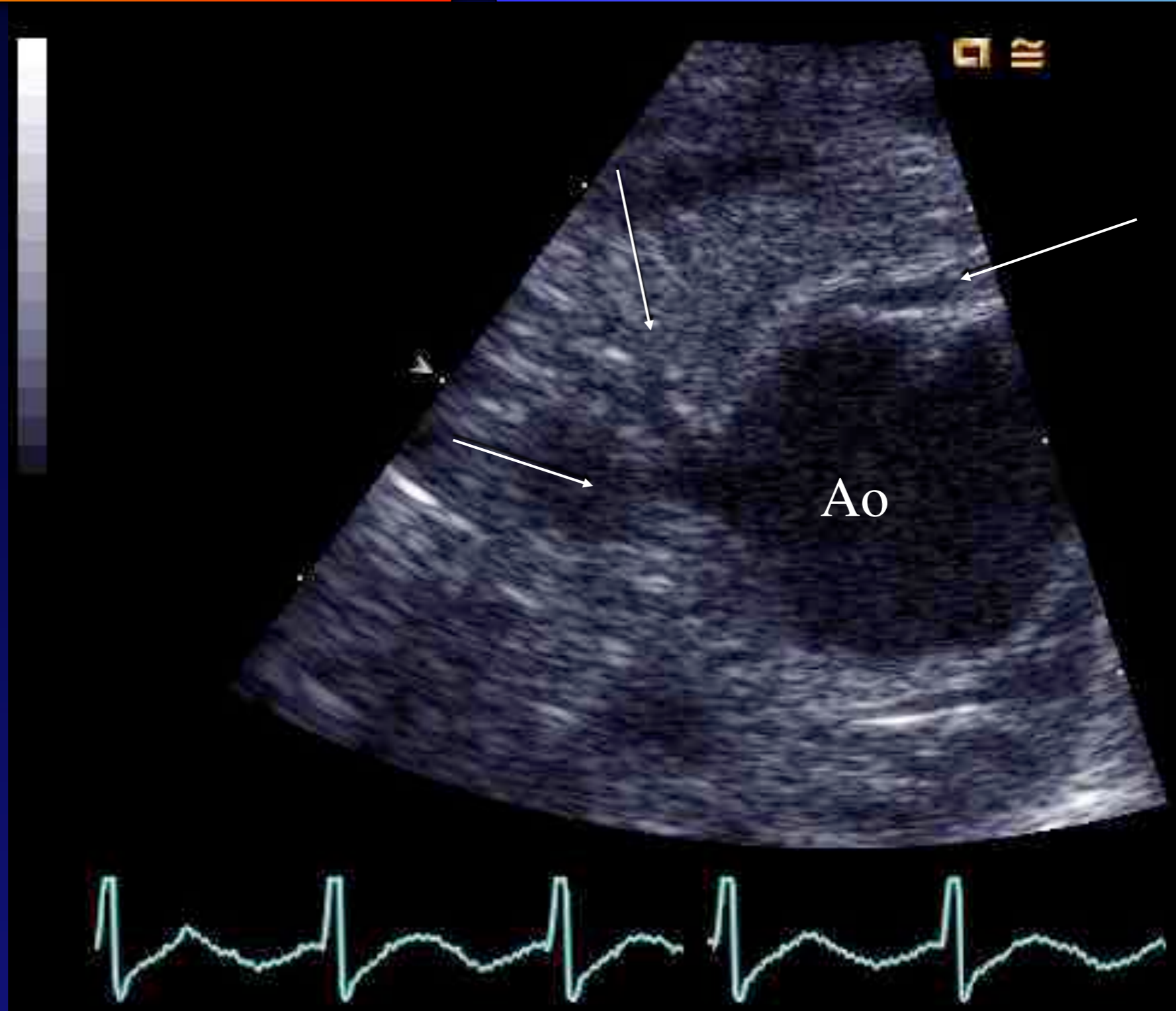
Looping Coronary Artery



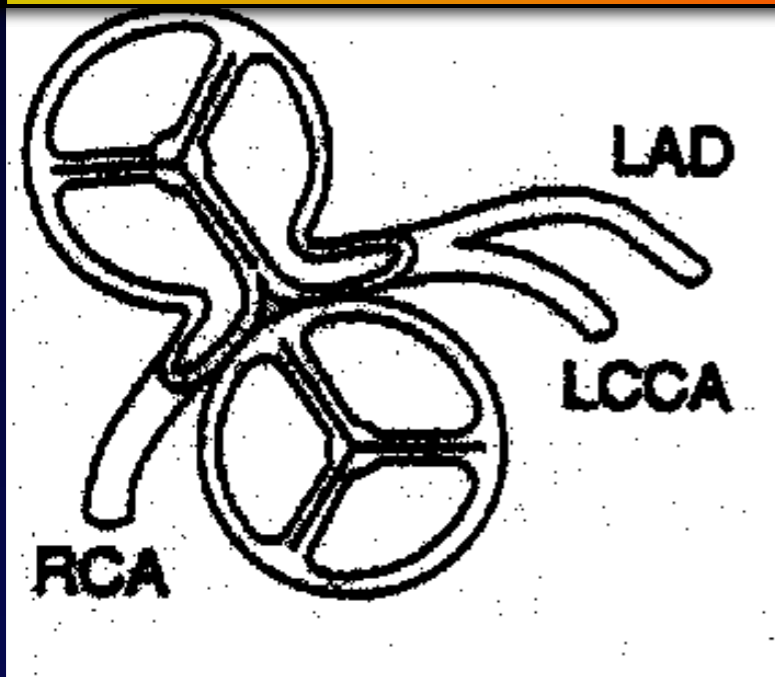
TGA: Single Left Coronary Artery



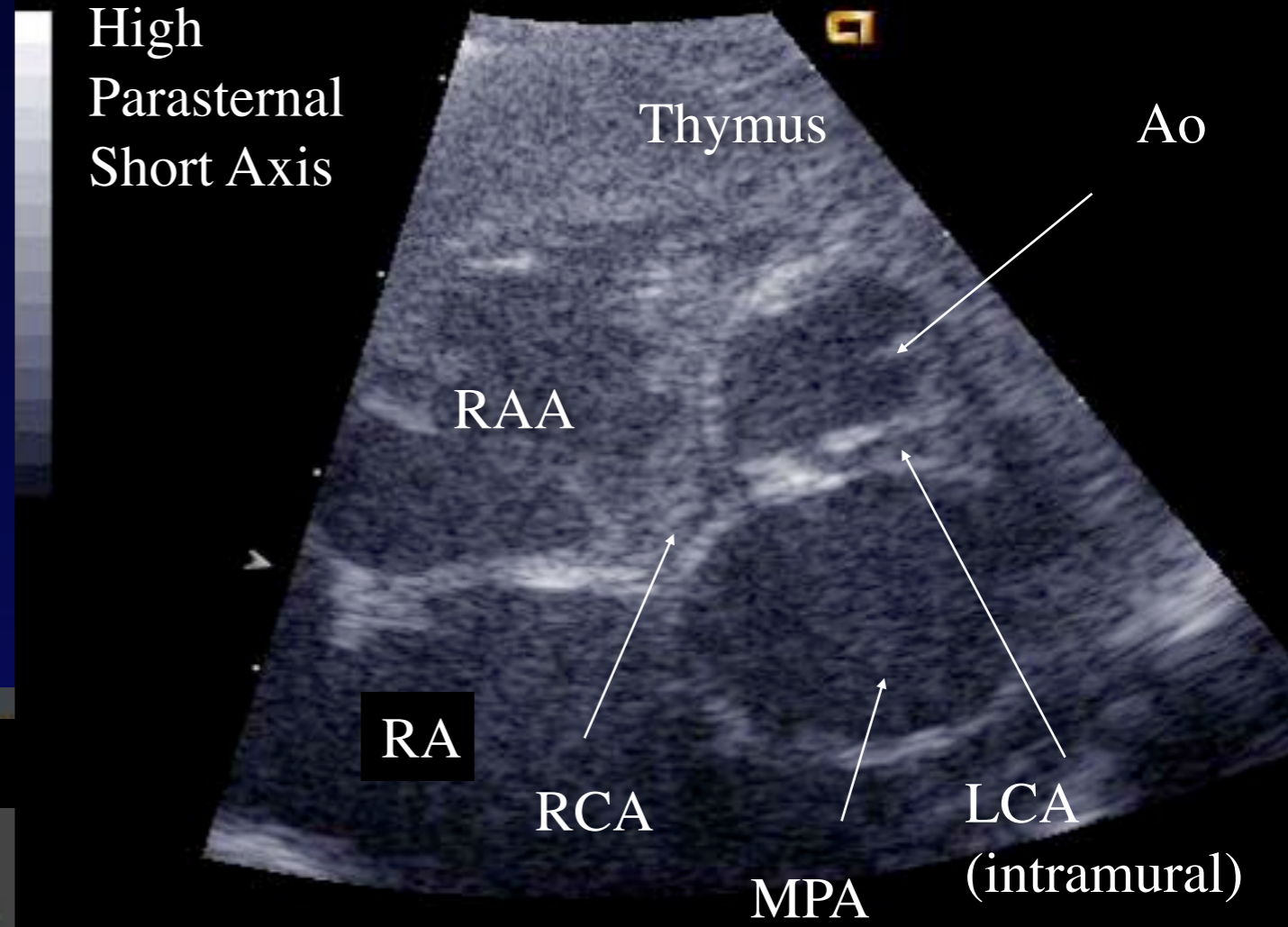
Single (Left) Coronary Artery in l-TGA



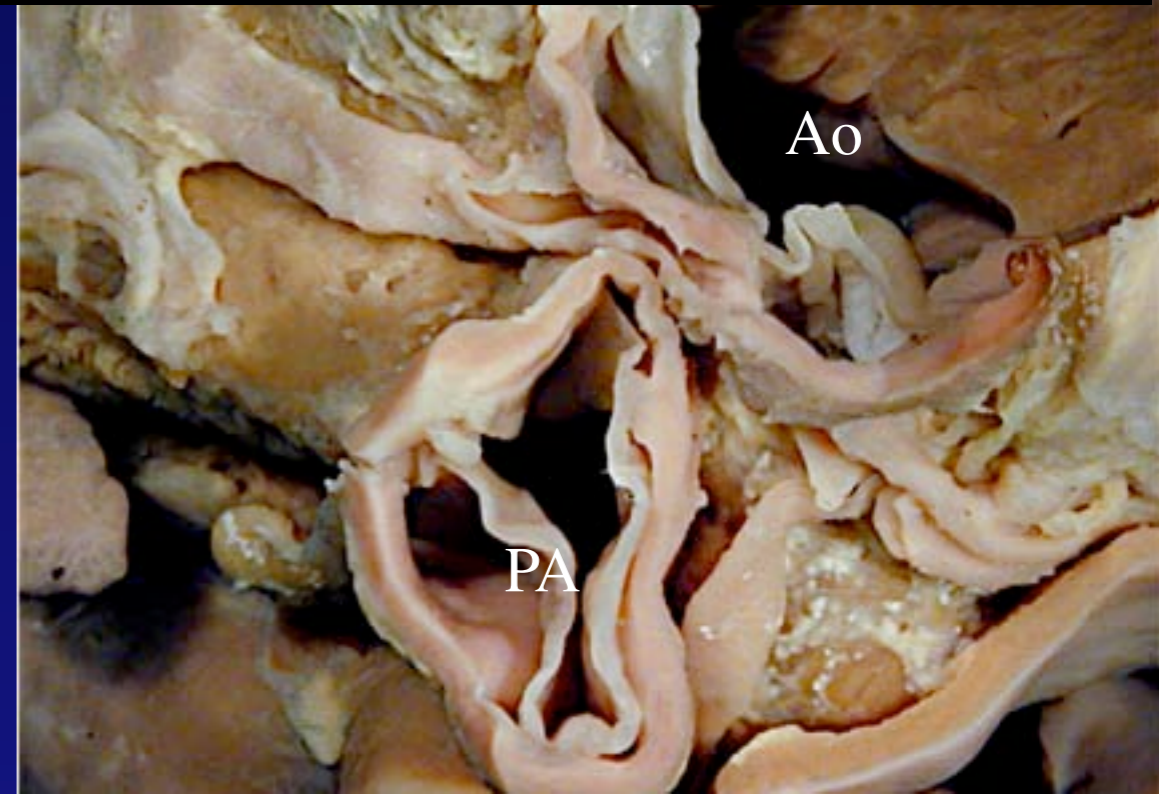
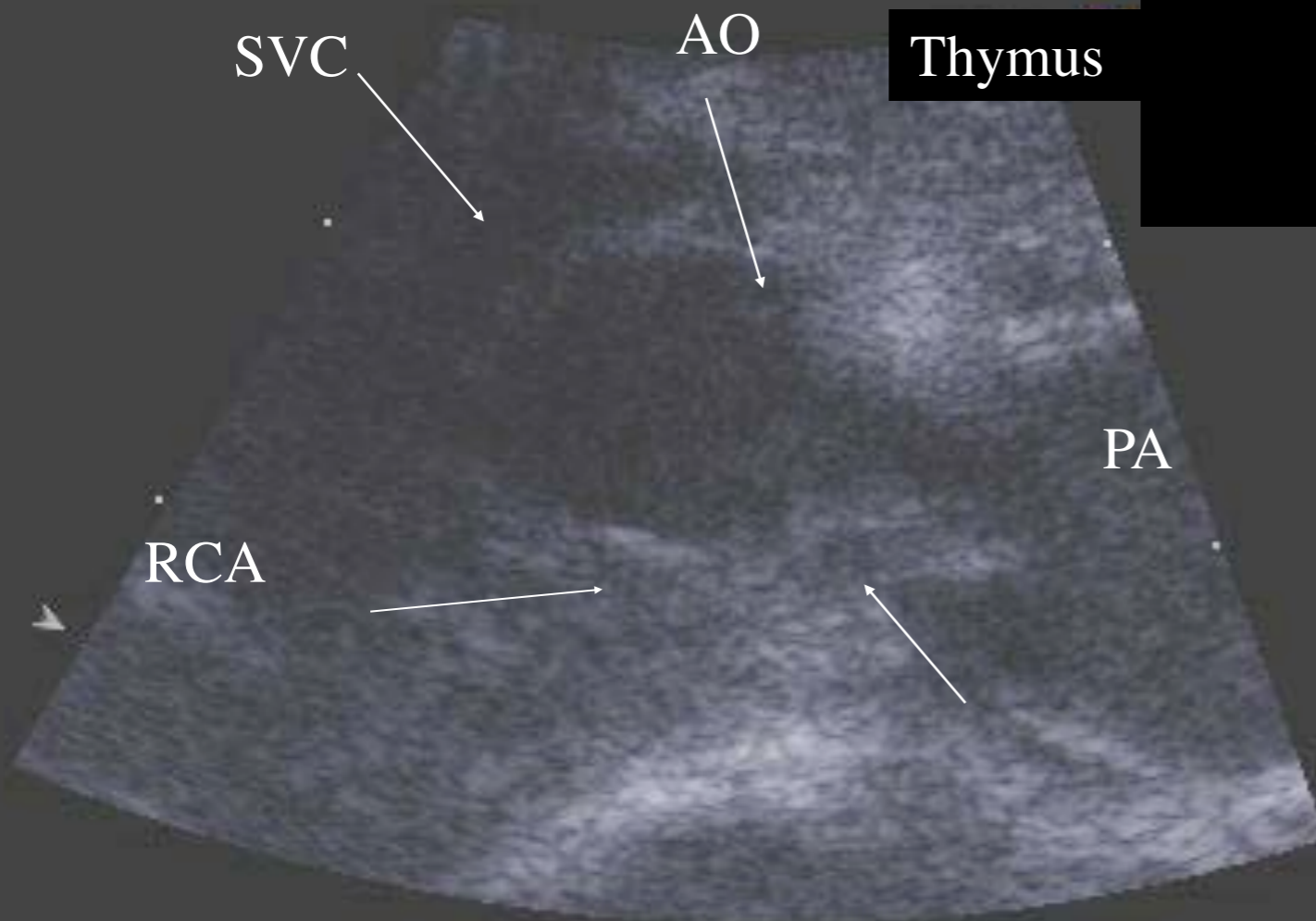
Intramural Coronary Artery



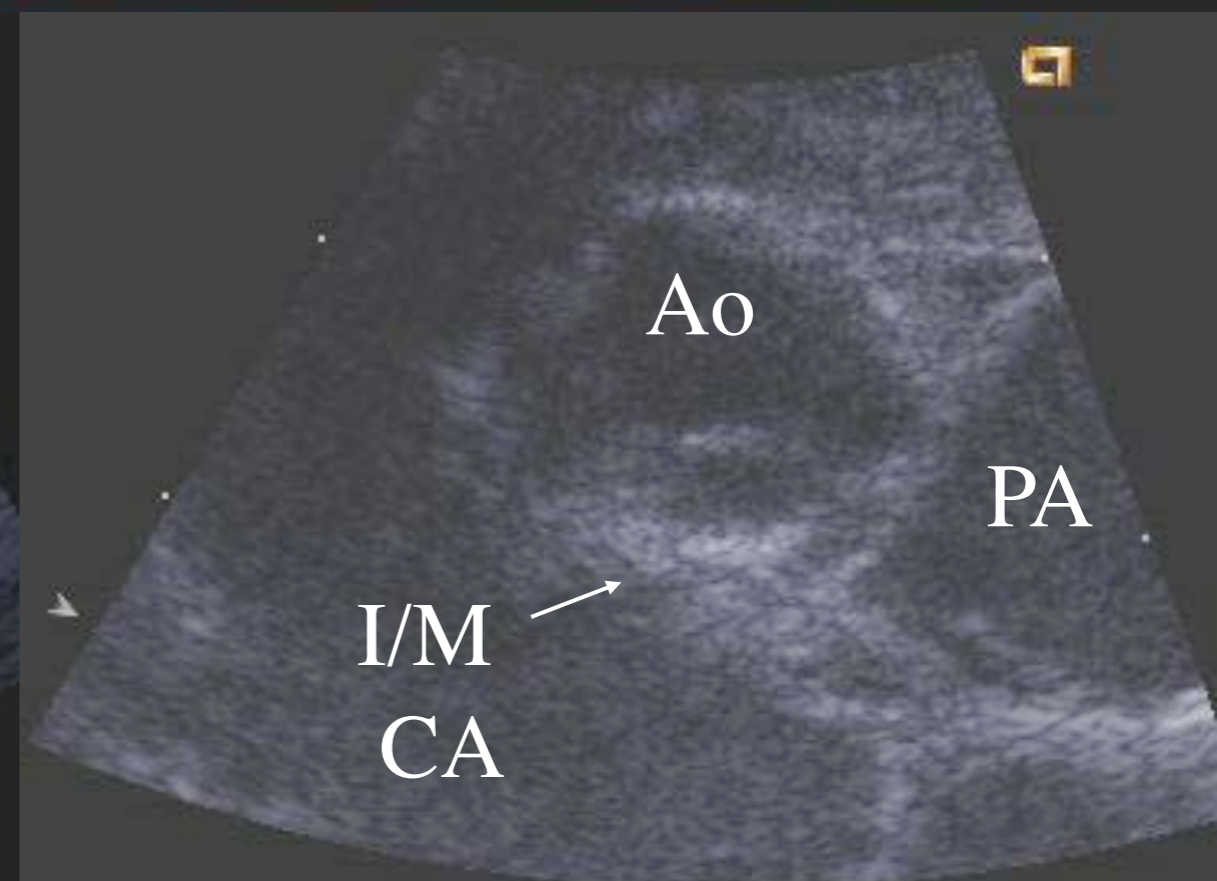
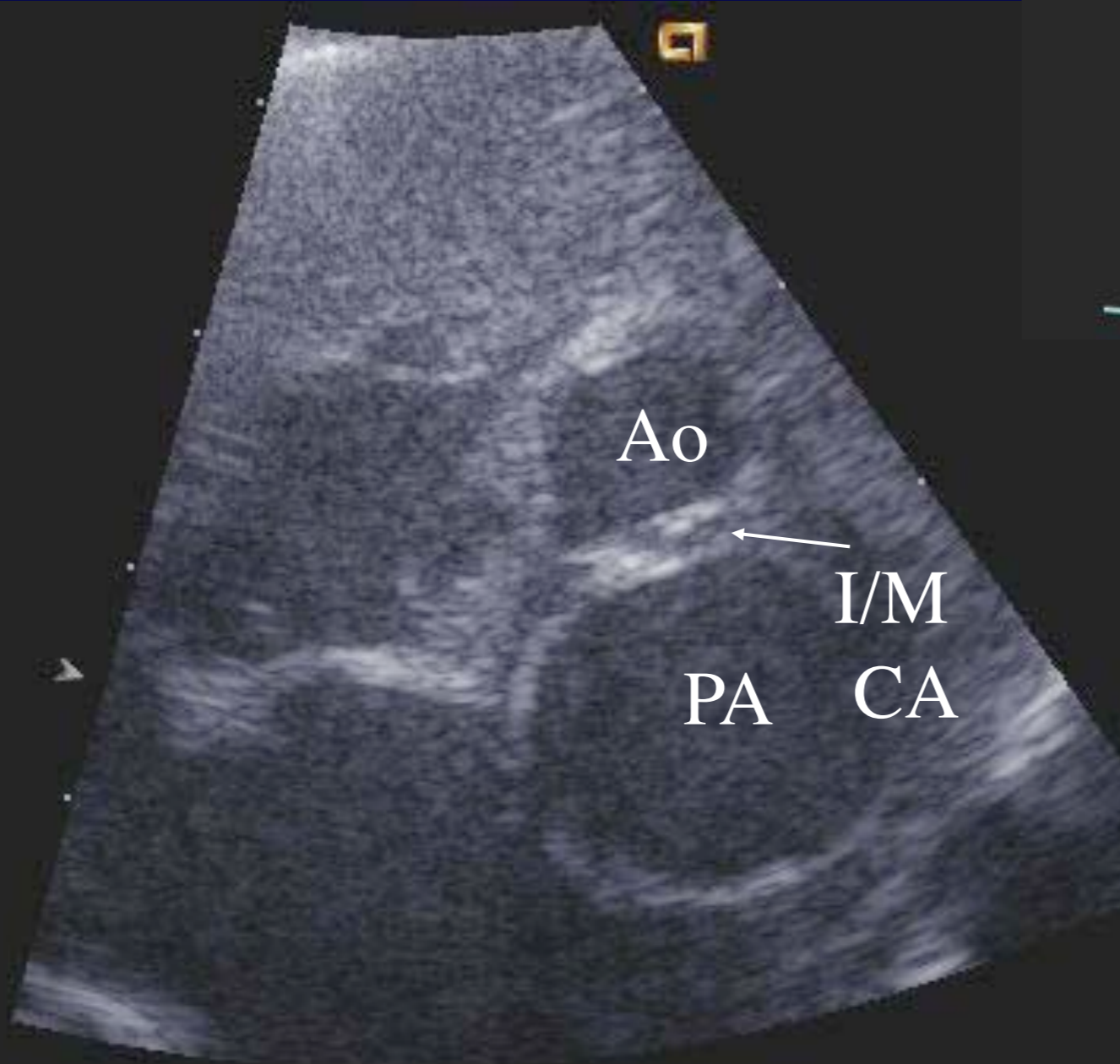
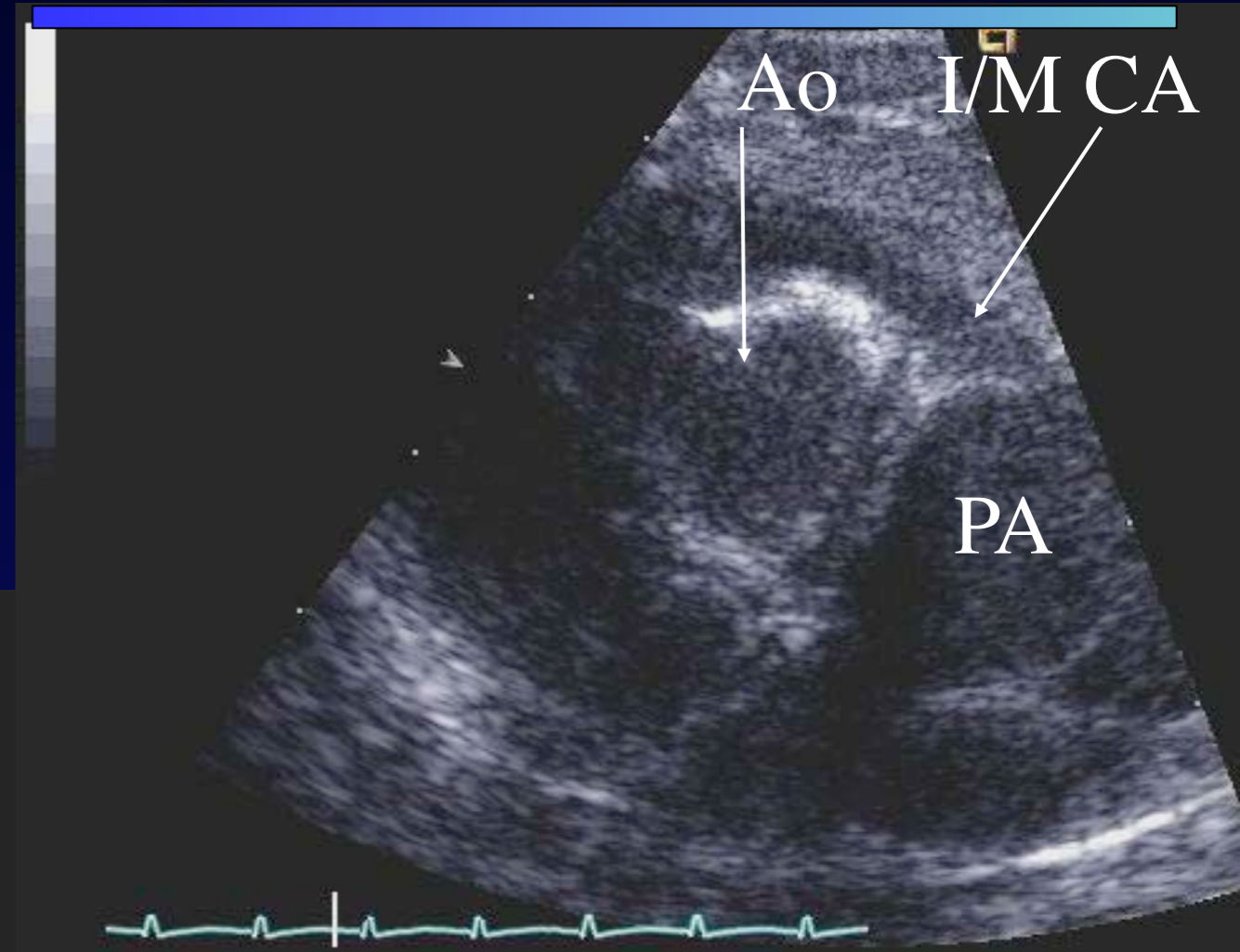
High Parasternal Short Axis



High Parasternal Short Axis



Intramural Coronary Artery in Transposition.



Intramural Coronary Arteries

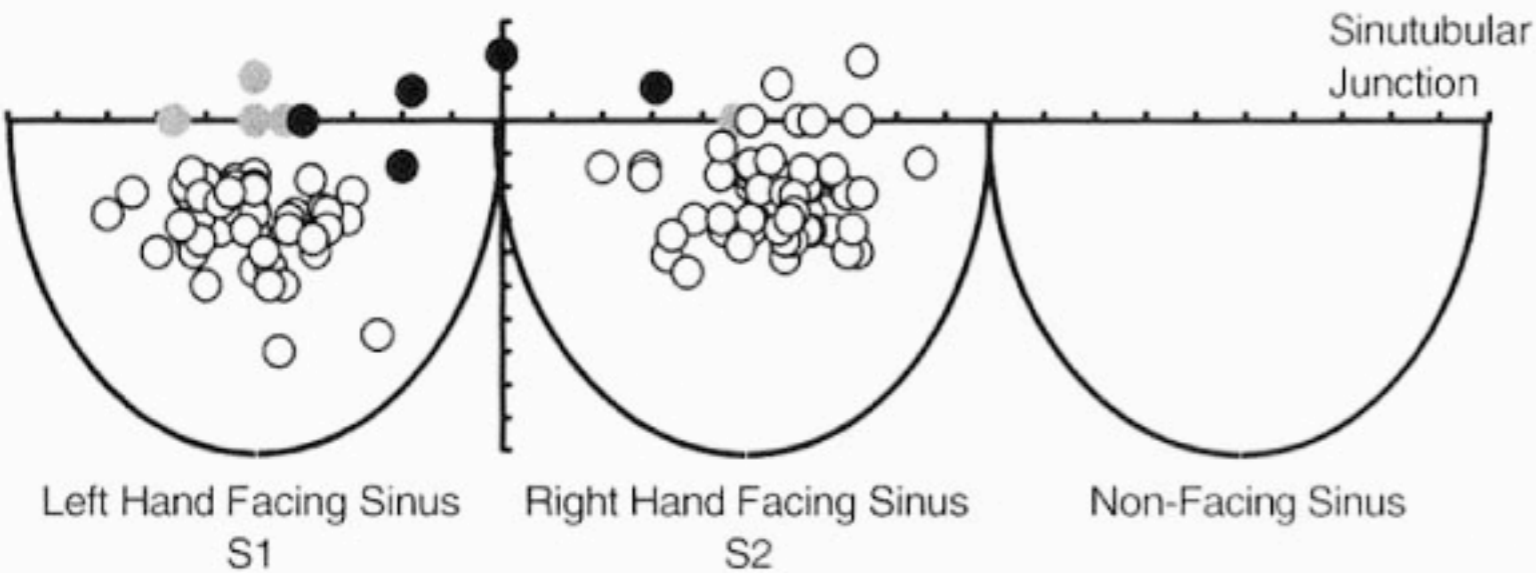


Figure 2.
Relation between the position of the coronary artery within the aortic sinus and the presence of intramural course as described by Li and associates.⁷ The open circles are normal angles of exit, the closed circles are intramural coronary arteries, and the opaque circles show tangential take-off of the coronary arteries.

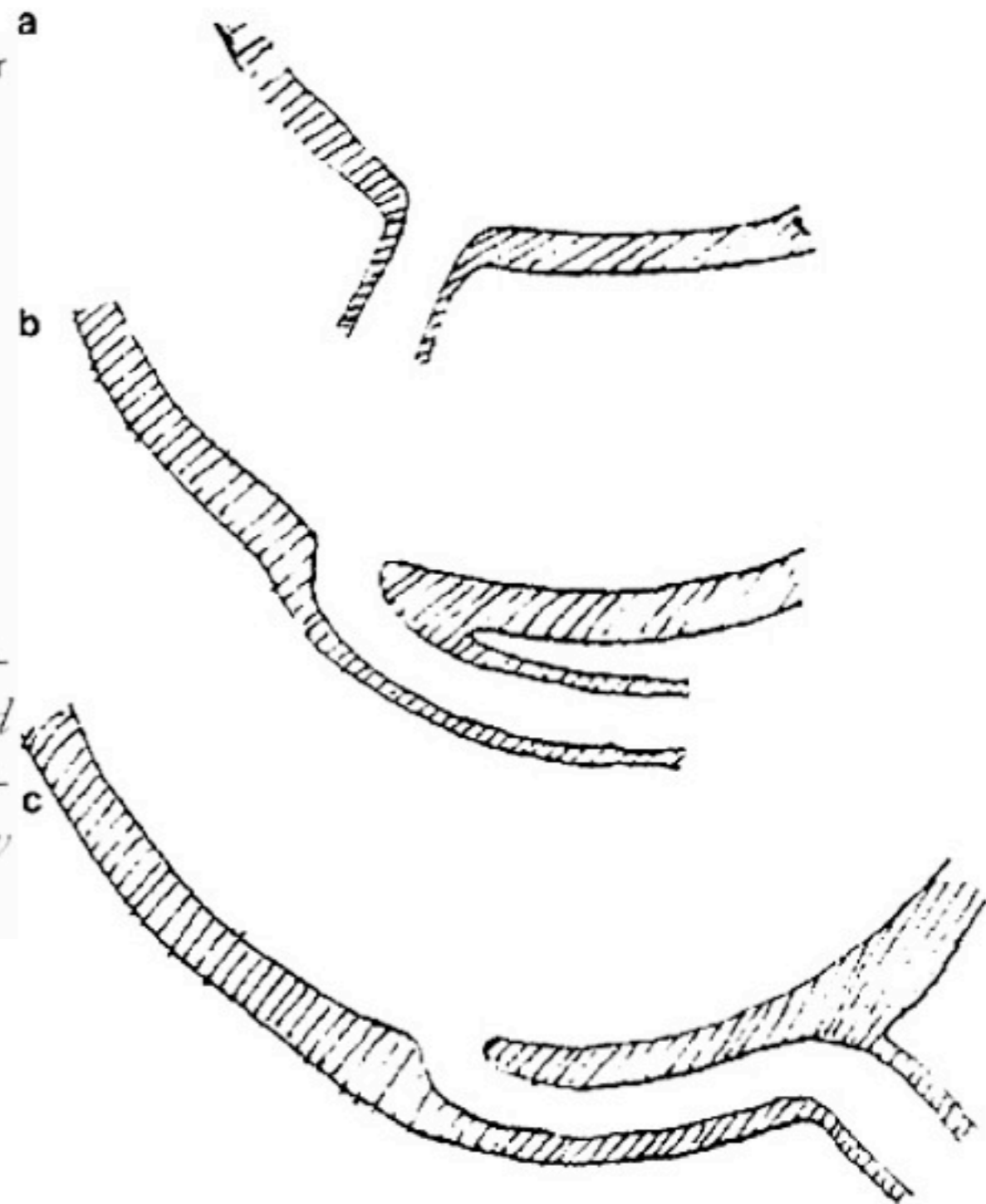
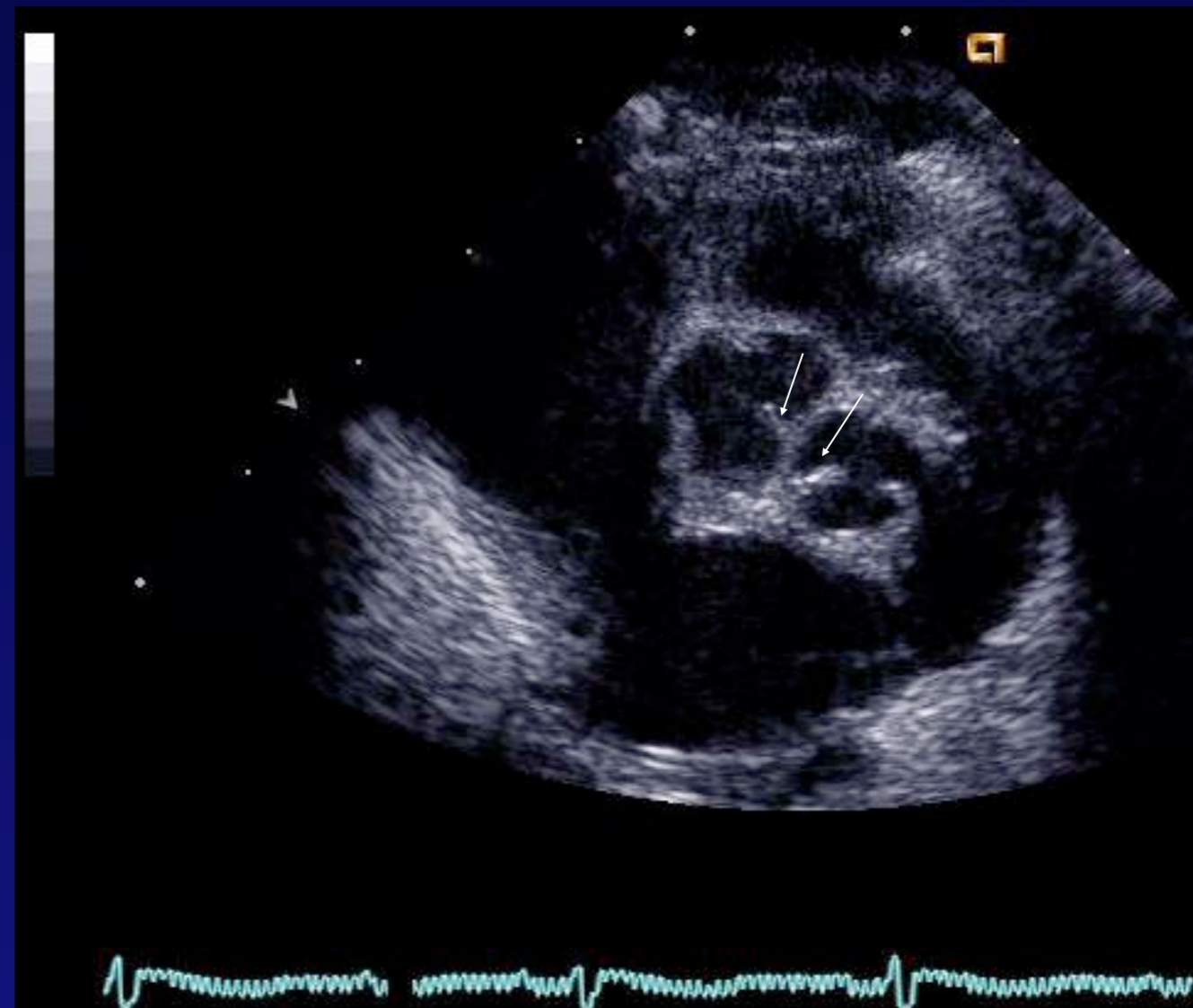
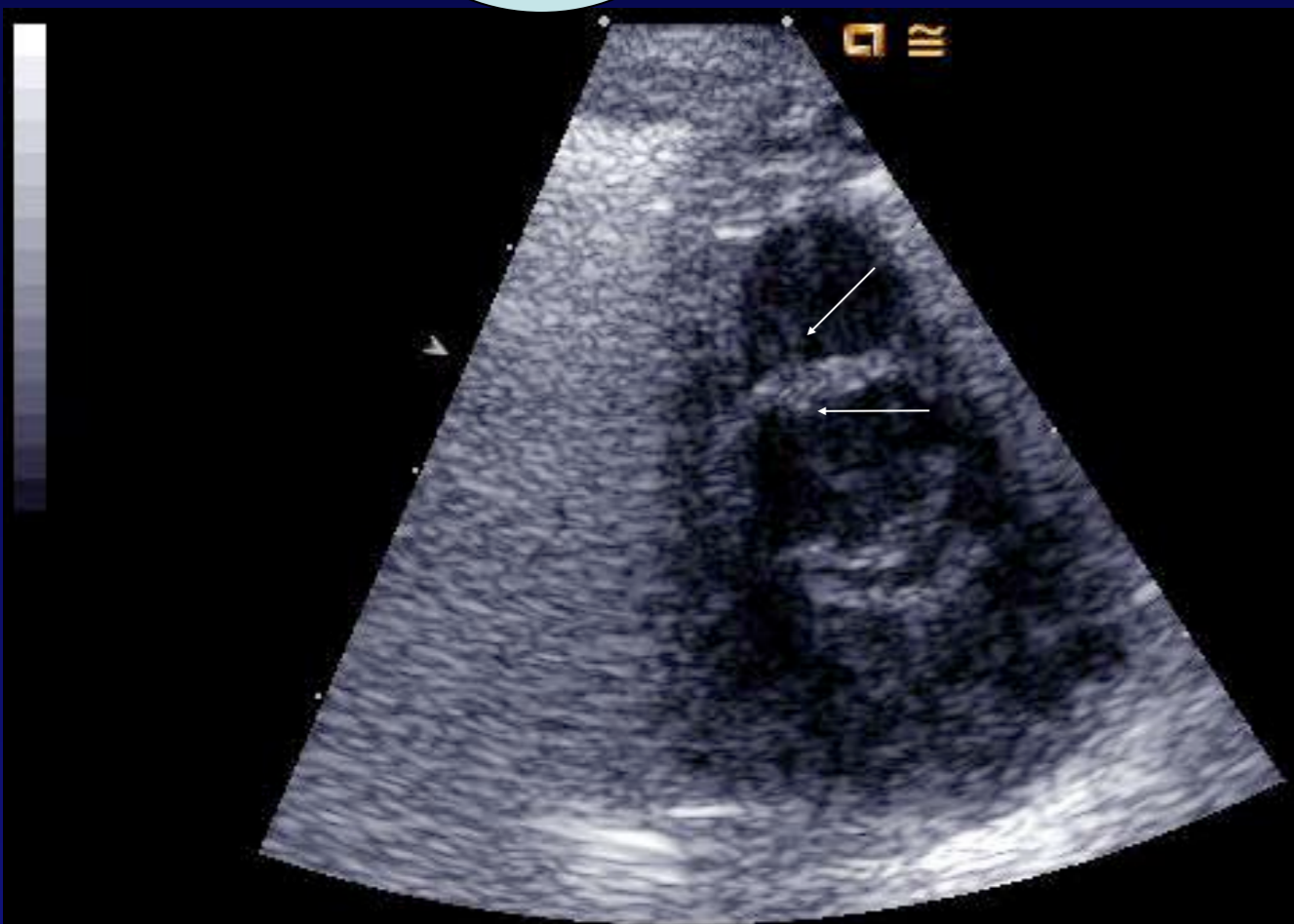




Figure 3.
The angle of origin of coronary arteries, as shown here, is based on the principles of Angelini.⁸ Take-off can be orthogonal (a), tangential (b) or intramural (c). There is greatest chance of a high take-off or intramural origin when the artery arises close to the commissure.

Great Vessel Cusp Malalignment.



Sinotubular Origin of LCA

RCA

Ao

LCA

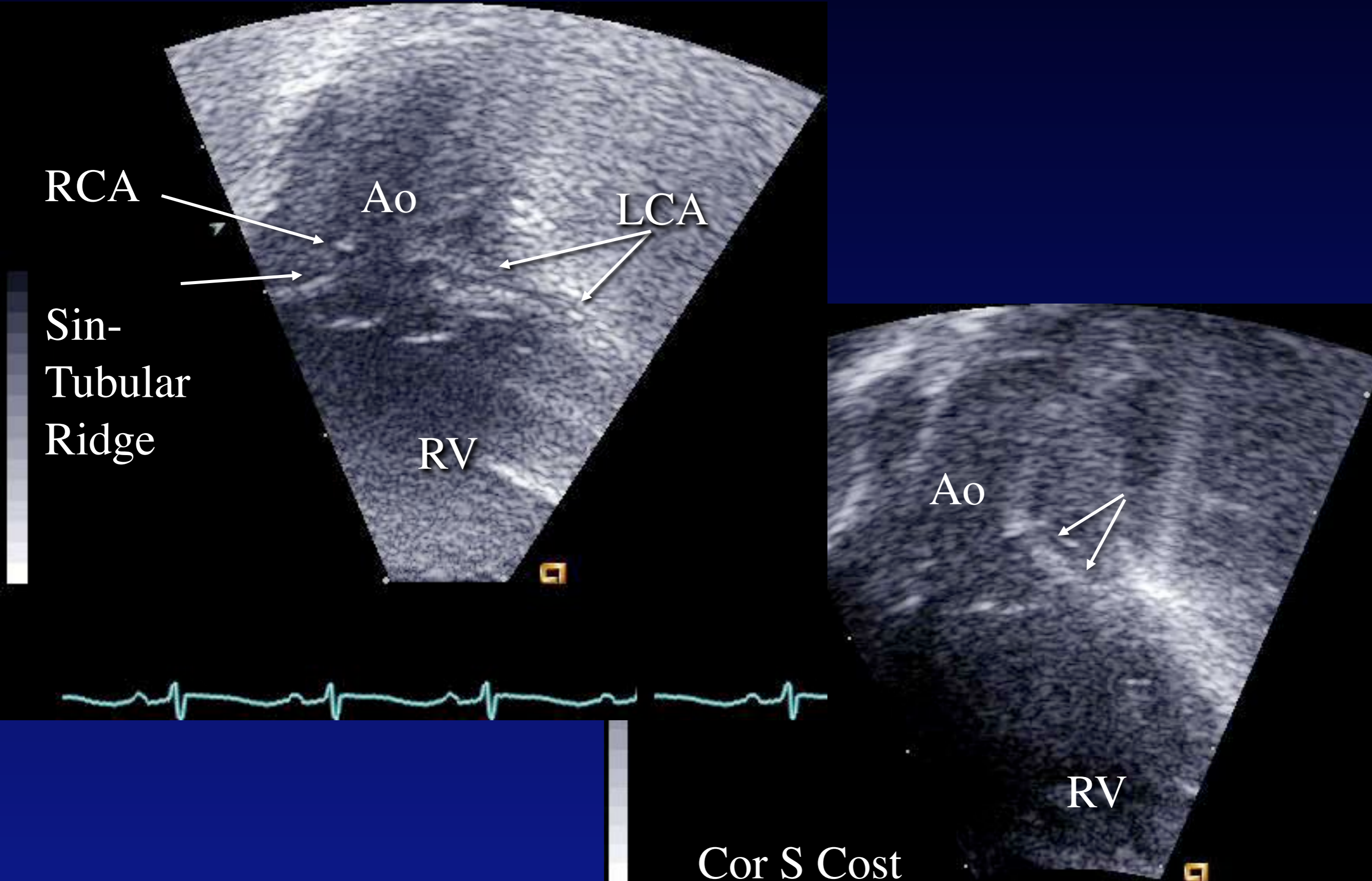
Sin-
Tubular
Ridge

RV

Ao

RV

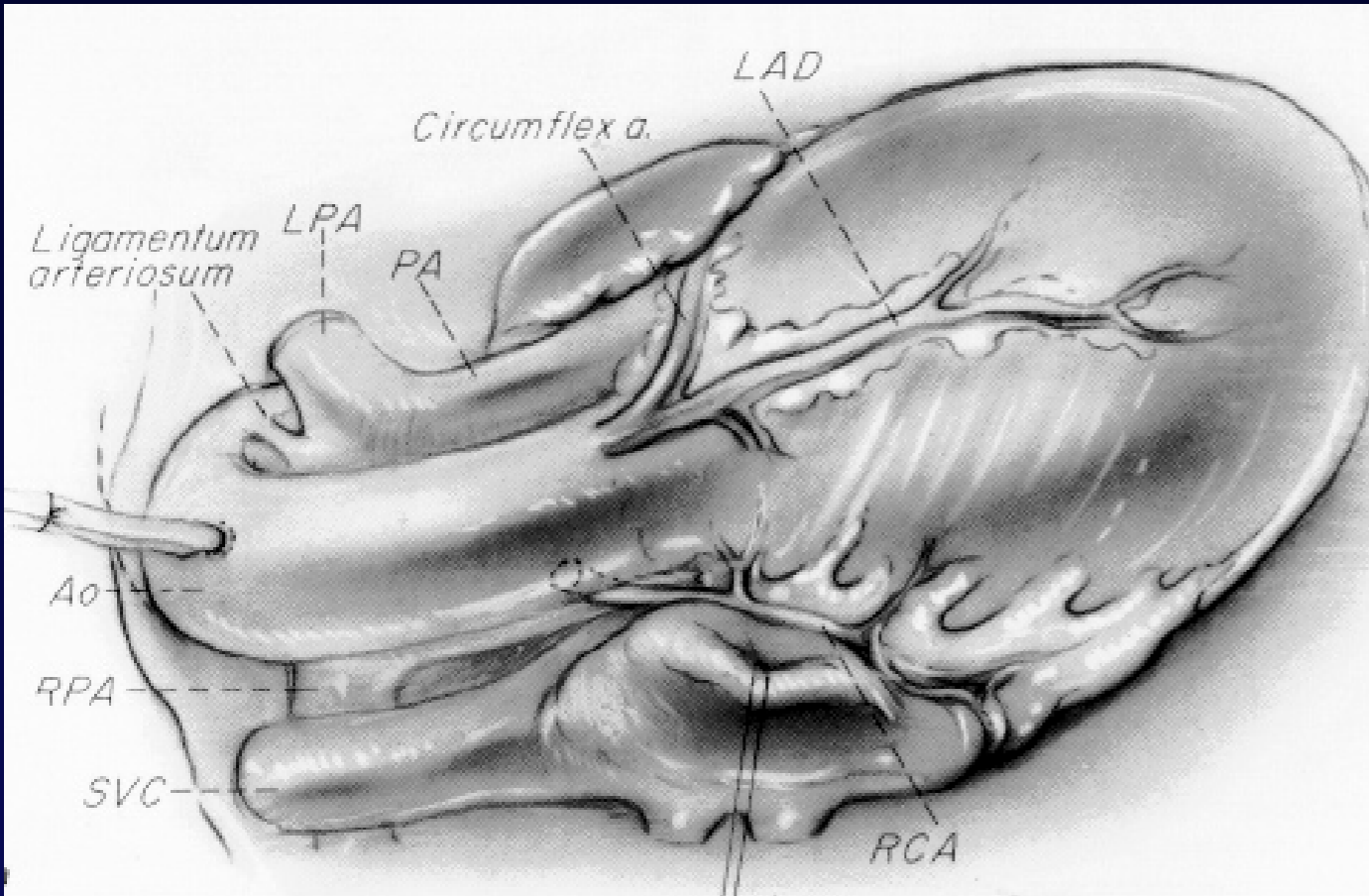
Cor S Cost



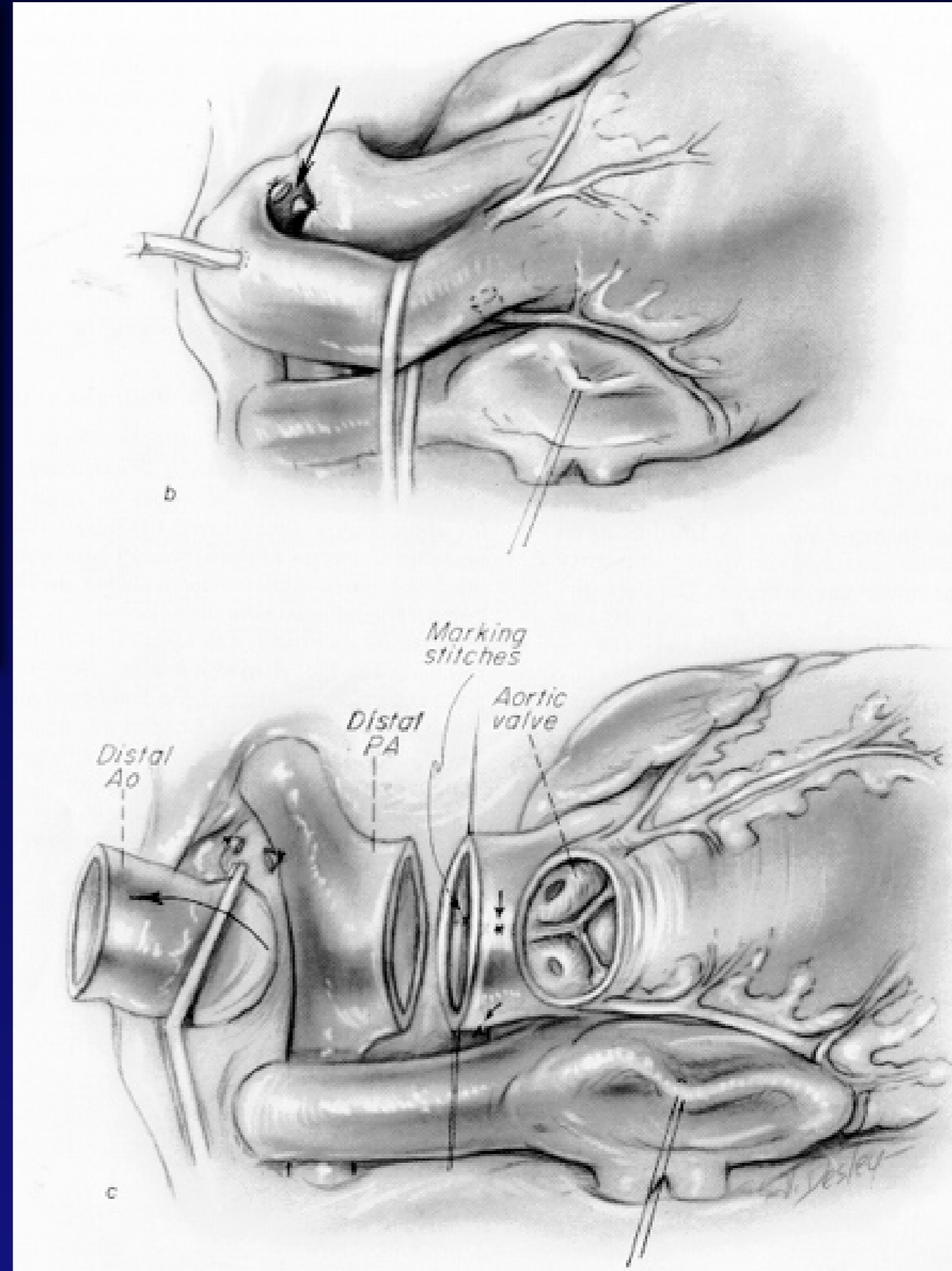
Pointers to an Intramural Coronary Artery

- Malalignment between the cusps of aorta & pulmonary artery
- High takeoff from the sinus of Valsalva or sinotubular ridge
- Crossing of the commissure of the aortic root
- Side by side great vessels (Double outlet)
- Coronary running between aorta & pulmonary arteries

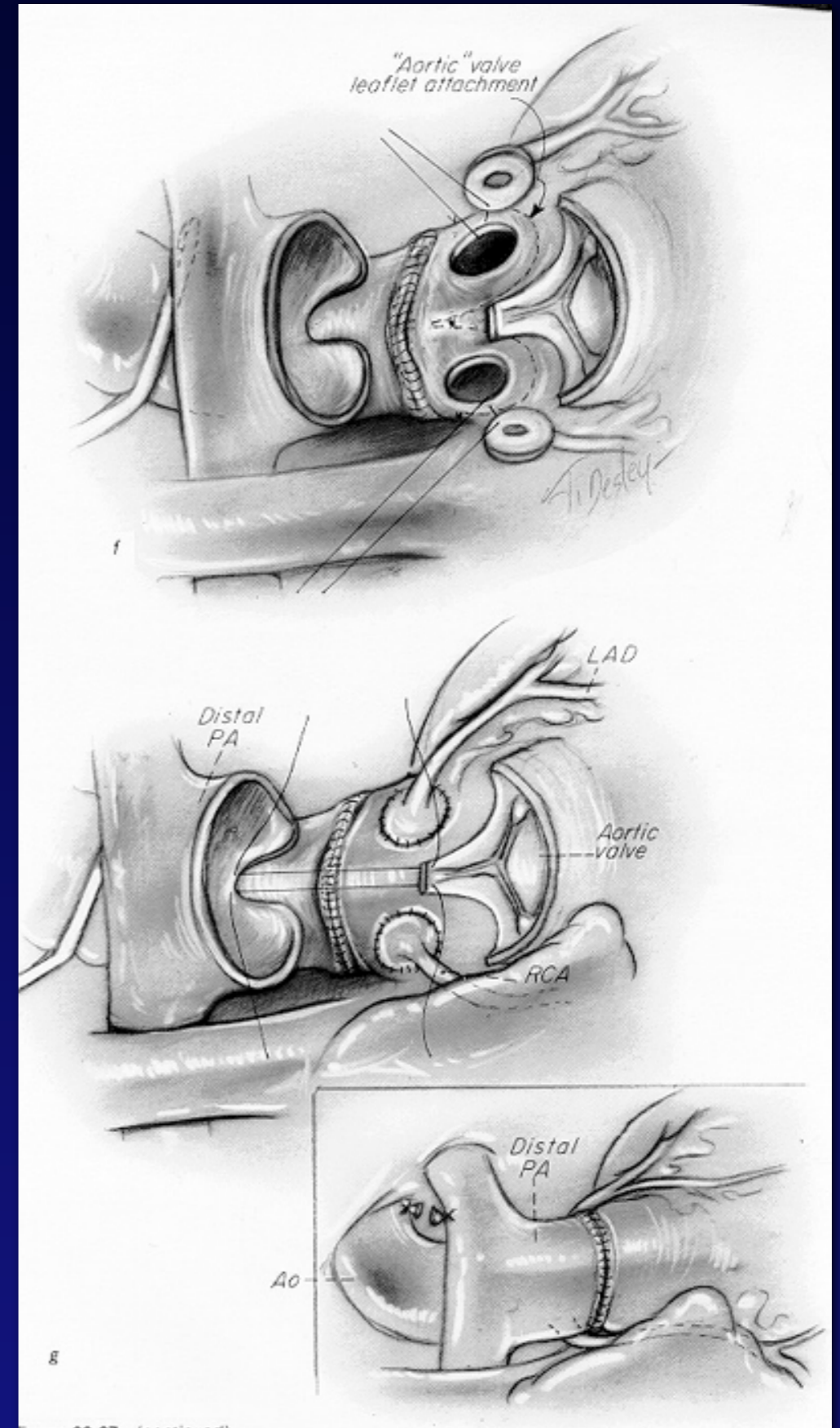
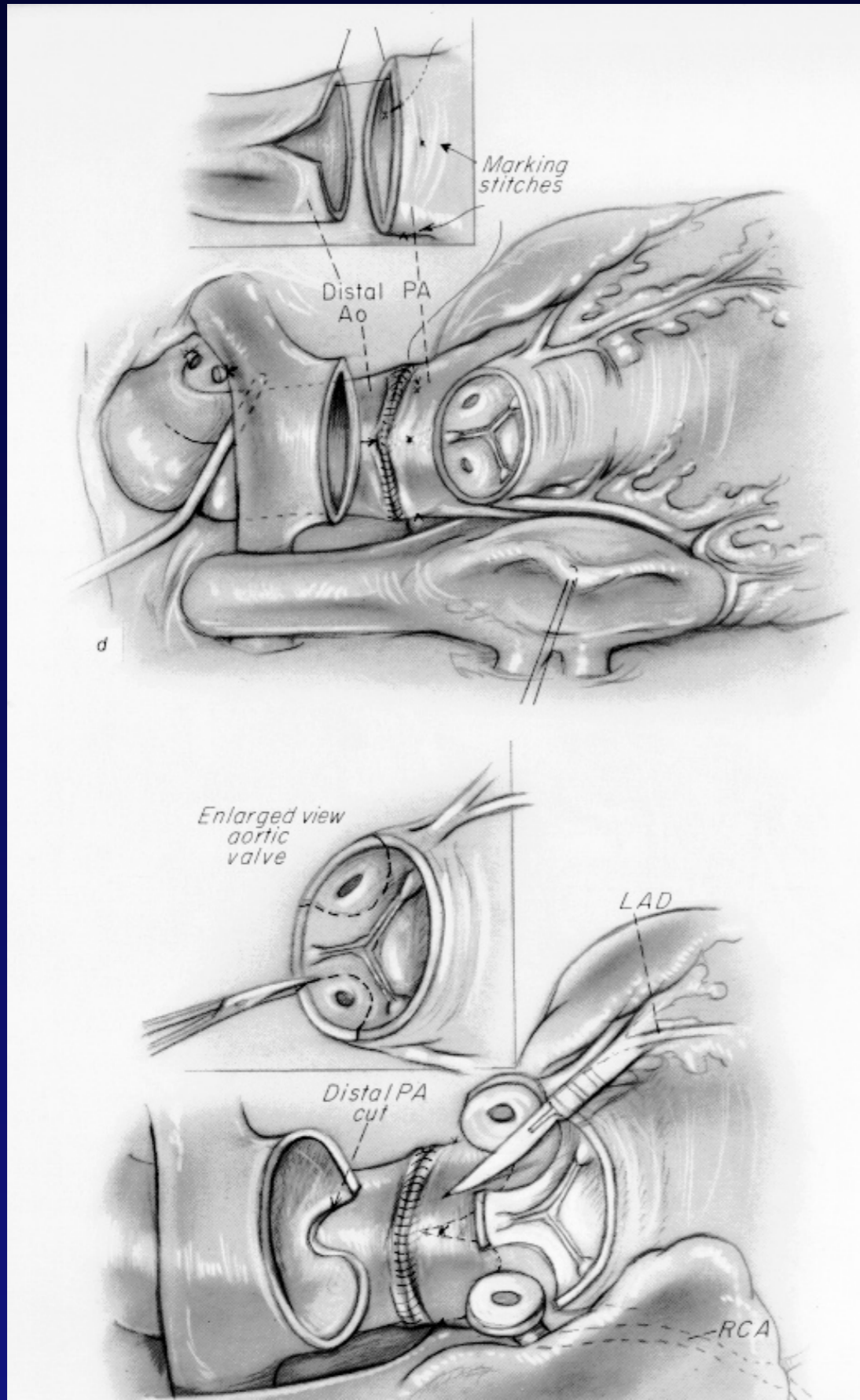
Current Operations For Transposition of the Great Arteries



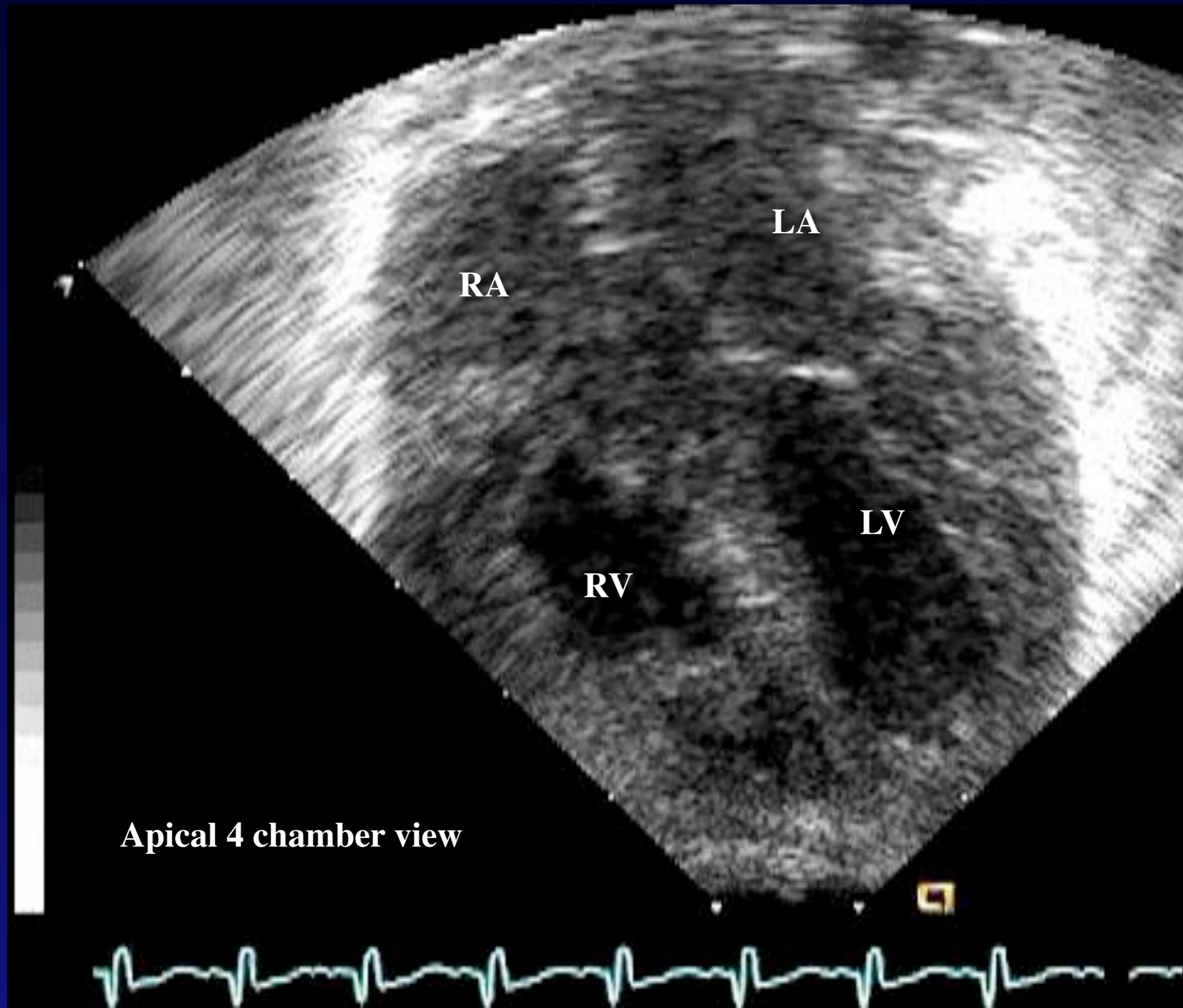
Arterial Switch Operation



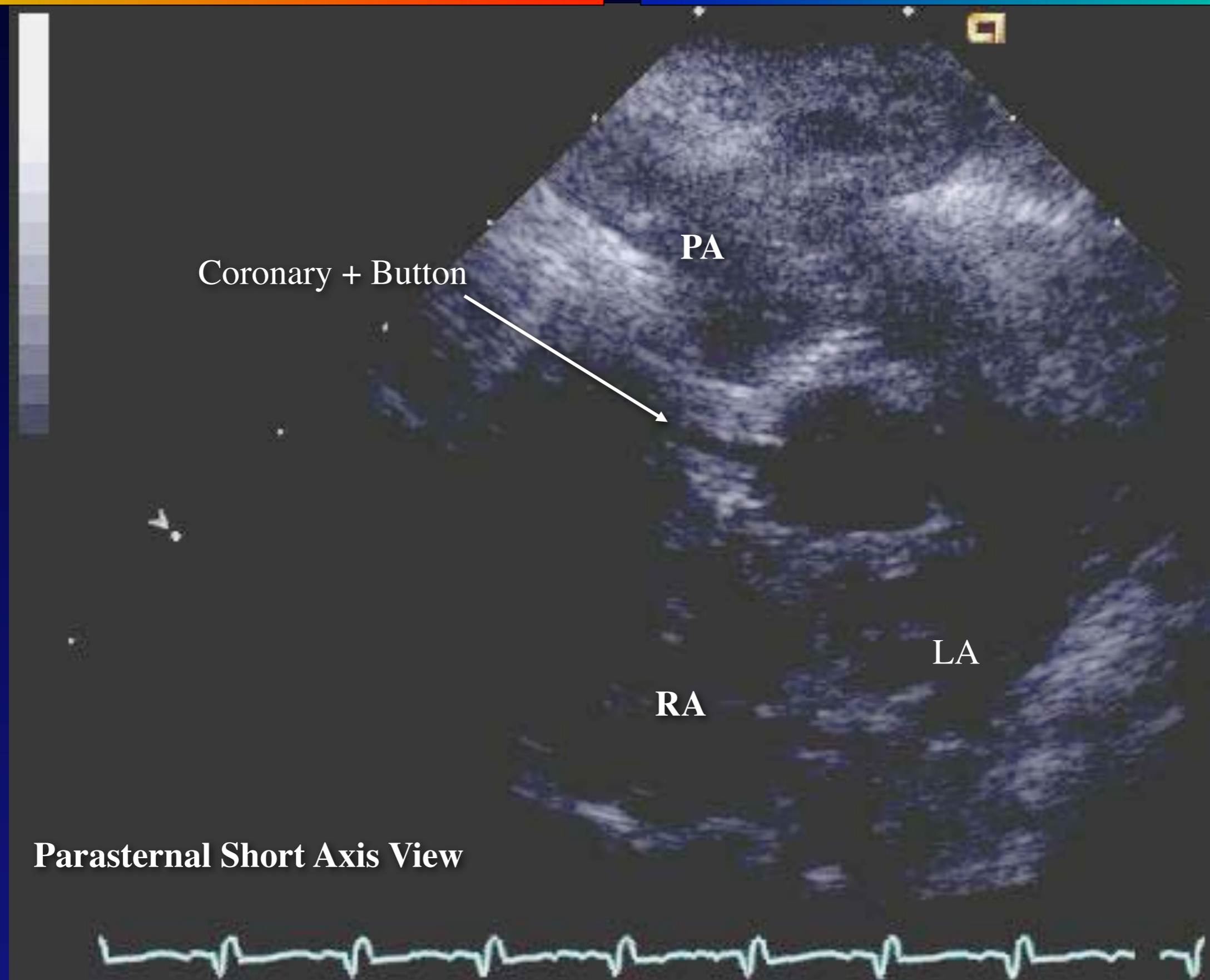
Current Operations For Transposition of the Great Arteries



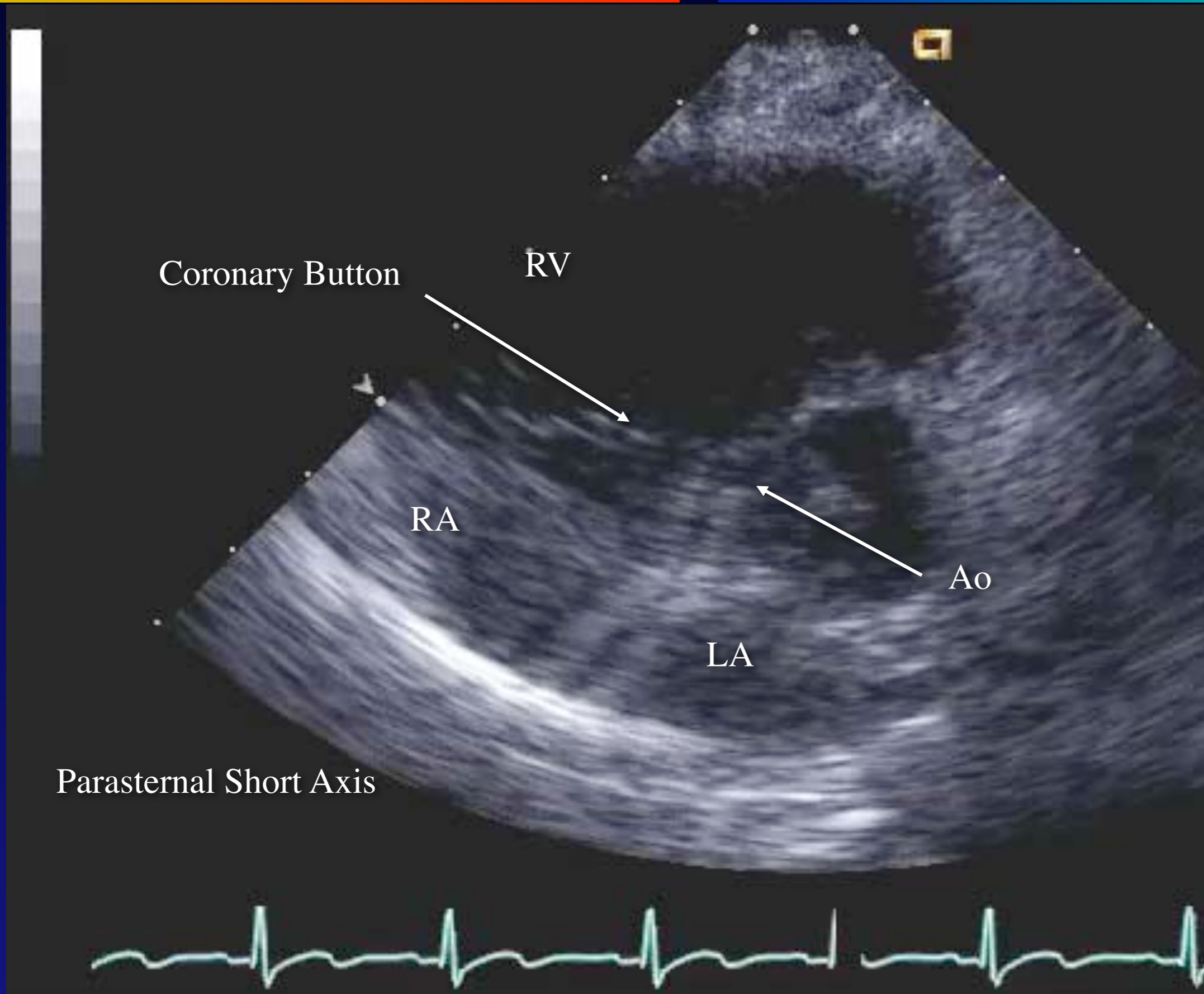
Arterial Switch Function & Residual Defects



Arterial Switch: The Coronary Arterial Anastomosis

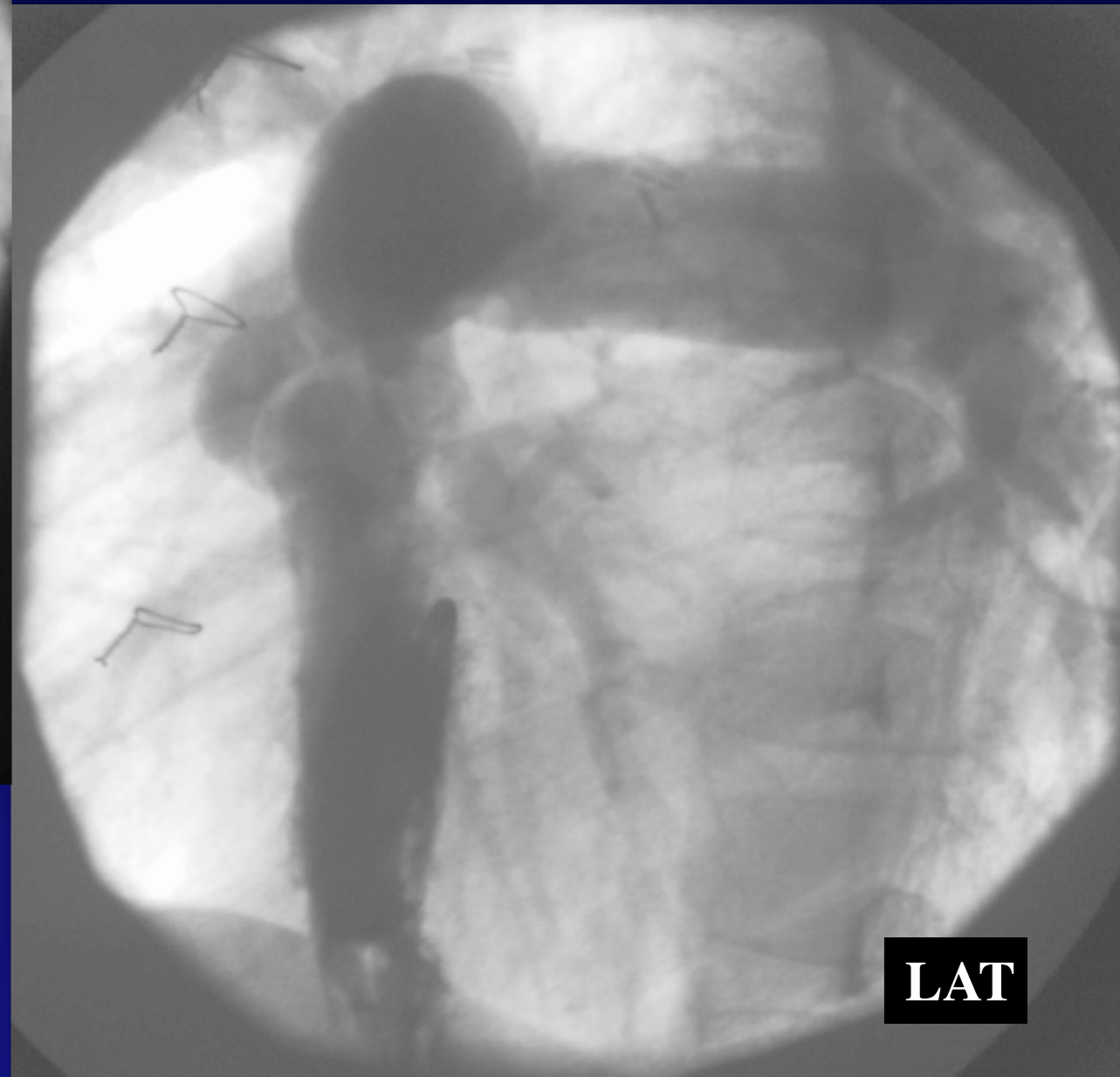
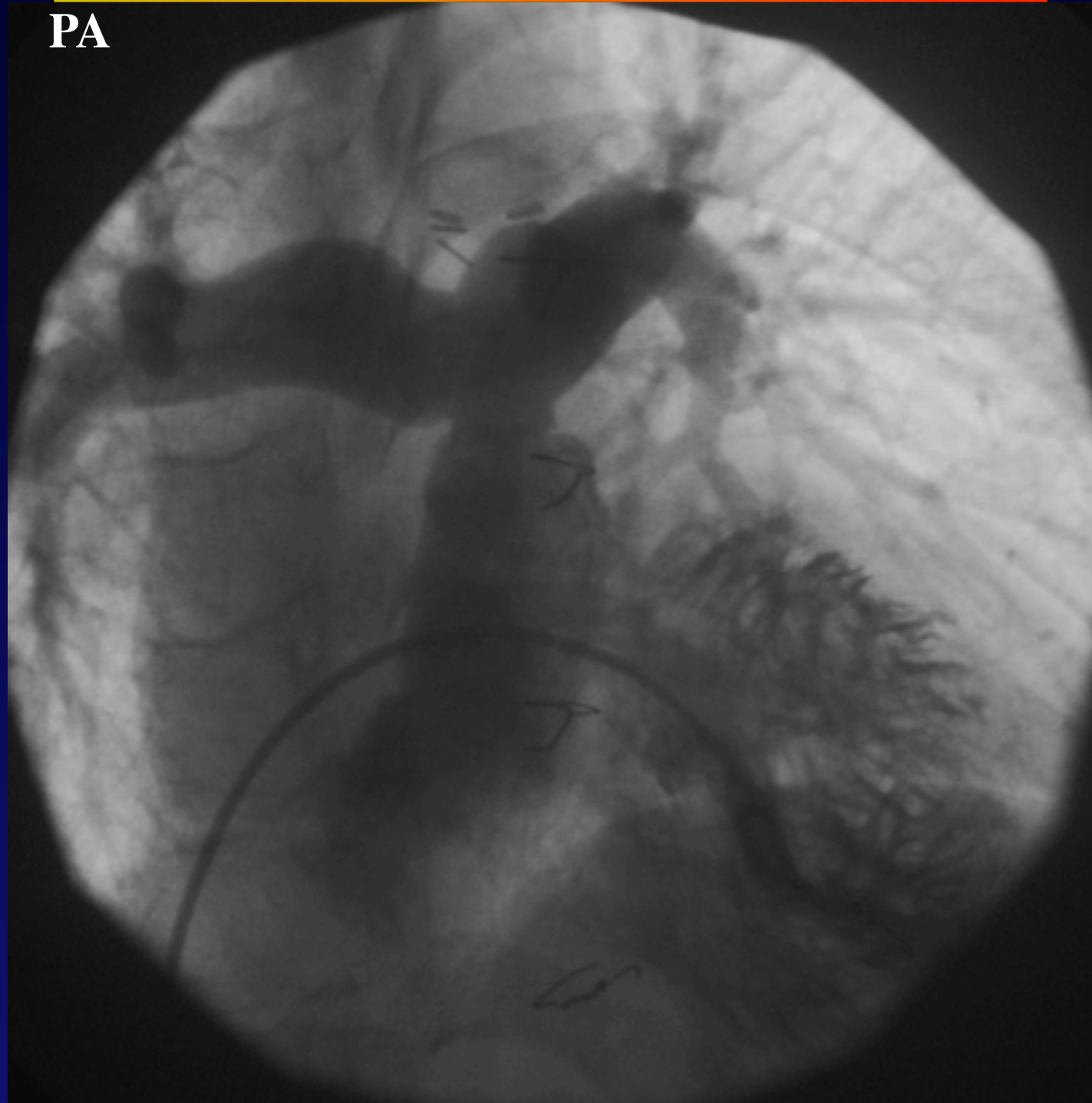


Arterial Switch: The Coronary Arterial Anastomosis



Arterial Switch Procedure: Angiography

PA



LAT


Arterial Switch Procedure: The Aortic Arch Evaluation

High Parasternal View

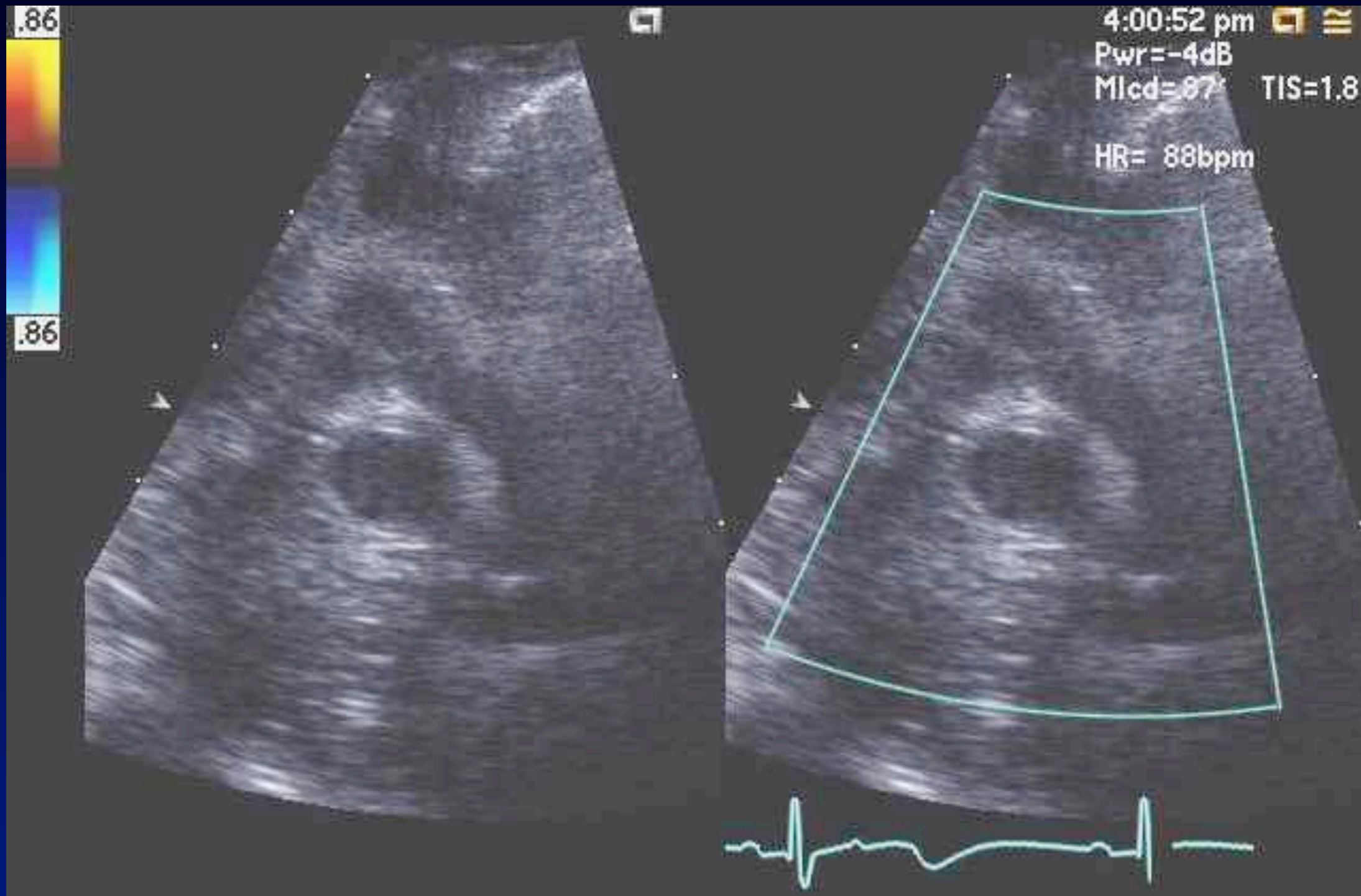
PA

AAo

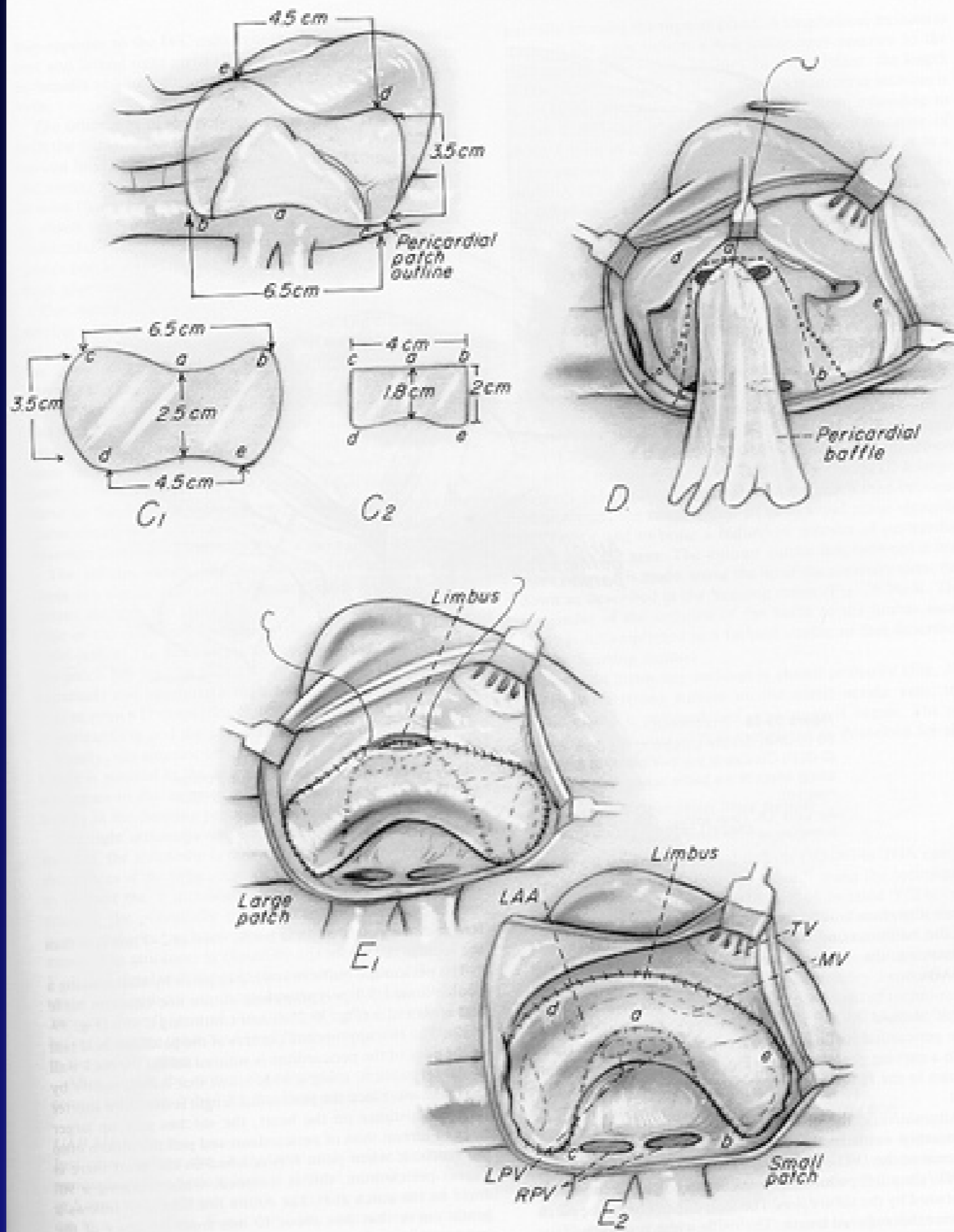
TAo



LeCompte arterioal Switch: SSN



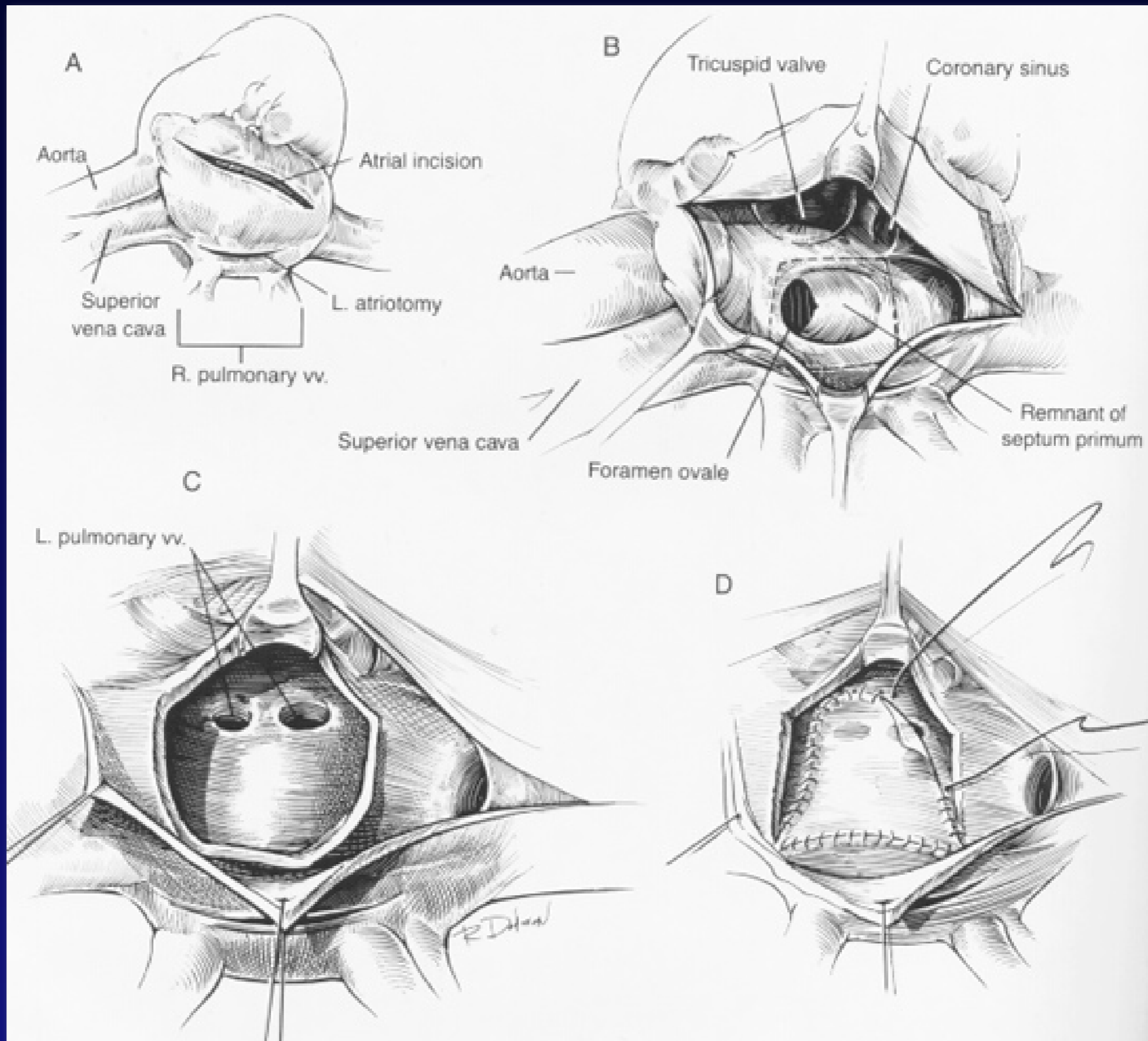
Atrial Switch Procedure



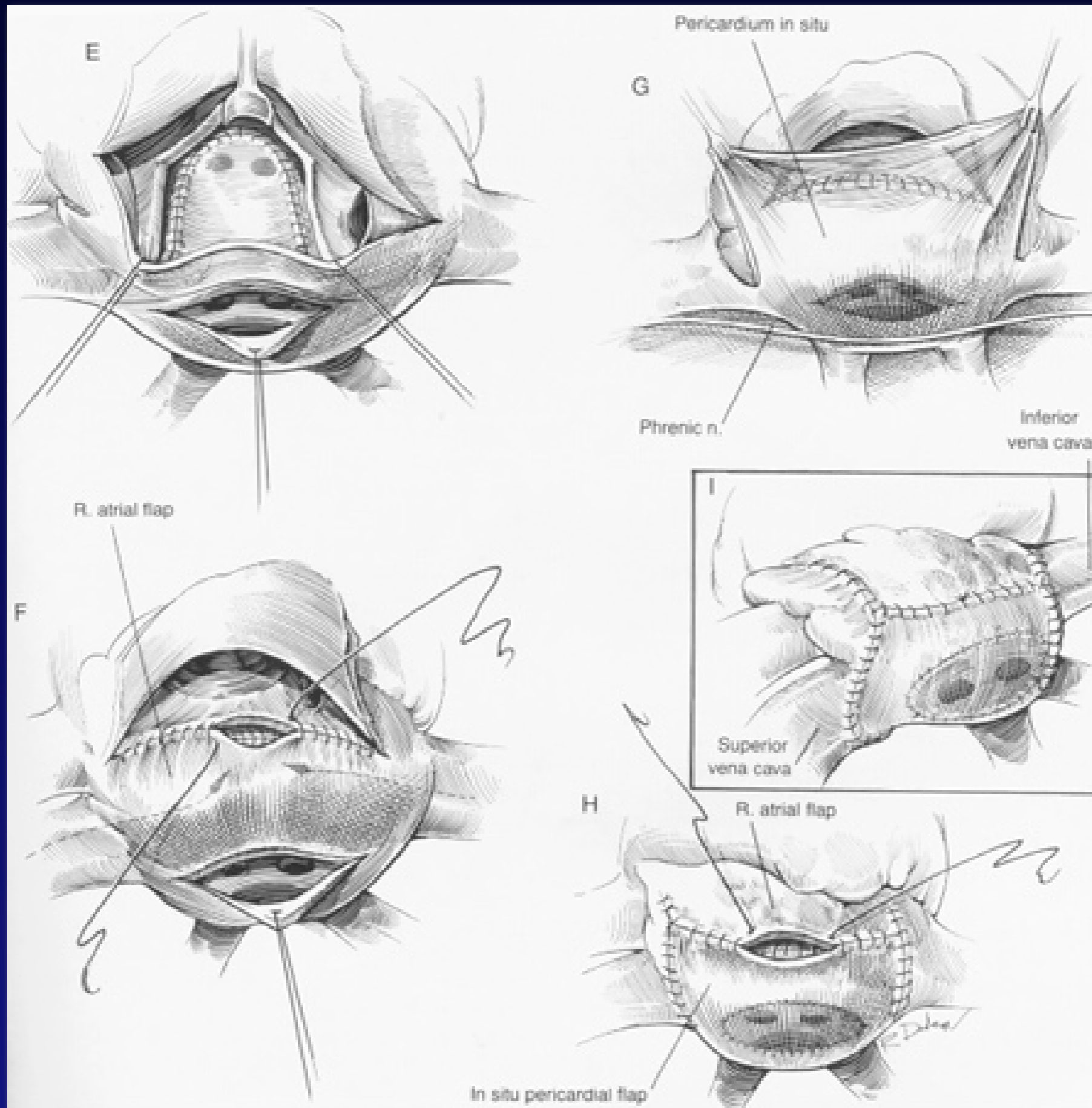
**Mustard's
Procedure**

Atrial Switch Procedure

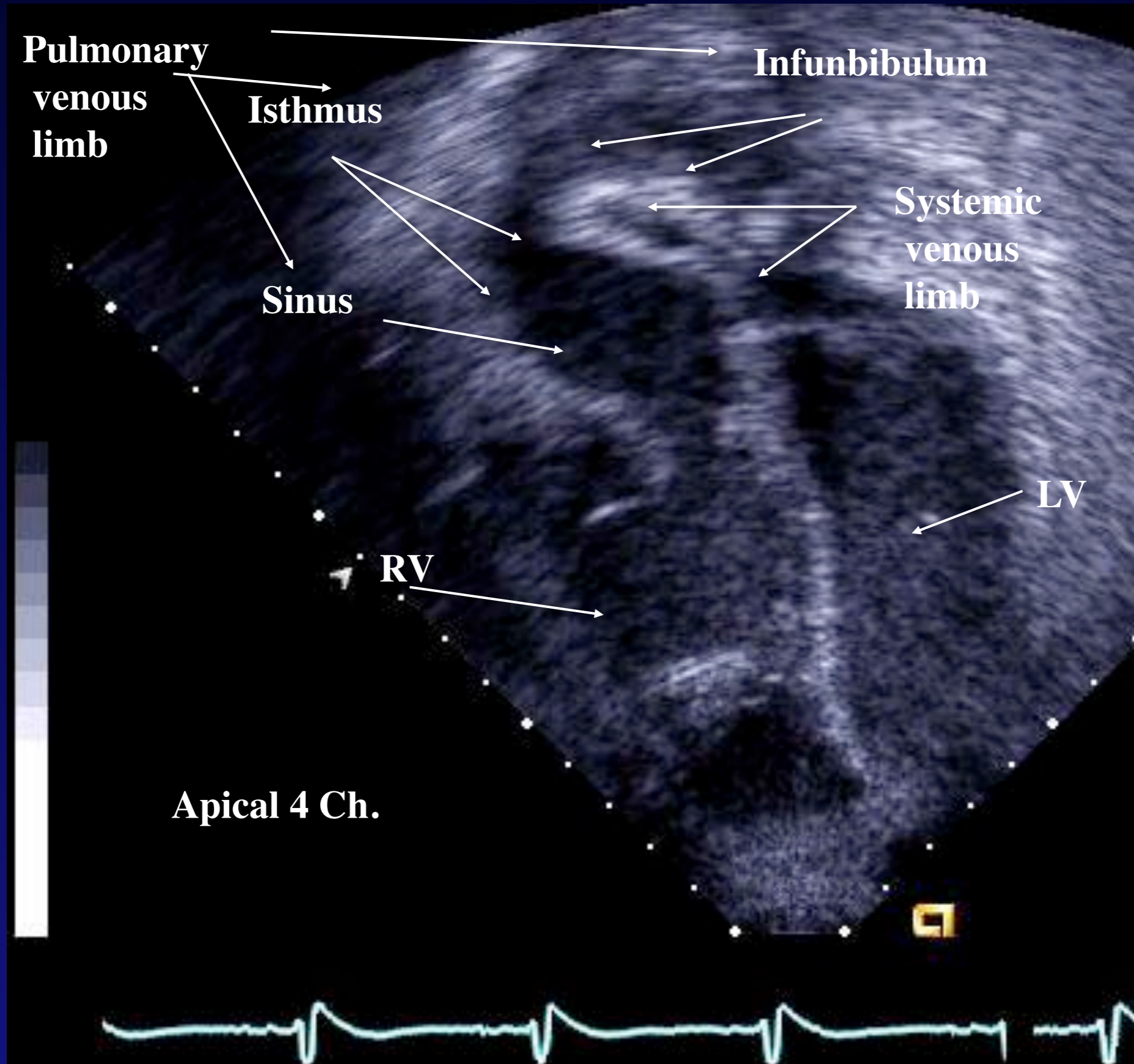
Senning's Operation



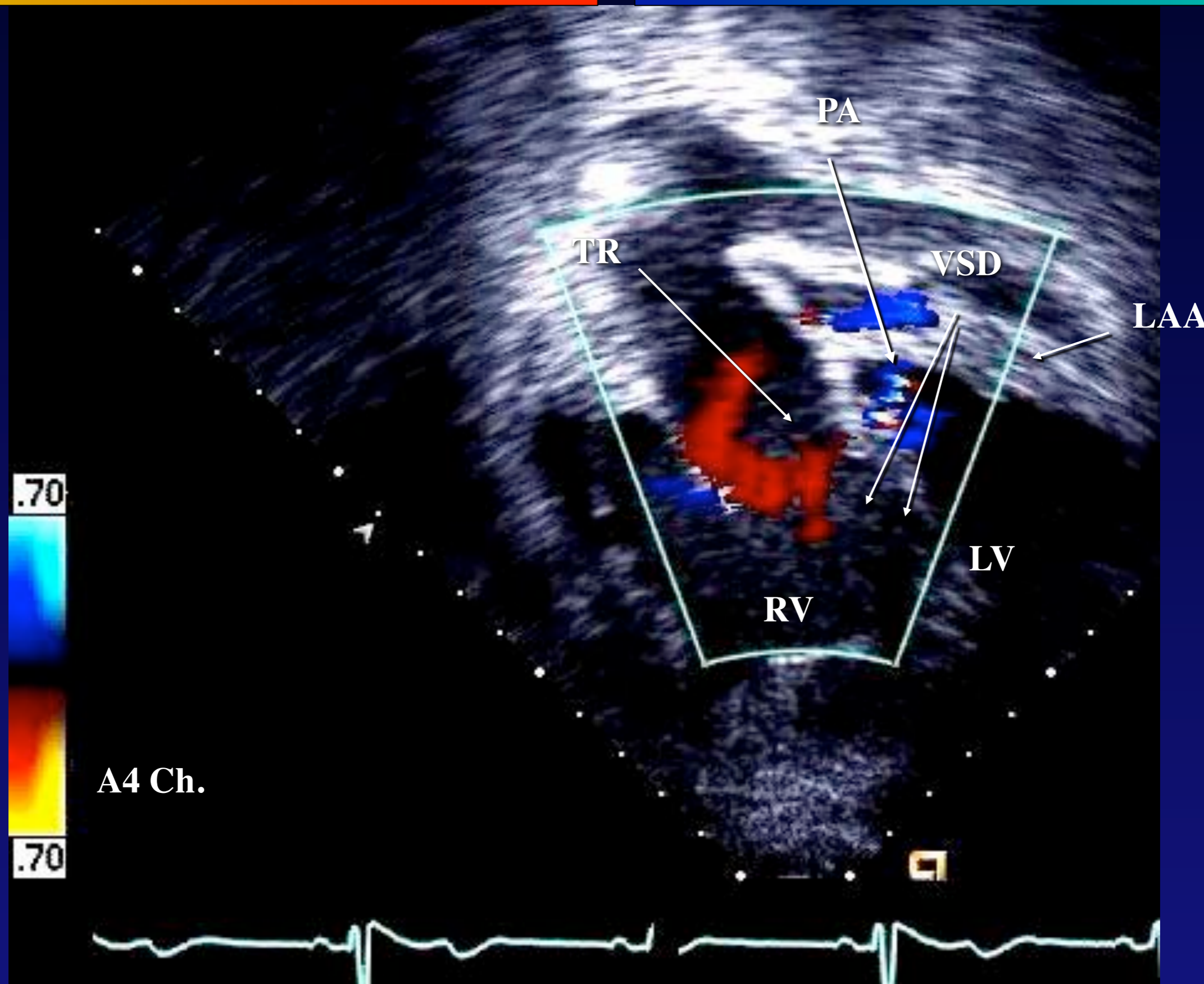
Atrial Switch Procedure



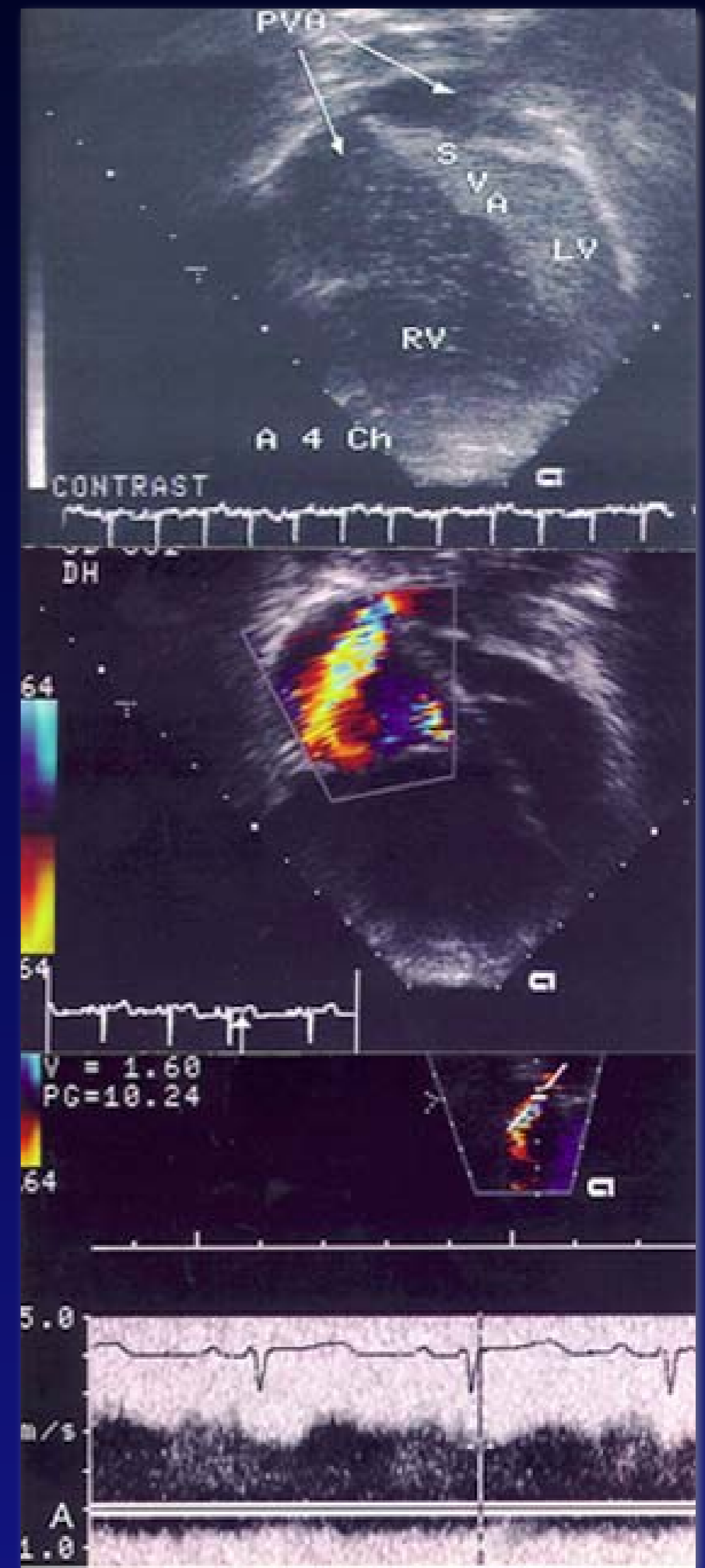
TGA, Postoperative Assessment: Venous Pathways (Mustard/Senning Operations)



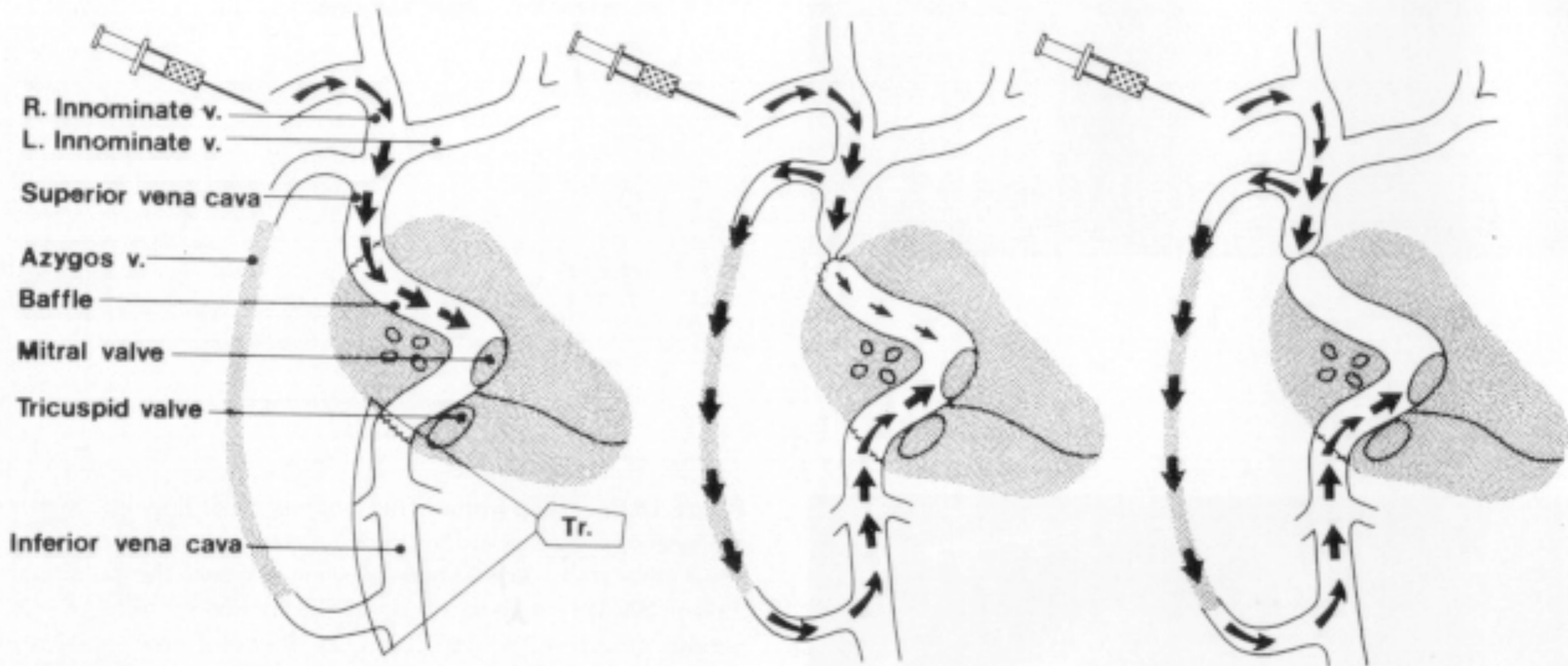
Atrial Switch Procedure: AV Valve Regurgitation & VSD



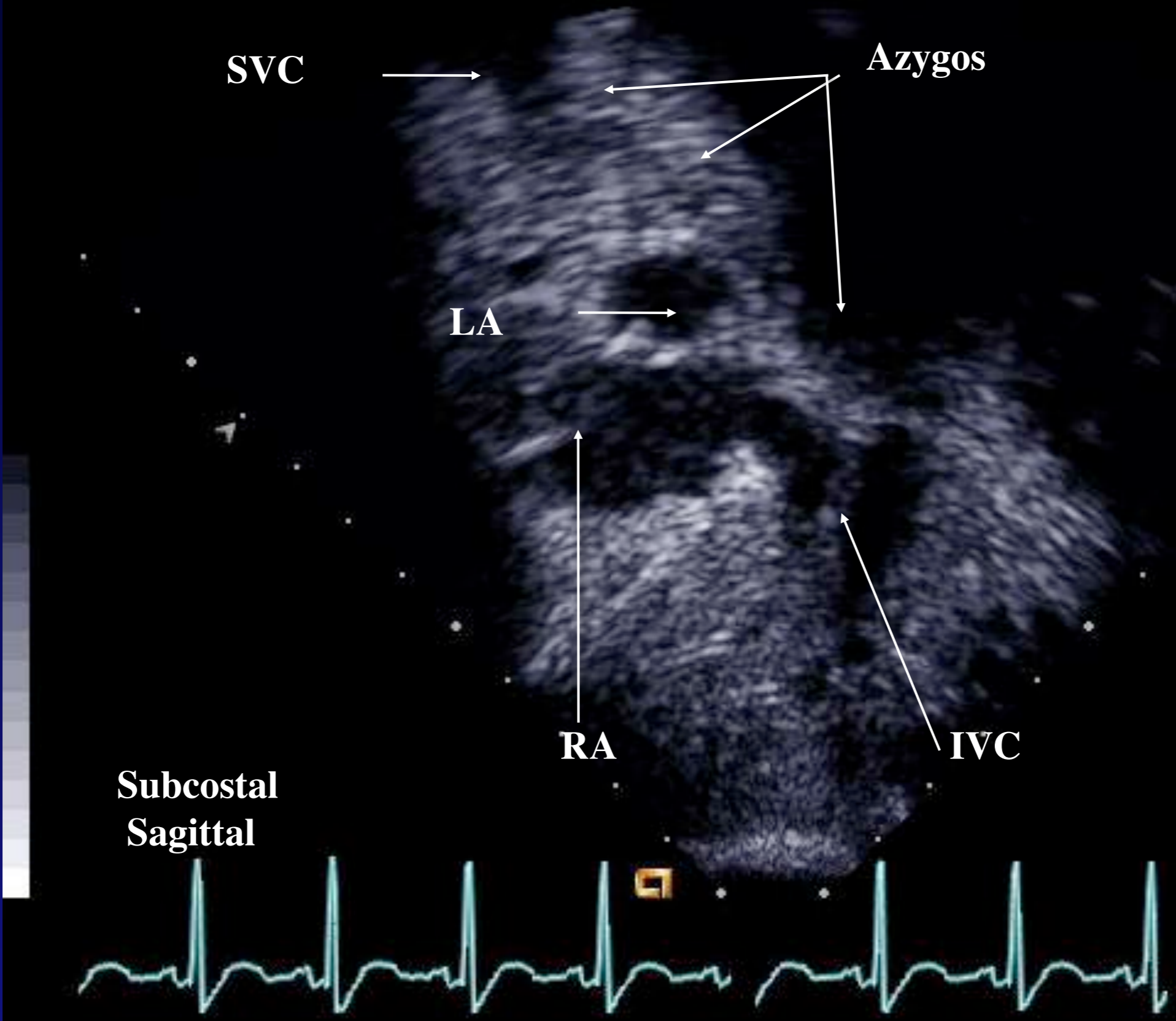
Atrial Switch Procedure: Obstructed Mid- Pulmonary Venous Pathway



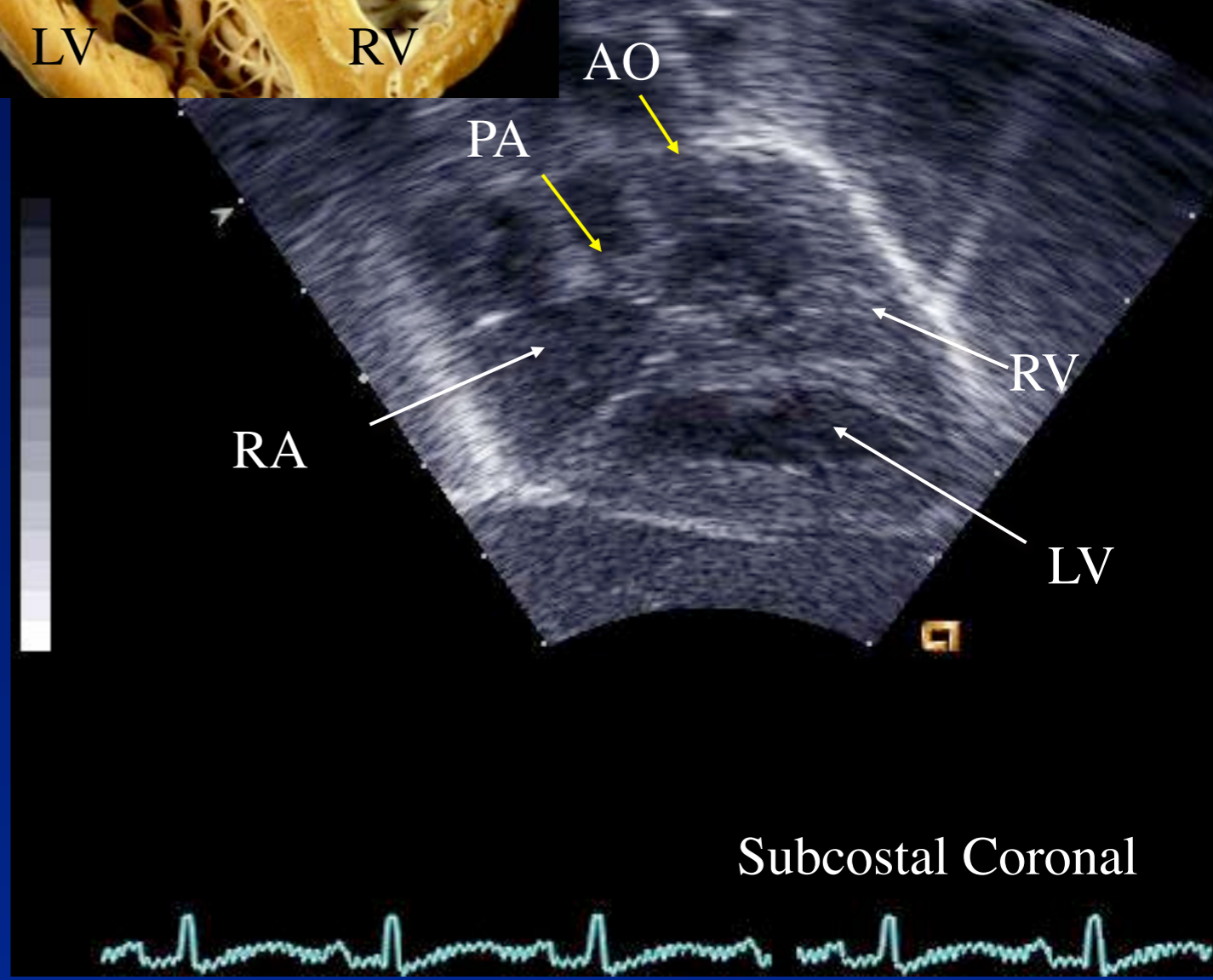
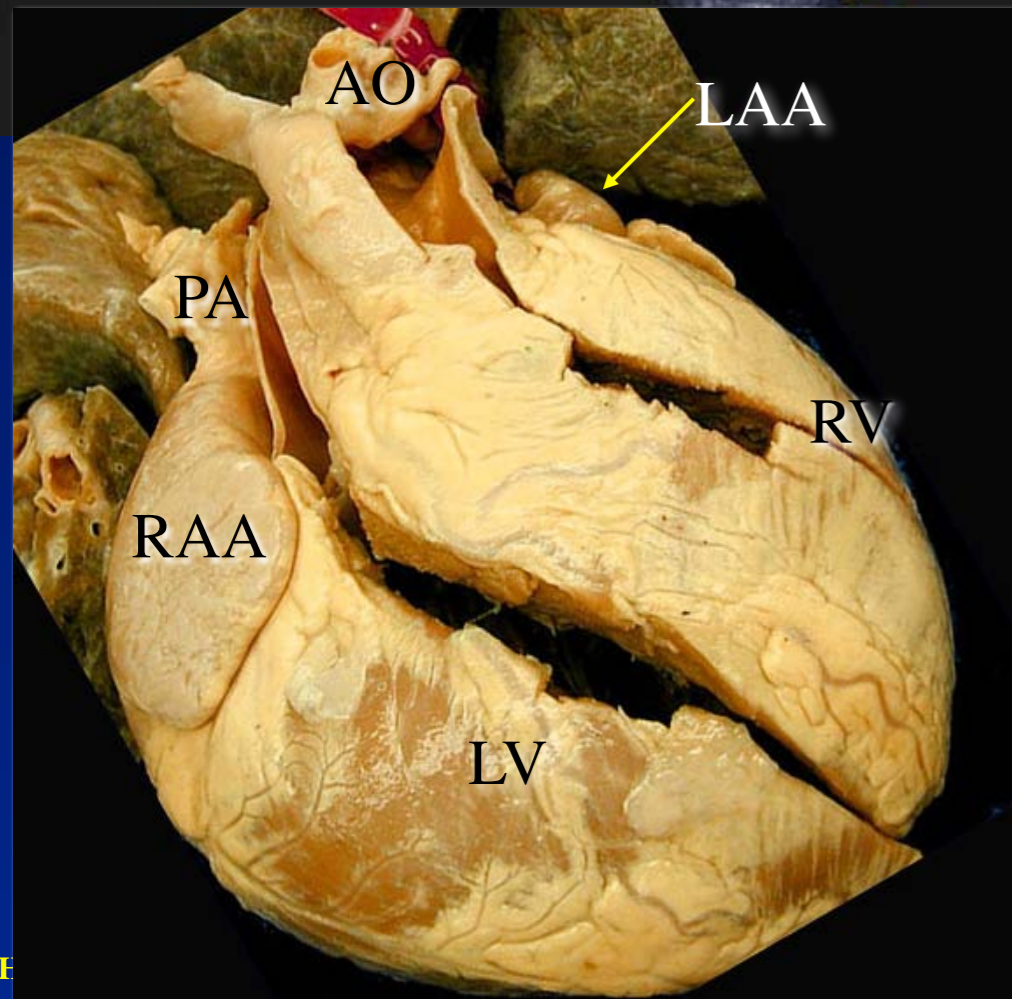
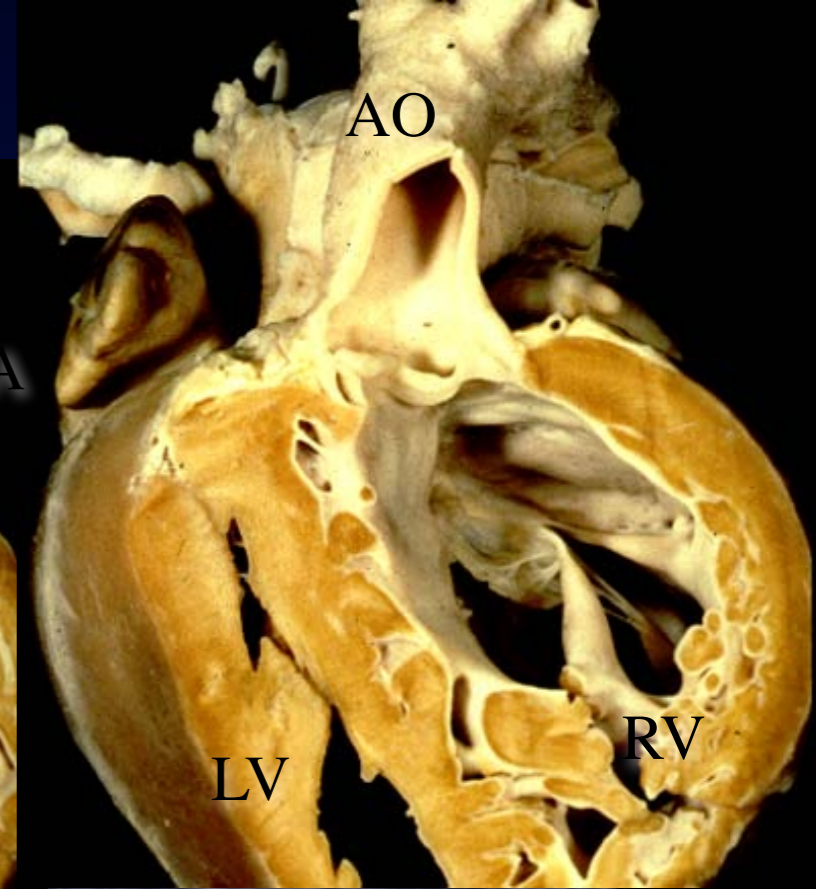
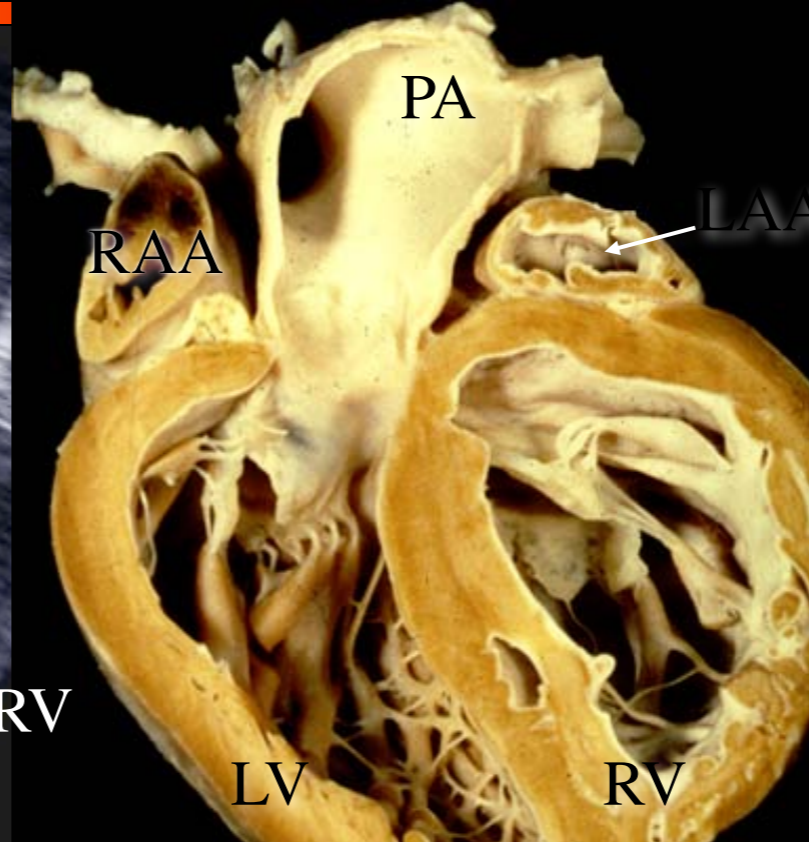
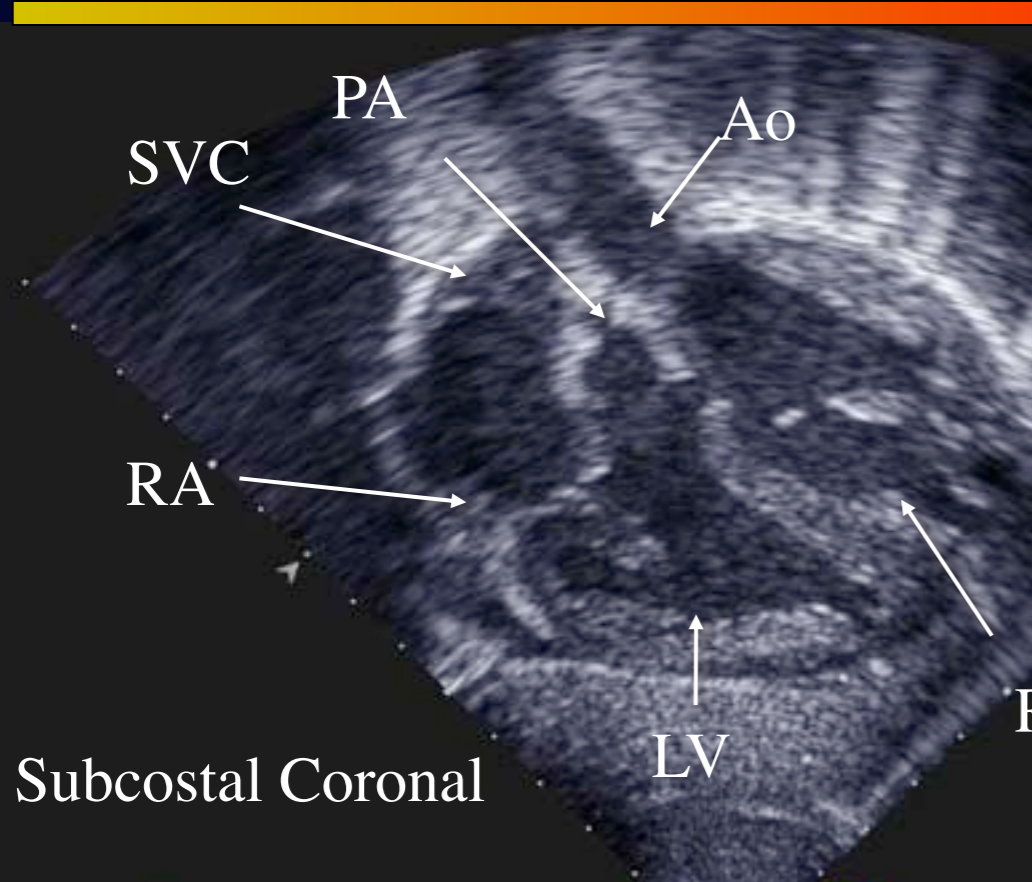
SCV Baffle obstruction with Conarast Echo



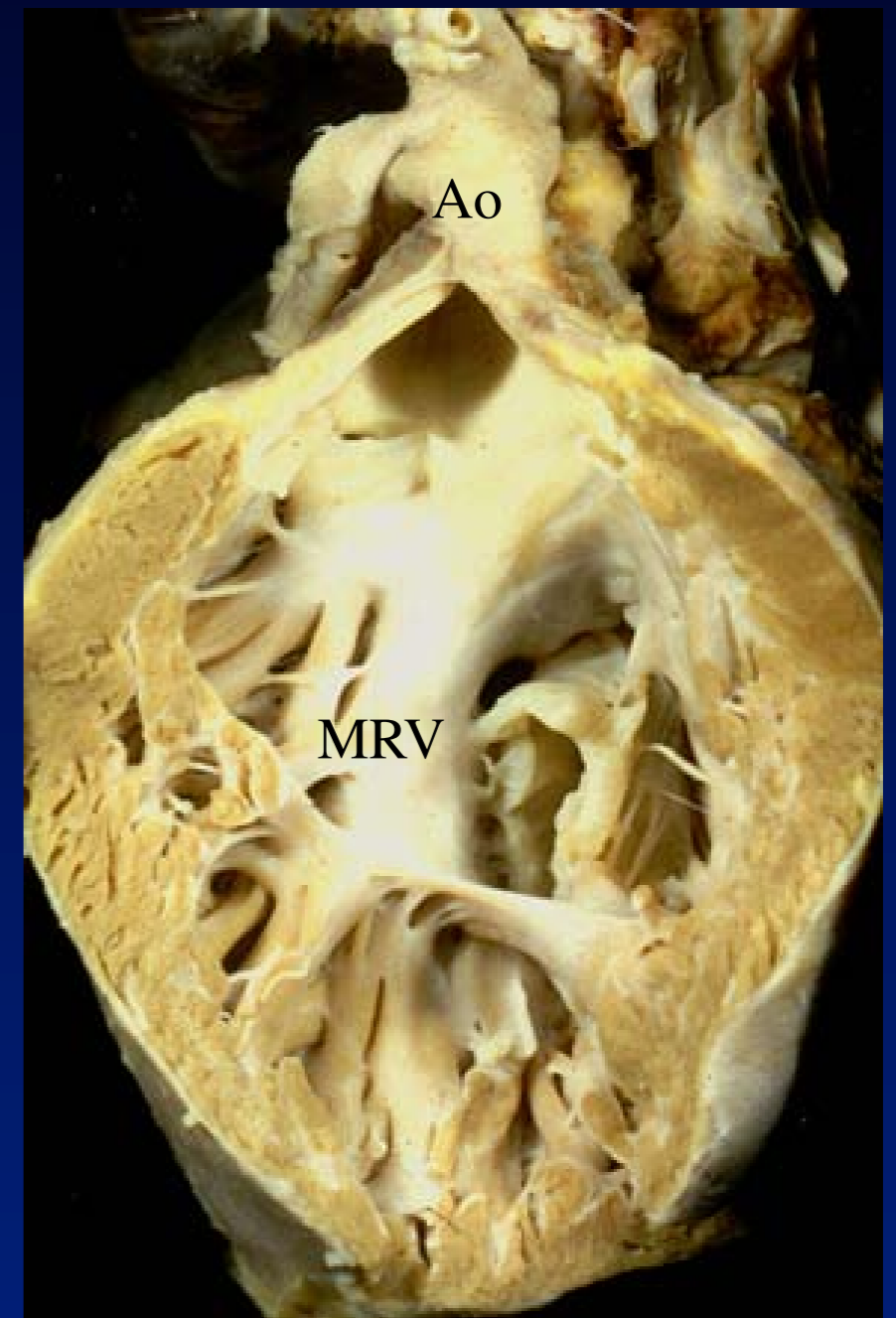
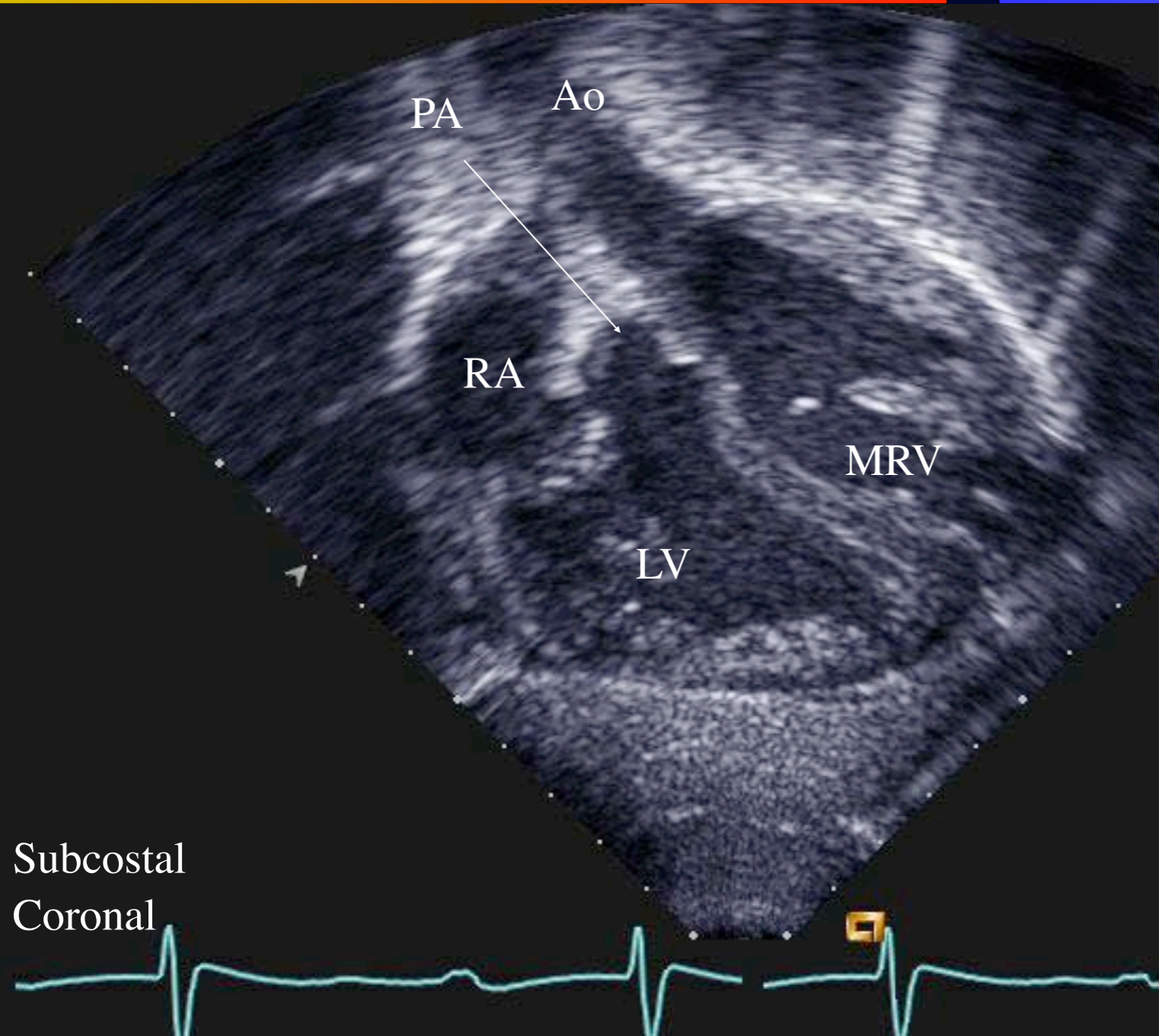
Atrial Switch Procedure: SVC Obstruction, color Mapping



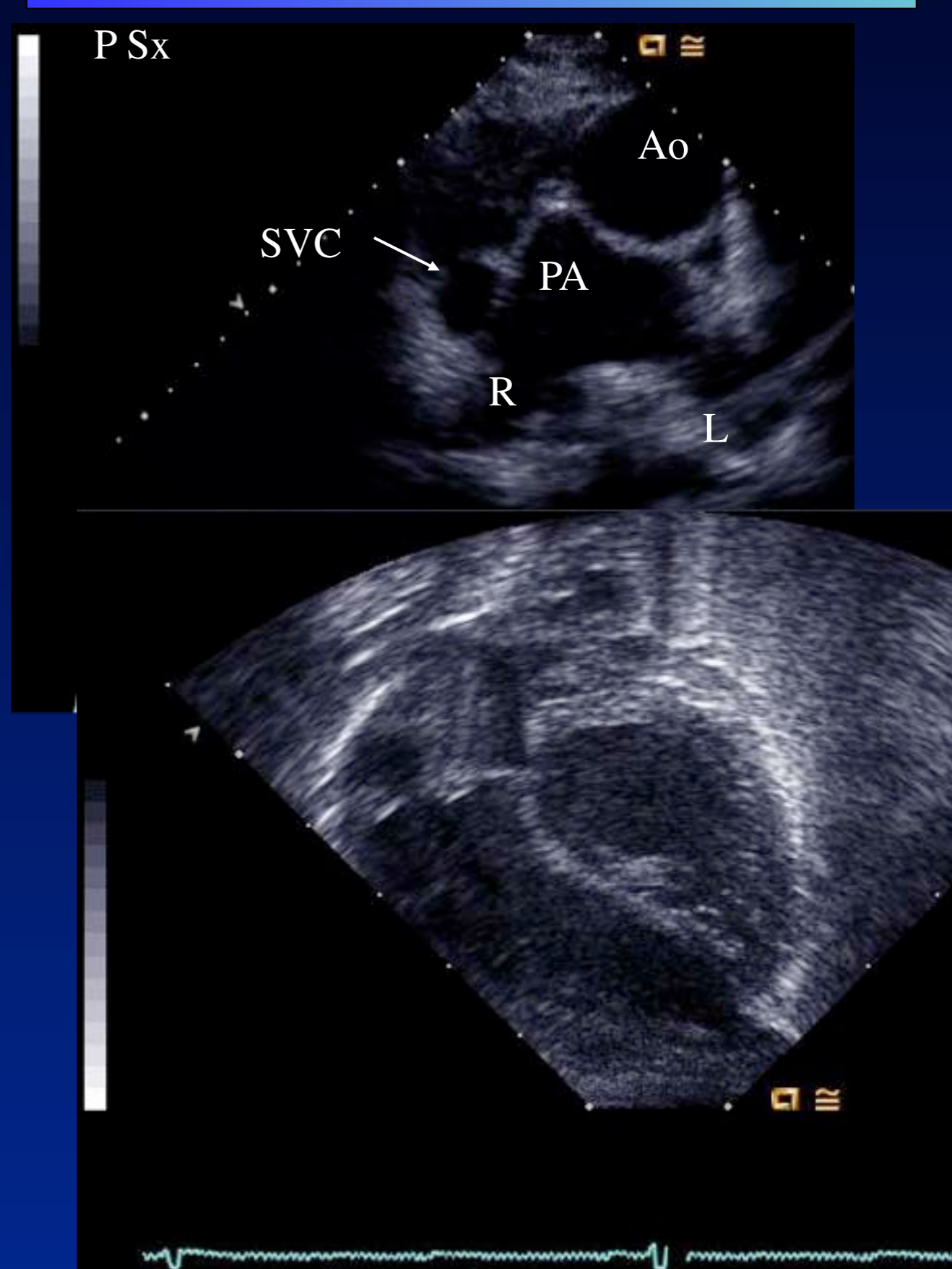
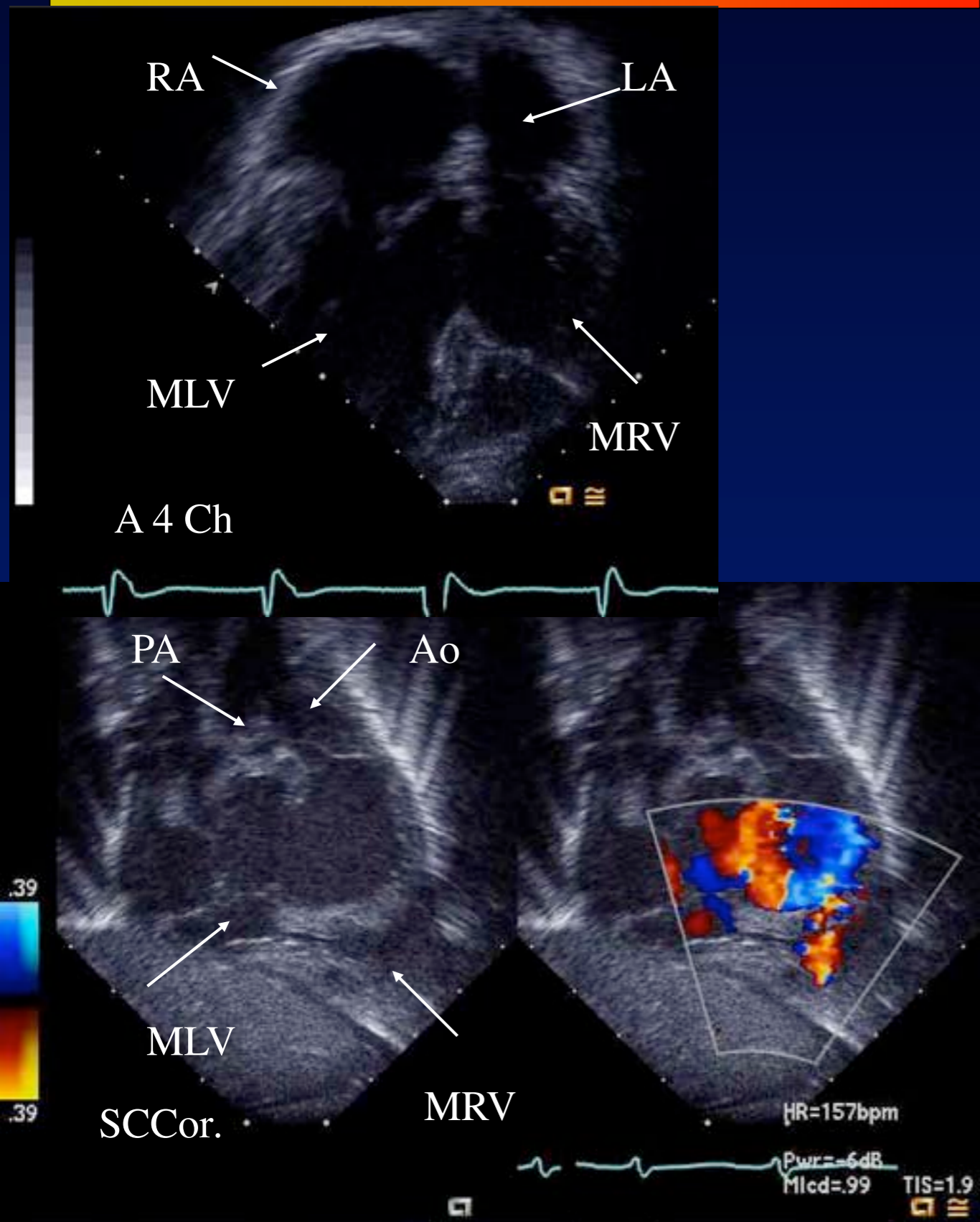
L Transposition



Corrected Transposition & Ebstein's Malformation



Corrected Transposition with Large inlet VSD





Thank You

Next Patient

